



Very Simple and Reliable Procedure, ‘Vertical Gastric Positioning’, To Prevent Delayed Gastric Emptying after Pancreatoduodenectomy

Takashi Orii*, Masaki Yoshimura, Hiroe Kitahara and Yukihiko Karasawa

Department of Gastrointestinal Surgery, Showa Inan General Hospital, Japan

Abstract

Purpose: Delayed gastric emptying is a major complication after pancreatoduodenectomy, and causes malnutrition owing to delayed oral feeding, leading to long hospital stays and increased hospitalization costs. It occurs at an incidence of 9%~30%. We have used vertical gastric positioning for several years for the treatment of delayed gastric emptying; therefore, we recommended its implementation. Herein we describe the procedure and report its efficacy.

Methods: Thirty-nine of 70 patients who underwent pancreatoduodenectomy in our hospital underwent pylorus-preserving pancreatoduodenectomy. A duodenojejunostomy was set at 40 cm distal from the hepaticojejunostomy, and the long axis of the stomach was placed vertical to the ground along the left abdominal wall without fixation to the surrounding tissue.

Results: Delayed gastric emptying of grade B occurred in only one (2.6%) of 39 cases. Eight patients discontinued oral food intake, but the causes were not related to delay gastric emptying. One patient did not begin oral feeding until 27 days after pancreatoduodenectomy owing to a grade B pancreatic fistula.

Conclusion: The incidence of delayed gastric emptying associated with vertical gastric positioning was as low as 2.6%. If the efficacy of this procedure can be established, it should easily become prevalent in view of its technical simplicity.

Keywords: Vertical gastric positioning; Delayed gastric emptying; Pylorus preserving pancreatoduodenectomy

Introduction

Pancreatoduodenectomy is one of the most invasive and complicated abdominal surgeries, and various complications may occur after the operation. Because Pancreatic Fistula (PF) occurs most frequently among those complications and may lead to a serious condition, much effort should be spent to prevent or manage PF. Delayed Gastric Emptying (DGE), though less serious, is another postoperative complication that can cause considerable stress for both patients and surgeons. DGE sometimes forces a long-term fasting, which causes a nutritional deterioration of the patient. The incidence of DGE is reported to be high, from 9% to 30% [1-5], and the International Study Group of Pancreatic Surgery (ISGPS) defined a grading scale of DGE [6], considering it to be an important complication in addition to PF.

In order to prevent the occurrence of DGE, operative procedures have been attempted and published in the medical literature, but a generally accepted procedure has not yet been established.

‘Vertical gastric positioning’ was devised as a means to prevent DGE. It is an easily-performed technique without complicated procedures, and it can be done during reconstruction after pancreatoduodenectomy. Here, we report the efficacy of ‘vertical gastric positioning’ as a procedure for preventing DGE in duodenojejunostomy after Pylorus-Preserving Pancreatoduodenectomy (PPPD).

Materials and Methods

Among the seventy patients who underwent pancreatoduodenectomy from 2012 to 2016, PPPD was performed in thirty-nine patients.

OPEN ACCESS

*Correspondence:

Takashi Orii, Department of Gastrointestinal Surgery, Showa Inan General Hospital, Akaho 3230, Komagane, Nagano 399-4117, Japan, Tel: +81-265822121; Fax: +81-

265822317;

E-mail: t.orii@sihp.jp

Received Date: 18 Feb 2020

Accepted Date: 10 Mar 2020

Published Date: 16 Mar 2020

Citation:

Orii T, Yoshimura M, Kitahara H, Karasawa Y. Very Simple and Reliable Procedure, ‘Vertical Gastric Positioning’, To Prevent Delayed Gastric Emptying after Pancreatoduodenectomy. *Clin Surg*. 2020; 5: 2768.

Copyright © 2020 Takashi Orii. This is an open access article distributed under the Creative Commons Attribution License, which permits unrestricted use, distribution, and reproduction in any medium, provided the original work is properly cited.

Procedure

The reconstruction after PPPD is performed according to Child's procedure. First, a duct-to-mucosa pancreaticojejunostomy is completed with interrupted suture, followed by Kakita's or Blumgart's pancreaticojejunostomy. Hepaticojejunostomy is the next procedure, consisting of a single-layer, interrupted suture. No stent is, in principle, placed in either of the anastomoses. A duodenojejunosomy located on the jejunum 40 cm distal to the hepaticojejunostomy is performed with end-to-side and layer-to-layer anastomoses, which consist of the interrupted seromuscular suture of the posterior row, the mucosal running suture of the round row, and finally the interrupted seromuscular suture of the anterior row. The suturing is done through the antecolic route using 4-0 absorbable polyglycolic acid strands. Two stitches between the jejunal wall of the afferent side and anterior wall of the lesser curvature are placed in order to prevent jejunal contents from being brought up to the proximal side of the jejunal loop. The Braun anastomosis is added at the preference of the surgeon. After the stomach is freed at the lesser curvature side by resecting the lesser omentum sufficiently until the abdominal esophagus, the stomach is positioned vertical to the ground in standing position, along the left abdominal wall without fixation to the surrounding organs or tissues (Figure 1).

Postoperative management and DGE definition

The Nasogastric Tube (NGT) is routinely removed on the first Postoperative Day (1POD), and intake of water is started on 3 to 5POD. After confirming negative findings of anastomotic leakage or gastric distention with passage disturbance by an Upper Gastrointestinal (UGI) series on 4 to 6POD (Figure 2), the patient begins to take a liquid, then a solid meal. Patients with gastric distention and passage disturbance at the first GI series are diagnosed as DGE. DGE is also diagnosed at the time of confirmation of gastric distention and passage disturbance by the second and subsequent UGI series when nausea and vomiting occur after the beginning of oral intake.

We used the grade of DGE defined by the International Study Group of Pancreatic Surgery (ISGPS) to evaluate of the severity of DGE.

Results

Comparison with other resection procedures

The patients included in this study underwent conventional Pancreatoduodenectomy (PD) or Subtotal Stomach-Preserving Pancreatoduodenectomy (SSPPD) besides PPPD. The patients with the three types of surgery were compared according to their backgrounds and operation-related variables (Table 1). In the order of PD, PPPD and SSPPD, the numbers of cases were 19, 39 and 12; the mean ages were 73.7 ± 9.6 , 70.5 ± 10.6 and 69.8 ± 8.1 years; the male-female ratios were 14:5, 25:14 and 7:5; and the body mass indices were 20.8 ± 2.4 , 21.2 ± 4.9 and 21.9 ± 3.5 , respectively. The most frequent primary diseases were pancreas head tumors, followed by the diseases of bile duct, papilla vater and duodenum within each type of operation. The one case of 'other diseases' belonging to PD was a metachronous metastasis of lymph nodes from gastric cancer. Except for the two cases of PD, the jejunal loop in a gastrojejunostomy or duodenojejunosomy was placed on the antecolic position. The Braun anastomosis was added in 13 of 19 cases with PD, 14 of 39 cases with PPPD and 0 of 12 cases with SSPPD. The occurrence of postoperative PF of grade B (no grade B was experienced) was nearly equivalent in the three types of the surgery. DGE occurred in 15.8% of PD,

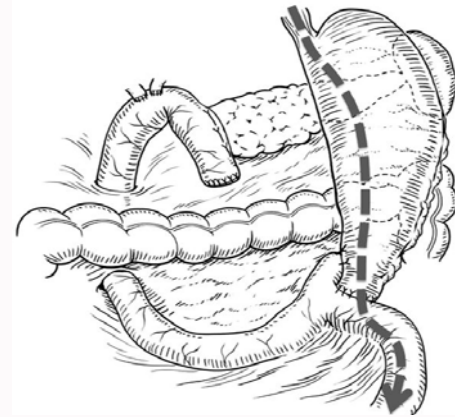


Figure 1: An illustration of 'Vertical gastric positioning', which the authors usually perform after pylorus-preserving pancreatoduodenectomy. The stomach, duodenum and jejunum are arranged along the left abdominal wall, vertical to the ground. The thick dotted arrow shows the pathway of meals due to gravity.

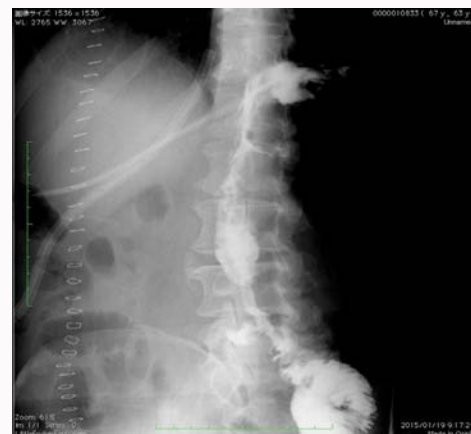


Figure 2: The upper gastrointestinal series on the fourth day after pylorus-preserving pancreatoduodenectomy. The contrast medium was passing straight down smoothly from the stomach to the efferent side of the jejunum.

2.6% of PPPD and 0% of SSPPD cases, and there were no significant differences among the three types of the surgery.

The cases of DGE after PPPD

As mentioned above, only one patient experienced DGE, the rate of occurrence of which was 2.6% (1 out of 39). The nasogastric tube was removed on 1POD because little fluid was drained through the tube the morning after the operation. Although the postoperative UGI series showed gastric distention and the massive retention of the contract medium in the stomach with a slight output, the patient was allowed to take a liquid meal on 5POD. On 7POD, two days after the beginning of oral intake, the patient vomited; X-rays showed the distention of the stomach. The patient was thus diagnosed as DGE. On 19POD, twelve days after the onset of DGE, the NGT was removed when the amount of drained fluid from NGT was less than 100 ml. This was followed by the intake of water on 20POD and solid oral diet on 21POD. After that, the symptoms of DGE did not recur. The severity of this case corresponded to grade B as defined by the ISGPS.

The cases with interruption of oral intake without DGE

In eight of the thirty-one cases, oral intake was interrupted, although the NGT was not reinserted, after confirming that the

Table 1: Characteristics by resection procedure of pancreatoduodenectomy.

Variables		PD	PPPD	SSPPD
No. of patients		19	39	12
Age [years]		73.7 ± 9.6	70.5 ± 10.6	69.8 ± 8.1
Gender	Male/Female	14/5	25/14	7/5
Body mass index [kg/m ²]		20.8 ± 2.4	21.2 ± 4.9	21.9 ± 3.5
Primary disease	Pancreas	9	19	7
	Bile duct	6	11	2
	Papilla Vater	2	6	2
	Duodenum	1	3	1
	others	1	0	0
Braun's anastomosis	Yes/No	13/6	14/25	0/12
Operation time [minutes]		572 ± 112	459 ± 111	481 ± 121
Hemorrhage [g]		1207 ± 620	878 ± 464	599 ± 333
Pancreatic fistula	No/Yes	10/9	18/21	06/6
	No & G-A/G-B	16/3	31/8	11/1
	%	15.8	20.5	8.3
DGE		3	1	0
	%	15.8	2.6	0

PD: Pancreatoduodenectomy; PPPD: Pylorus-Preserving Pancreatoduodenectomy; SSPPD: Subtotal Stomach-Preserving Pancreatoduodenectomy; G-A: Grade A; G-B: Grade B; DGE: Delayed Gastric Emptying

Table 2: Cases that experienced abnormal courses of oral feeding in DGE and other causes after PPPD.

Abnormality of OFD	Causes	No. of patient	POD, start of OFD	OFD interrupt period [days]	POD, restart of OFD
DGE		1	20		
Interruption	Peritoneal bleeding	1	4	3	
	Appetite loss	2	4	1	6
			6	2	12
	PF grade B	1	4	13	30
	Cholangitis	1	7	5	14
	Abdominal pain	2	4	1	7
			6	2	12
CD enteritis	1	5	5	14	
Start delay	PF grade B	1	27		

DGE: Delayed Gastric Emptying; PPPD: Pylorus-Preserving Pancreatoduodenectomy; OFD: Oral Feeding; POD: Postoperative Day; PF: Pancreatic Fistula; CD: Clostridium Difficile

patient did not have DGE at the first UGI series; in another case, the beginning of oral intake was delayed (Table 2).

The cause of the interruption was appetite loss in two cases, abdominal pain in two cases, the surgical treatment for peritoneal hemorrhage in one case, PF of grade B in one case, cholangitis in one case and enterocolitis due to *Clostridium difficile* in one case. The interruptions occurred within one week (the median period was 4 days), except for the case of PF (thirteen days). In the case with PF of grade B, the oral intake was delayed until the 27th day.

Discussion

DGE is one of the leading causes of morbidity as well as PF after pancreatoduodenectomy. DGE may affect not only the elongation of postoperative hospital stay and the increase of re-hospitalization [7], but also the reduction of postoperative survival [8]. The ISGPS proposed the definition of a grading scale for DGE [6], and this system is widely used in clinical settings. There are many published reports concerning DGE; the incidence rates reported in the literature published in 2017 range from 9% to 30% [1-5].

Regarding DGE, SSPPD would be superior to PPPD because the pylorus ring, which may not function sufficiently due to reduction of blood supply and denervation by surgical maneuver, could disturb the passage of meals from the stomach to the jejunum. In the published literature, some studies concluded that pylorus-resecting PD reduced the incidence of DGE compared with PPPD [9,10]; other studies report that pylorus preservation had no impact on DGE [4,11]. In our series, SSPPD had very little advantage compared to PPPD in DGE, so we concluded that there is no difference between PPPD and SSPPD regarding the incidence of DGE.

Many trial studies have been performed to date with the goal of suppressing DGE.

Tani et al. [12] concluded in their prospective randomized trial that antecolic duodenojejunostomy might improve the outcome of PPPD due to less DGE and a shorter hospital stay compared to retrocolic duodenojejunostomy. Hanna et al. [13] also suggested in their meta-analysis, which included 10 studies with a total of 1,067 patients, that the incidence of DGE was significantly lower with antecolic reconstruction than with retrocolic reconstruction. Ueno

et al. [14] speculated in their short series of twelve patients that Billroth-I type, end-to-side duodenojejunostomy with alignment of the stomach contour and fixation of the greater omentum to the abdominal wall resulted in the absence of DGE.

While a meta-analysis concluded that Braun anastomosis played an important role in reducing DGE after PD with traditional gastrojejunostomy [15], a prospective randomized controlled trial indicated that Braun anastomosis had an impact on reducing the clinical relevance of DGE (grade B and C in the definition of the ISGPS) after PPPD [16].

The devices used for the anastomosis, such as a circular stapler instead of hand-sewing [17] or flange gastroenterostomy (reported in cases after standard PD) [3,18], also resulted in reduction of DGE.

The major causes of DGE are assumed to be peristaltic dysfunction of the stomach due to the resection of the duodenal pacemaker and disruption of the gastroduodenal neural conditions [19] or ischemic injury to the antropyloric muscle mechanism [20]. If these are the causes, then the meal coming into the stomach would be better carried into the jejunum by gravity. 'Vertical gastric positioning' was born out of such a simple idea. By placing the long axis of the stomach along the left abdominal wall and directing the part of the duodenojejunostomy to the caudal side, the effect of gravity on the meal is increased.

Although several papers were retrieved by a key-words search for 'vertical stomach reconstruction', one described a case of retrocolic reconstruction [21], another described cases of pancreaticogastrostomy [22], and one was concerned with cases of pancreaticogastrostomy after SSPPD [23]. The incidence of DGE in those studies was 0% (0/12), 10% (3/10), and 0% (0/8), respectively (in the latter paper, some patients could have been considered as having DGE from the definition of the ISGPS).

Although some researchers have developed various methods and have obtained good results in preventing DGE after pancreatoduodenectomy, the overall incidence remains near 10%. Although more data are needed due to the shortage of reported cases (e.g., only 39 cases in our series), our result, that DGE occurred in only one out of 39 cases, should help improve the management after pancreatoduodenectomy.

Conclusion

Vertical gastric positioning is a simple and effective procedure to prevent the occurrence of DGE as a reconstruction after PPPD. Because this procedure does not require specialized skills or abilities, it should be suitable for examination in a high-volume center or multicenter collaboration. Vertical gastric positioning would be expected to become prevalent as a routine procedure to prevent DGE.

Acknowledgment

Approved Number: No. 2018-4 (Institutional ethics committee).

References

1. Tsutaho A, Nakamura T, Asano T, Okamura K, Tsuchikawa T, Noji T, et al. Delayed gastric emptying in side-to-side gastrojejunostomy in pancreatoduodenectomy: Result of a propensity score matching. *J Gastrointest Surg.* 2017;21(10):1635-42.
2. Murata Y, Tanemura A, Kato H, Kuriyama N, Azumi Y, Kishiwada M, et al. Superiority of stapled side-to-side gastrojejunostomy over conventional hand-sewn end-to-side gastrojejunostomy for reducing the

risk of primary delayed gastric emptying after subtotal stomach-preserving pancreaticoduodenectomy. *Surg Today.* 2017;47(8):1007-17.

3. Khan AS, Williams G, Woolsey C, Liu J, Fields RC, Doyle MMB, et al. Flange gastroenterostomy results in reduction in delayed gastric emptying after standard pancreaticoduodenectomy: A prospective cohort study. *J Am Coll Surg.* 2017;225(4):498-507.
4. Akizuki E, Kimura Y, Nobuoka T, Imamura M, Nishidate T, Mizuguchi T, et al. Prospective nonrandomized comparison between pylorus-preserving and subtotal stomach-preserving pancreaticoduodenectomy from the perspectives of DGE occurrence and postoperative digestive functions. *J Gastrointest Surg.* 2008;12(7):1185-92.
5. Glowka TR, Webler M, Matthaei H, Schäfer N, Schmitz V, Kalff JC, et al. Delayed gastric emptying following pancreatoduodenectomy with alimentary reconstruction according to Roux-en-Y or Billroth-II. *BMC Surg.* 2017;17(1):24.
6. Wente MN, Bassi C, Dervenis C, Fingerhut A, Gouma DJ, Izbicki JR, et al. Delayed gastric emptying (DGE) after pancreatic surgery: A suggested definition by the International Study Group of Pancreatic Surgery (ISGPS). *Surgery.* 2007;142(5):761-8.
7. Robinson JR, Marincola P, Shelton J, Merchant NB, Idrees K, Parikh AA. Peri-operative risk factors for delayed gastric emptying after a pancreaticoduodenectomy. *HPB (Oxford).* 2015;17(6):495-501.
8. Futagawa Y, Kanehira M, Furukawa K, Kitamura H, Yoshida S, Usuba T, et al. Impact of delayed gastric emptying after pancreaticoduodenectomy on survival. *J Hepatobiliary Pancreat Sci.* 2017;24(8):466-74.
9. Hanna MM, Gadde R, Tamariz L, Allen CJ, Meizoso JP, Sleeman D, et al. Delayed gastric emptying after pancreaticoduodenectomy: Is subtotal stomach preserving better or pylorus preserving? *J Gastrointest Surg.* 2015;19(8):1542-52.
10. Kawai M, Tani M, Hirono S, Miyazawa M, Shimizu A, Uchiyama K, et al. Pylorus ring resection reduces delayed gastric emptying in patients undergoing pancreatoduodenectomy: A prospective, randomized, controlled trial of pylorus-resecting versus pylorus-preserving pancreatoduodenectomy. *Ann Surg.* 2011;253(3):495-501.
11. Wu W, Hong X, Fu L, Liu S, You L, Zhou L, et al. The effect of pylorus removal on delayed gastric emptying after pancreaticoduodenectomy: A meta-analysis of 2,599 patients. *PLoS One.* 2014;9(10):e108380.
12. Tani M, Terasawa H, Kawai M, Ina S, Hirono S, Uchiyama K, et al. Improvement of delayed gastric emptying in pylorus-preserving pancreaticoduodenectomy: Results of a prospective, randomized, controlled trial. *Ann Surg.* 2006;243(3):316-20.
13. Hanna MM, Tamariz L, Gadde R, Allen C, Sleeman D, Livingstone A, et al. Delayed gastric emptying after pylorus preserving pancreaticoduodenectomy--does gastrointestinal reconstruction technique matter? *Am J Surg.* 2016;211(4):810-9.
14. Ueno T, Takashima M, Iida M, Yoshida S, Suzuki N, Oka M. Improvement of early delayed gastric emptying in patients with Billroth I type of reconstruction after pylorus preserving pancreatoduodenectomy. *J Hepatobiliary Pancreat Surg.* 2009;16(3):300-4.
15. Huang MQ, Li M, Mao JY, Tian BL. Braun enteroenterostomy reduces delayed gastric emptying: A systematic review and meta-analysis. *Int J Surg.* 2015;23(Pt A):75-81.
16. Hwang HK, Lee SH, Han DH, Choi SH, Kang CM, Lee WJ. Impact of Braun anastomosis on reducing delayed gastric emptying following pancreaticoduodenectomy: A prospective, randomized controlled trial. *J Hepatobiliary Pancreat Sci.* 2016;23(6):364-72.
17. Sakamoto Y, Hori S, Oguro S, Arita J, Kishi Y, Nara S, et al. Delayed gastric emptying after stapled versus hand-sewn anastomosis of duodenojejunostomy in pylorus-preserving pancreaticoduodenectomy: A randomized controlled trial. *J Gastrointest Surg.* 2016;20(3):595-603.

18. Khan AS, Hawkins WG, Linehan DC, Strasberg SM. A technique of gastrojejunostomy to reduce delayed gastric emptying after pancreatoduodenectomy. *J Gastrointest Surg.* 2011;15(8):1468-71.
19. Tanaka M, Sarr MG. Total duodenectomy: effect on canine gastrointestinal motility. *J Surg Res.* 1987;42(5):483-93.
20. Liberski SM, Koch KL, Atnip RG, Stern RM. Ischemic gastroparesis: Resolution after revascularization. *Gastroenterology.* 1990;99(1):252-7.
21. Chijiwa K, Ohuchida J, Hiyoshi M, Nagano M, Kai M, Kondo K. Vertical retrocolic duodenojejunostomy decreases delayed gastric emptying after pylorus-preserving pancreatoduodenectomy. *Hepatogastroenterology.* 2007;54(78):1874-7.
22. Murakami H, Yasue M. A vertical stomach reconstruction after pylorus-preserving pancreaticoduodenectomy. *Am J Surg.* 2001;181(2):149-52.
23. Oida T, Mimatsu K, Kawasaki A, Kano H, Kuboi Y, Aramaki O, et al. Vertical stomach reconstruction with pancreaticogastrostomy after modified subtotal-stomach-preserving pancreaticoduodenectomy for preventing delayed gastric emptying. *Hepatogastroenterology.* 2009;56(90):565-7.