



## Value of Vessel Sealing System in Skin-Sparing Mastectomy in Patients with Early Breast Cancer

Jun Hirano, Satoki Kinoshita\*, Takashi Kazama, Naoko Shimada, Ryo Miyake, Ken Uchida and Hiroshi Takeyama

Department of Surgery, Jikei University School of Medicine, Japan

### Abstract

**Purpose:** Skin-Sparing Mastectomy (SSM) with immediate breast reconstruction is generally chosen to achieve radical cure with favorable cosmetic outcome in patients with breast cancer, but some skin approaches limit exposure of the surgical field. We evaluated our results using a Vessel Sealing System (VSS) to determine if its use counterbalanced limitations associated with these approaches.

**Methods:** We retrospectively reviewed records of 365 consecutive patients with breast cancer who underwent mastectomy between February 2007 and August 2017 to identify 148 cases that employed either of 2 skin approaches—a periareolar incision with midaxillary line incision or areola-sparing incision with midaxillary line incision.

**Results:** We divided cases into 2 groups of 74 each that either did or did not employ the VSS system and observed significant differences between the groups in intraoperative hemorrhage (214 g vs. 106 g,  $p < 0.000$ ), length of midaxillary line incision scar (136 mm vs. 86 mm,  $p < 0.000$ ), and postoperative hospital stay (14.9 days vs. 10.9 days,  $p < 0.000$ ), findings that suggested the system's use improved outcomes.

**Conclusions:** Significant advantages using the vessel sealing system in skin-sparing mastectomy compensated for drawbacks associated with inadequate operative field exposure with some approaches.

### OPEN ACCESS

**Keywords:** Breast cancer; Skin-sparing mastectomy; Vessel sealing system

#### \*Correspondence:

Satoki Kinoshita, Department of Surgery, Jikei University School of Medicine, 3-25-8 Nishishimbashi, Minato-ku, Tokyo, 105-8461, Japan, Tel: 81-3-3433-1111; Fax: 81-3-5472-4140;

E-mail: satokino0918@nifty.com

**Received Date:** 02 Jul 2018

**Accepted Date:** 27 Jul 2018

**Published Date:** 31 Jul 2018

#### Citation:

Hirano J, Kinoshita S, Kazama T, Shimada N, Miyake R, Uchida K, et al. Value of Vessel Sealing System in Skin-Sparing Mastectomy in Patients with Early Breast Cancer. *Clin Surg*. 2018; 3: 2055

**Copyright** © 2018 Satoki Kinoshita.

This is an open access article distributed under the Creative Commons Attribution License, which permits unrestricted use, distribution, and reproduction in any medium, provided the original work is properly cited.

### Introduction

Since Halsted [1] first performed radical surgery for breast cancer in 1882, therapeutic strategies and surgical techniques have evolved [2]. Today, the major objective of surgical treatment is the local control of cancer as a part of systemic therapy [3], and breast-conserving surgery is the mainstream treatment.

The breast surgeon faces the ongoing challenge to cure the cancer and achieve a favorable cosmetic outcome in that process, and Skin-Sparing Mastectomy (SSM) with immediate breast reconstruction, reported by Toth and Lappert [4] in 1991, has become the generally acknowledged best method to accomplish those sometimes seemingly conflicting tasks.

At Jikei University hospitals, we have adopted this method in cooperation with plastic surgeons and achieved excellent results since 2003 [2], developing, after some trial and error, 4 types (5 approaches) of skin incision for SSM (Figure 1) [5-7].

These include a periareolar incision with lateral extension that is described as a “tennis racket” incision (Type A in Figure 1); a periareolar incision with a midaxillary line incision (Type B); an “areola-sparing” incision (Type C) that combines a straight incision in either a mediolateral (Type C1) or craniocaudal direction (Type C2) with a small elliptical incision at the base line of the nipple within the areola complex (Type C2 adds a caudal extension if needed) with a midaxillary line incision; and a small transverse elliptical incision that contains the entire nipple areolar complex combined with a transverse axillary incision (Type D).

We have achieved superior postoperative aesthetic results using 2 of the 4 approaches, the periareolar incision with midaxillary line incision (Type B in the Figure 1) and areola-sparing incision with midaxillary line incision (Type C), but optimal exposure of the operative field with either of these approaches is difficult and requires particular skill. To address this issue, we began

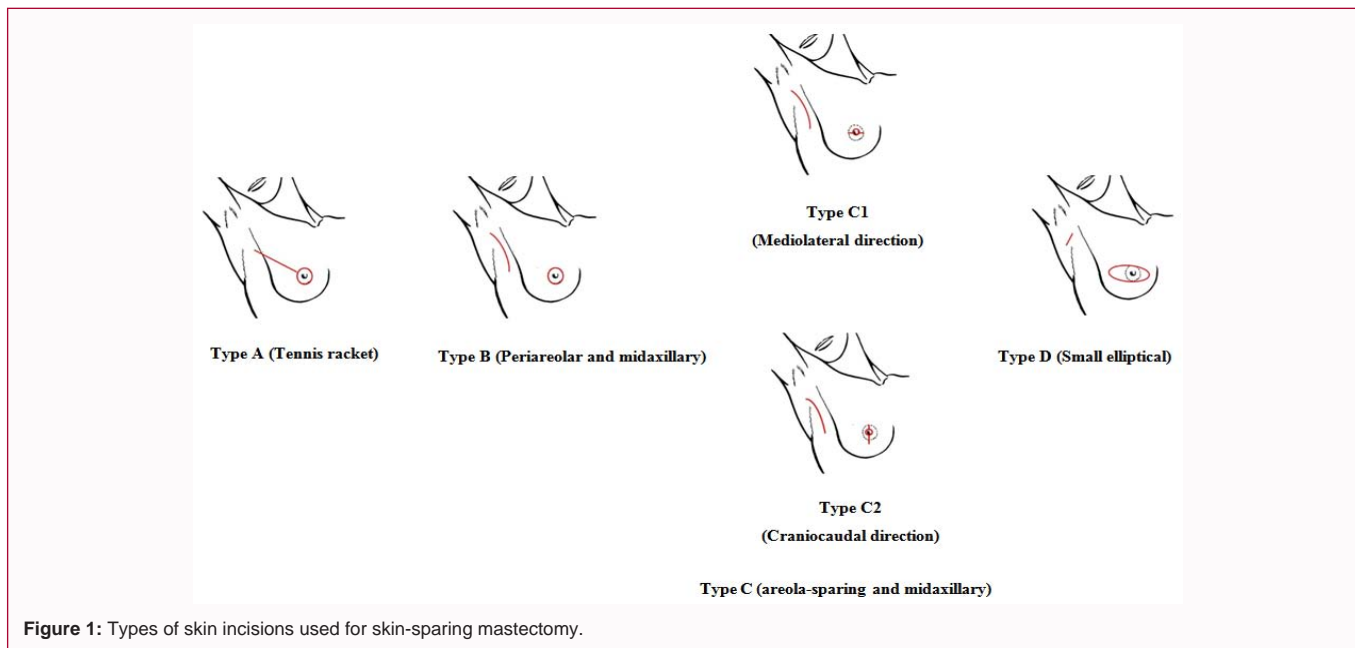


Figure 1: Types of skin incisions used for skin-sparing mastectomy.

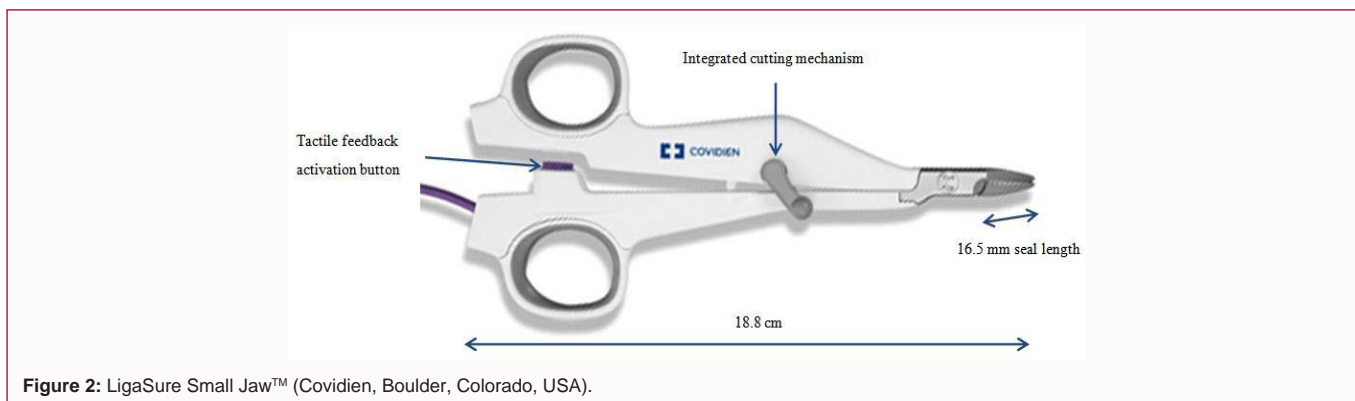


Figure 2: LigaSure Small Jaw™ (Covidien, Boulder, Colorado, USA).

using a Vessel Sealing System (VSS) (LigaSure Small Jaw™, Covidien, Boulder, Colorado, USA) in April 2012 (Figure 2) that achieves simultaneous hemostasis with severing.

We herein report our experience of the vessel sealing system’s contributions to improving surgical and cosmetic outcomes in these patients despite the limitations associated with these approaches.

### Patients and Methods

Among 365 Japanese women with breast cancer who underwent mastectomy at Jikei University hospitals between February 1, 2007 and August 31, 2017, we identified 148 skin-sparing mastectomy cases that employed either the periareolar incision with midaxillary line incision (Type B) or areola-sparing incision with midaxillary line incision (Type C) that was immediately followed by breast reconstruction by plastic surgeons. Skin-sparing mastectomy was planned to remove the nipple with or without the areola complex, biopsy scars (excluding the core needle biopsy scar), and the entire breast parenchyma [4].

Figure 3 shows our favorite devices for SSM: a heated scalpel system (Thermal Scalpel™, Hemostatix Medical Technologies, LLC, Bartlett, TN, USA), vessel sealing system (LigaSure Small Jaw™, Covidien, Boulder, Colorado, USA), bipolar scissors (Ethicon POWERSTAR™ scissors, Johnson & Johnson Co, New Brunswick,



Figure 3: The authors’ favorite devices for SSM: (a) Thermal Scalpel™, (b) LigaSure Small Jaw™, (c) Power Star scissors™.

NJ, USA). We have used bipolar scissors, heated scalpel system and conventional electrocautery in creating skin flap between February 2007 and March 2012. Since April 2012, we have applied VSS instead of bipolar scissors.

We assigned the 148 patients to either of 2 groups of 74 each, those in whom VSS was not used (non-VSS group) and those in whom it was used (VSS group), retrospectively evaluated the duration

**Table 1:** Results and characteristics of patients, tumors, operative procedures, type of axillary management.

		non-VSS	VSS	P value
Number of cases		74	74	
Age (years)		48.2 ± 9.8(29-71)	47.3 ± 9.4(32-74)	NS
Stage				
	0, Tis	13	19	NS
	I	24	20	
	Ila	26	28	
	Iib	11	7	
Type of skin approach				
	B	54	41	0.03
	C1	20	6	
	C2	0	27	
Axillary management				
	SLNB	41	59	0.002
	SLNB → ALND	17	8	
	ALND	16	7	
Reconstruction procedure				
	LD	23	17	<0.000
	LD+SBI	0	10	
	TRAM	20	17	
	DIEP	30	0	
	TE/SBI	1	30	
SSM				
	time (minutes)	133.2 ± 30.0	132.7 ± 24.4	NS
	blood loss (g)	213.6 ± 133.5	105.8 ± 97.2	<0.000
	length of Ax. Incision (mm)	135.7 ± 19.5	86.3 ± 15.4	<0.000
	P/O hospital stays (days)	14.9 ± 3.9	10.9 ± 3.6	<0.000

ALND: Axillary Lymph Node Dissection; Ax: Axilla; DIEP: Deep Inferior Epigastric Perforator; LD: Latissimus Dorsi; P/O: Postoperative; SBI: Silicon Breast Implant; SLNB: Sentinel Lymph Node Biopsy; SSM: Skin-sparing Mastectomy; TE: Tissue Expander; TRAM: Transverse Rectus Abdominis Muscle; VSS: Vessel Sealing System (referring to those cases in which the system was used; non-VSS, those in which the system was not used)

of SSM, blood loss during SSM, length of midaxillary line incision, and duration of postoperative hospital stays, and then analyzed statistics using the chi-square test and t-test, with  $p < 0.05$  considered significant difference.

## Results

Table 1 delineates the characteristics of our study patients and their tumors, operative procedures, and type of axillary management. Tumors were staged based on the system of the American Joint Committee on Cancer. The mean age of patients was 48.2 years in the non-VSS group and 47.3 years in the VSS group. The 2 groups did not differ significantly with regard to staging classification or average operation time (133.2 minutes [non-VSS group]; 132.7 minutes [VSS group]). However, they did differ significantly with regard to intraoperative blood loss (213.6 g [non-VSS]; 105.8 g [VSS]) ( $p < 0.000$ ), length of midaxillary line incision (135.7 mm [non-VSS]; 86.3 mm [VSS]) ( $p < 0.000$ ), and postoperative hospital stays (14.9 days [non-VSS]; 10.9 days [VSS]) ( $p < 0.000$ ) as well as type of skin approach employed ( $p = 0.03$ ), axillary management ( $p = 0.002$ ), and reconstruction procedure ( $p < 0.000$ ).

When performing ALND or SLNB alone in the non-VSS group and the VSS group respectively, there were no significant differences

of the results (time of SSM, blood loss during SSM, and length of axillary incision) and the type of skin approaches (Table 2).

Table 3 shows the characteristics of 48 cases with axillary dissection alone, 33 that were classified in the non-VSS group and 15 in the VSS group. Those in the non-VSS group experienced significantly shorter operation duration (158.5 minutes) than that of the VSS group (172.9 minutes) ( $p = 0.01$ ) and significantly longer midaxillary line incision ( $p < 0.000$ ) and included significantly fewer cases that utilized device-based reconstruction ( $p = 0.05$ ).

Table 4 delineates the characteristics of 100 cases with sentinel lymph node biopsy alone, 41 that were classified in the non-VSS group and 59 in the VSS group. The non-VSS group experienced significantly shorter operation duration than the VSS group (112.9 minutes [non-VSS]; 122.6 minutes [VSS]) and underwent significantly fewer device-based reconstructions ( $p < 0.000$ ). However, the VSS group demonstrated significantly better findings with regard to blood loss during SSM (200.5 g [non-VSS]; 96.8 g [VSS]) ( $p < 0.000$ ), length of midaxillary line incision (132.1 mm [non-VSS]; 82.8 mm [VSS]) ( $p < 0.000$ ), and postoperative hospital stay (13.8 days [non-VSS]; 10.3 days [VSS]) ( $p < 0.000$ ).

Table 5 shows the characteristics of cases using the periareolar

**Table 2:** Relationship between type of skin approaches and results (time of SSM, blood loss during SSM, length of axillary incision) when performing ALND or SLNB alone in the non-VSS group and the VSS group respectively.

		Number of Patients	time (minutes)	P-value	blood loss (g)	P-value	length of Ax. incision (mm)	P-value
non-VSS	TypeB ALND	27	159.4±18.2	NS	221.7±165.2	NS	138.1±19.8	NS
	TypeC ALND	6	154.2±15.4		267.5±131.0		150.0±11.9	
	TypeB SLNB	27	109.4±21.5	NS	179.6±99.2	NS	127.0±17.5	NS
	TypeC SLNB	14	119.6±18.6		240.7±104.4		141.8±17.9	
VSS	TypeB ALND	11	169.1±13.5	NS	137.3±94.1	NS	100.9±13.1	NS
	TypeC ALND	4	181.3±17.5		152.5±120.7		97.5±26.8	
	TypeB SLNB	30	124.6±14.6	NS	100.2±89.5	NS	87.8±12.8	NS
	TypeC SLNB	29	121.2±12.2		93.3±97.9		77.6±9.8	

ALND: Axillary Lymph Node Dissection; Ax: Axilla; SLNB: Sentinel Lymph Node Biopsy; SSM: Skin-Sparing Mastectomy; VSS: Vessel Sealing System (referring to those cases in which the system was used; non-VSS, those in which the system was not used)

**Table 3:** Results and characteristics of patients, operative procedure with ALND alone.

		non-VSS	VSS	P value
Number of cases		33	15	
Age (years)		46.5 ± 7.7	43.9 ± 4.5	NS
Type of skin approach				
	B	27	11	NS
	C1	6	1	
	C2	0	3	
Reconstruction procedure				
	LD	8	4	0.05
	LD+SBI	0	2	
	TRAM	11	6	
	DIEP	13	0	
	TE/SBI	1	3	
SSM				
	time (minutes)	158.5 ± 17.8	172.9 ± 16.0	0.01
	blood loss (g)	230.0 ± 160.5	150.7 ± 99.2	NS
	length of Ax. incision (mm)	140.3 ± 19.2	100.0 ± 18.5	<0.000
	P/O hospital stays (days)	16.2 ± 5.2	13.5 ± 4.3	NS

ALND: Axillary Lymph Node Dissection; Ax: Axilla; DIEP: Deep Inferior Epigastric Perforator; LD: Latissimus Dorsi; P/O: Postoperative; SBI: Silicon Breast Implant; TE: Tissue Expander; TRAM: Transverse Rectus Abdominis Muscle; VSS: Vessel Sealing System (referring to those cases in which the system was used; non-VSS, those in which the system was not used)

incision with midaxillary line incision (Type B) approach with sentinel lymph node biopsy alone. None of these cases utilized device-based reconstructions. Of these 57 cases, 27 were classified in the non-VSS group and 30 in the VSS group. Operation time was significantly shorter for the non-VSS group than the VSS group (109.4 minutes [non-VSS]; 124.1 minutes [VSS]) ( $p=0.004$ ). However, results for the VSS group were better with regard to blood loss during SSM (179.6 g [non-VSS]; 100.2 g [VSS]) ( $p=0.003$ ), length of midaxillary line incision (127.0 mm [non-VSS]; 87.8 mm [VSS]) ( $p<0.000$ ), and duration of postoperative hospital stays (14.0 days [non-VSS]; 11.9 days [VSS]) ( $p=0.001$ ).

Postoperative complications included one case with hemorrhage that required reoperation, 5 cases with insufficient circulation that resulted in skin necrosis (4 cases) and flap loss (one case), and 2 cases in which infection developed at the surgical site, one of which required removal of the tissue expander.

## Discussion

Skin-Sparing Mastectomy (SSM) attempts to preserve all the breast skin. When we began these surgeries at the beginning of 2003, as previously reported, we initially used a periareolar incision with lateral extension (Type A) and then adopted a small transverse elliptical incision that contained the entire nipple areolar complex with a transverse axillary incision (Type D) just after the introduction of device-based breast reconstruction [6].

Just as in non-skin-sparing mastectomy, these 2 incision types allowed clear exposure of the surgical field with relative ease, but the periareolar incision with midaxillary line incision (Type B) and areola-sparing incision with midaxillary line incision (Type C) that are frequently used to improve postoperative cosmetic outcomes require greater specific surgical skill for sufficient exposure of the operative field to remove total breast tissue.

**Table 4:** Results and characteristics of patients, operative procedure with SLNB alone.

		non-VSS	VSS	P value
<b>Number of cases</b>		41	59	
<b>Age (years)</b>		49.5 ± 11.0	48.2 ± 9.9	NS
<b>Type of skin approach</b>				
	B	27	30	NS
	C1	14	5	
	C2	0	24	
<b>Reconstruction procedure</b>				
	LD	15	13	<0.000
	LD+SBI	0	8	
	TRAM	9	11	
	DIEP	17	0	
	TE/SBI	0	27	
<b>SSM</b>				
	time (minutes)	112.9 ± 21.0	122.6 ± 13.6	0.01
	blood loss (g)	200.5 ± 105.1	96.8 ± 93.8	<0.000
	length of Ax. Incision (mm)	132.1 ± 19.0	82.8 ± 12.5	<0.000
	PIO hospital stays (days)	13.8 ± 1.8	10.3 ± 3.1	<0.000

Ax: Axilla; DIEP: Deep Inferior Epigastric Perforator; LD: Latissimus Dorsi; P/O: Postoperative; SBI: Silicon Breast Implant; SLNB: Sentinel Lymph Node Biopsy; TE: Tissue Expander; TRAM: Transverse Rectus Abdominis Muscle; VSS: Vessel Sealing System (referring to those cases in which the system was used; non-VSS, those in which the system was not used)

**Table 5:** Results and characteristics of patients, operative procedure using Type B approach with SLNB alone.

		non-VSS	VSS	P value
<b>Number of cases</b>		27	30	
<b>Age (years)</b>		49.1 ± 11.7	47.0 ± 9.3	NS
<b>Reconstruction procedure</b>				
	LD	14	13	NS
	LD+SBI	0	6	
	TRAM	4	11	
	DIEP	9	0	
	TE/SBI	0	0	
<b>SSM</b>				
	time (minutes)	109.4 ± 21.5	124.1 ± 14.6	0.004
	blood loss(g)	179.6 ± 99.2	100.2 ± 89.5	0.003
	length of Ax. incision (mm)	127.0 ± 17.5	87.8 ± 12.8	<0.000
	P/O hospital stays (days)	14.0 ± 2.0	11.6 ± 2.8	0.001

Ax: Axilla; DIEP: Deep Inferior Epigastric Perforator; LD: Latissimus Dorsi; P/O: Postoperative; SBI: Silicon Breast Implant; SLNB: Sentinel Lymph Node Biopsy; TE: Tissue Expander; TRAM: Transverse Rectus Abdominis Muscle; VSS: Vessel Sealing System (referring to those cases in which the system was used; non-VSS, those in which the system was not used)

Prior to the introduction of the VSS (LigaSure Small Jaw™) in the spring of 2012, exposure of the surgical field was accomplished by extending the midaxillary line incision, a technique that reduced operation time but could not address issues associated with intraoperative hemorrhage. Vessel sealing system was expected to overcome these issues. This is accomplished by placing the vessels and bundle tissues between the 2 electrodes in the jaw of the unit's handpiece and applying high-frequency current from the ForceTriad™ energy platform between the 2 poles to generate Joule heat that fuses collagen in the vessel wall to seal the vessels as tissue is severed with the blade of the jaw. Although the length of the instrument is only 18.8 cm, the lengths of the seal (16.5 mm) and cut (14.7 mm) are considered sufficient to treat relatively small breasts, and it was

adequate in our patients. In addition, the 28.8° jaw angle is suitable for the subcutaneous detachment, and the reduced thermogenesis compared to that of other devices is convenient to avoid heat damage of the skin [8].

The utility of the vessel sealing system (LigaSure Small Jaw™) to reduce operation time and control hemorrhage in surgery of the thyroid area has been reported [9], and Chang and associates have reported similar advantages in its use in SSM for breast cancer [10]. We did not observe significant shorter operation time in our cases, but differences were significant in blood loss during SSM, length of midaxillary line incision, and duration of postoperative hospital stays which is determined based on the volume of fluid drain loss. Because

axillary management differed between the 2 groups, to exclude bias we compared patients who underwent only axillary lymph node dissection, and those who underwent only sentinel lymph node biopsy, between non-VSS group and VSS group. Surprisingly, the results showed significantly longer operation time in the VSS group, though in both ALND and SLNB cases, the length of the midaxillary line incision was about 4 cm to 5 cm shorter in the VSS group. If there was no such difference in length of midaxillary line incision, we believe that the use of VSS had contributed to shorten the operation time. We have used VSS, heated scalpel system and conventional electrocautery in creating skin flap of SSM since April 2012, although we had used bipolar scissors instead of VSS between February 2007 and March 2012. When using VSS that can achieve simultaneous hemostasis and severing, we can perform creating skin flap even under poor exposure of operative field. Therefore when using VSS, we can complete almost whole skin flap creation from areolar approach alone. And we consider that VSS contributes to reduce the intraoperative blood loss and to shorten the length of axillary incision.

The length of blade part of bipolar scissors is about twice as compared with VSS one. It contributed to the speedy creating skin flap, resulting in shortening of operation time. However, when using bipolar scissors instead of VSS, once an intraoperative bleeding was happened under the poor exposure of operative field, it was more difficult for hemostasis compared with VSS. Therefore we have tried to remove the whole breast under using gauze compression as fast as possible to complete hemostasis. Furthermore, in creating skin flap we had preferred axillary approach to get better exposure of operative field than areolar one even if needed longer length of axillary incision when using bipolar scissors. And as a result, longer axillary incision contributed to shorten the time of SSM. Although extending the midaxillary line incision can shorten operation time without use of the VSS, the resulting longer surgical scar can compromise cosmetic results.

In addition, reconstructive procedures may affect the duration of postoperative hospital stays. Focusing on cases with only SLNB who underwent the Type B incision with autologous tissue reconstruction (Table 5), we observed significantly reduced postoperative hospital stays in the VSS group, which suggests a cost-saving advantage in the use of the vessel sealing system.

Our findings suggest that use of the current vessel sealing system in skin-sparing mastectomies that employ Types B and C incisions can reduce intraoperative hemorrhage, length of midaxillary line incision, and duration of postoperative hospital stays. And thereby we consider that use of VSS compensate for the drawbacks such as limited exposure of the surgical field with these approaches.

From our experience of using VSS, hopefully, we believe that lengthening the device from the tip of the jaw to the integrated cutting mechanism by about 3 cm would yield a more user-friendly tool.

## Conclusion

Our use of the vessel sealing system in skin-sparing mastectomies significantly reduced intraoperative hemorrhage, improved postoperative cosmetic outcomes by shortening the midaxillary line surgical wound scar, and reduced costs by reducing the duration of postoperative hospital stays. We therefore consider the system useful as a means to compensate for drawbacks associated with this surgical procedure.

## Acknowledgement

The authors would like to thank Rosalyn A Uhrig for English-language editorial assistance in the preparation of our manuscript.

## References

1. Halsted WS. I. The Results of Radical Operations for the Cure of Carcinoma of the Breast. *Ann Surg.* 1907;46(1):1-19.
2. Kinoshita S, Nojima K, Takeishi M, Imawari Y, Kyoda S, Hirano A, et al. Retrospective comparison of non-skin-sparing mastectomy and skin-sparing mastectomy with immediate breast reconstruction. *Int J Surg Oncol.* 2011;2011:876520.
3. Fisher B. From Halsted to prevention and beyond: advances in the management of breast cancer during the twentieth century. *Eur J Cancer.* 1999;35(14):1963-73.
4. Toth BA1, Lappert P. Modified skin incisions for mastectomy: the need for plastic surgical input in preoperative planning. *Plast Reconstr Surg.* 1991;87(6):1048-53.
5. Kinoshita S, Kyoda S, Hirano A, Akiba T, Nojima K, Uchida K, et al. Clinical comparison of four types of skin incisions for skin sparing mastectomy and immediate breast reconstruction. *Surg Today.* 2014;44:1470-5.
6. Kinoshita S, Nojima K, Miyake R, Shimada N, Hirano A, Uchida K, et al. Clinical assessment of skin incisions used for skin-sparing mastectomy. *Internal Med Review.* 2016;2(8):197.
7. Kinoshita S, Nojima K, Takeyama H, Uchida K. Four types of skin incisions for skin-sparing mastectomy with immediate breast reconstruction. In: Shiffman MA, editor. *Breast reconstruction: art, science, and new clinical techniques.* Cham, Switzerland: Springer; 2016. p. 547-54.
8. Smith CT, Zarebczan B, Alhefdhi A, Chen H. Infrared thermographic profiles of vessel sealing devices on thyroid parenchyma. *J Surg Res.* 2011;170(1):64-8.
9. Vidal O, Saavedra-Perez D, Valentini M, Astudillo E, Fernández-Cruz L, García-Valdecasas JC. Surgical outcomes of total thyroidectomy using the LigaSure™ SmallJaw versus LigaSure Precise™: A retrospective study of 2000 consecutive patients. *Int J Surg.* 2017;37:8-12.
10. Chang YW, Kim HS, Jung SP, Woo SU, Lee JB, Bae JW, et al. Comparison of skin-sparing mastectomy using LigaSure™ Small Jaw and electrocautery. *World J Surg Oncol.* 2017;15(1):129.