



## Treatment of a Spontaneous Vertebral Artery-Vertebral Vein Arteriovenous Fistula (AVF) in a Paediatric Patient

Sajjad Muhammad<sup>1\*</sup>, Jussi Numminen<sup>2</sup>, Atte Karppinen<sup>1</sup> and Mika Niemelä<sup>1</sup>

<sup>1</sup>Department of Neurosurgery, University of Helsinki and Helsinki University Hospital, Finland

<sup>2</sup>Department of Neuroradiology, University of Helsinki and Helsinki University Hospital, Finland

### Abstract

**Background:** Extracranial vertebral artery AVF are extremely rare and there is no standardized treatment for such aneurysms. Treatment of an unruptured V1-segment vertebral artery-vertebral vein fistula in a pediatric patient has rarely been described in literature.

**Case Presentation:** We present a case of a 6-year-old child with an incidental V1-segment vertebral artery AVF. During a routine pediatric auscultation of the heart, a bruit over the supraclavicular region was heard. Initial ultrasound showed suspicion of aneurysm of vertebral artery. CT-angiogram and DSA showed a V1-segment vertebral artery fistula. The patient was treated successfully with coil embolization. The vertebral artery was spared and reconstructed successfully during embolization without any complications. The child is now 9 years old and follow-up MRI scans in 2018 showed complete occlusion 3 years after intervention.

**Conclusion:** Endovascular coiling sparing vertebral artery is a safe, effective, and reliable treatment modality in pediatric cases of V1-segment vertebral artery fistula with the adjacent vein.

**Keywords:** V1-segment vertebral artery fistula; Coil embolization; Pediatric case

### Abbreviations

AVF: Arteriovenous Fistula; DSA: Digital Subtraction Angiography

### OPEN ACCESS

#### \*Correspondence:

Sajjad Muhammad, University of Helsinki and Helsinki University Hospital, Finland, Tel: 00358-503757488;

E-mail: ext-sajjad.muhammad@hus.fi

Received Date: 10 Apr 2019

Accepted Date: 28 May 2019

Published Date: 04 Jun 2019

#### Citation:

Muhammad S, Numminen J, Karppinen A, Niemelä M. Treatment of a Spontaneous Vertebral Artery-Vertebral Vein Arteriovenous Fistula (AVF) in a Paediatric Patient. *Clin Surg.* 2019; 4: 2451.

Copyright © 2019 Sajjad Muhammad.

This is an open access article distributed under the Creative Commons Attribution License, which permits unrestricted use, distribution, and reproduction in any medium, provided the original work is properly cited.

### Introduction

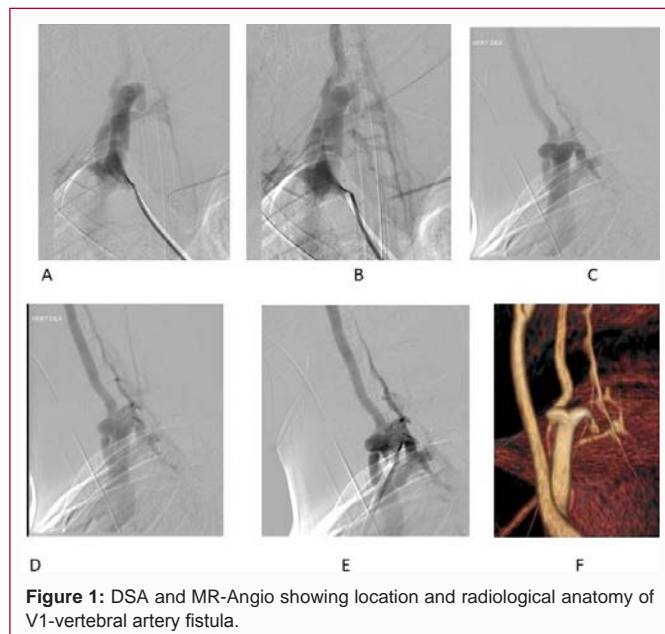
Extracranial vertebral artery V1-segment making AVF with vertebral vein are extremely rare. These fistulas are challenging to manage because of the high risk of ischemic complications to the posterior circulation. Both surgical and endovascular treatments carry potential risks and technical difficulties. The best treatment options are still controversial in such pediatric cases [1,2]. Here we show a pediatric case of a successfully treated v1-segment fistula with adjacent vein utilizing endovascular coils to close the fistula and to reconstruct the parent artery.

### Case Presentation

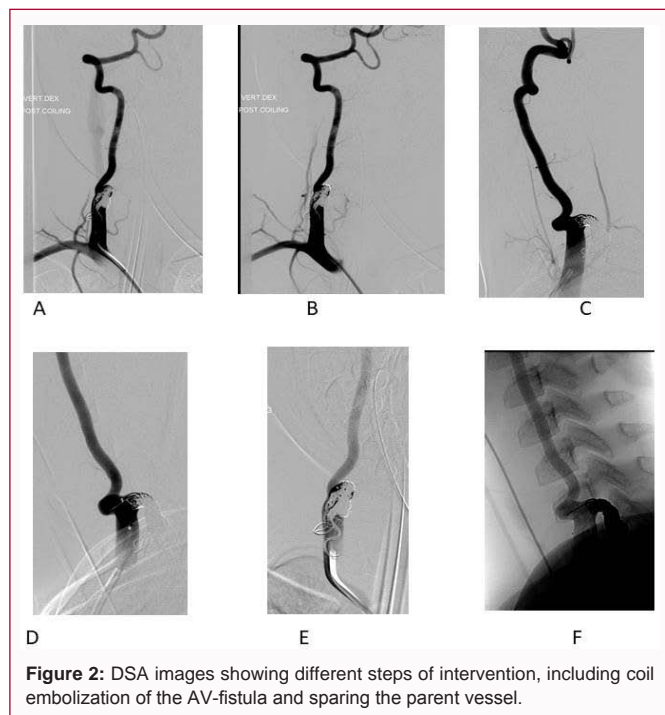
We present a case of a 6-year-old child with an incidental V1-segment vertebral artery fistula. During a routine pediatric auscultation of the heart, a bruit over the carotid was heard. Initial ultrasound showed suspicion of aneurysm of vertebral artery. DSA showed a V1-segment vertebral artery fistula (Figure 1A-1E). The patient was treated successfully with coil embolization. The vertebral artery was spared and reconstructed successfully during embolization without any complications (Figure 2A-2E). The child is now 9 years old and follow-up MRI scans showed complete occlusion 3 years after intervention.

### Endovascular coiling

After interdisciplinary discussion we decided upon the endovascular treatment of choice. The contralateral vertebral artery was normal and the probability of tolerating ipsilateral vertebral artery occlusion was high in this patient. An endovascular procedure with deposition of Guglielmi Detachable Coils to close the arteriovenous fistula was performed with the aim of interrupting the flow to the fistula point. The ipsilateral vertebral artery was spared and was filling after the intervention (Figure 2). Post-intervention images show a complete occlusion of the fistula and patent parent vessel (Figure 2). No post-interventional neurological deficit was noted. The child was discharged from hospital after 4 days. The patient was completely symptom-free at a follow up of 3 years. Follow-up MRI scans in 2018 showed unchanged complete occlusion of AV-fistula with



**Figure 1:** DSA and MR-Angio showing location and radiological anatomy of V1-vertebral artery fistula.

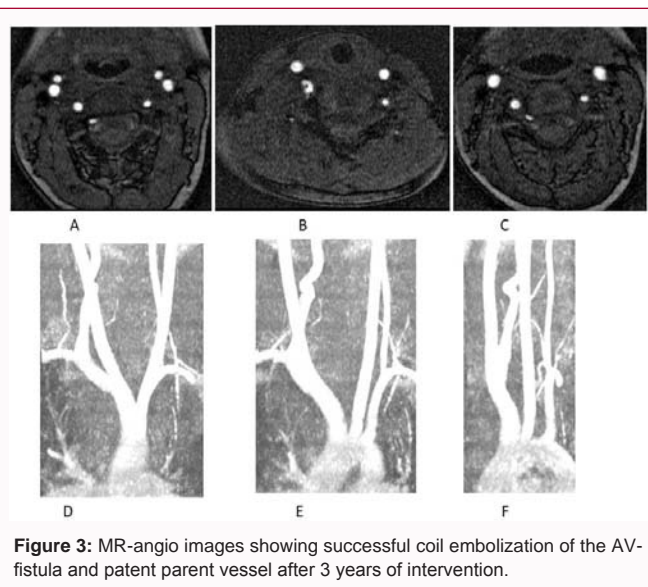


**Figure 2:** DSA images showing different steps of intervention, including coil embolization of the AV-fistula and sparing the parent vessel.

unchanged patency of the parent vessel.

## Discussion

We present a pediatric case of V1 segment vertebral artery-vertebral vein fistula successfully treated with coil embolization with a stable long-term outcome. Extracranial vertebral artery fistulas are extremely rare. Most extracranial vertebral artery aneurysms and fistula are located in the V3 segment followed by the V1 segment and are even rarer in pediatric populations [3]. These fistulas are diagnosed secondary to an embolic infarct or incidentally as a palpable mass. Patients with connective tissue disorders, including Ehlers-Danlos syndrome, Marfan syndrome, and neurofibromatosis type I are at higher risk of developing extracranial vertebral artery aneurysms and AV fistula. A ruptured vertebral artery aneurysm causing local pain



**Figure 3:** MR-angio images showing successful coil embolization of the AV-fistula and patent parent vessel after 3 years of intervention.

and hematoma and often making fistula with adjacent vein are found in this particular group of patients [1,4-6]. In contrast, we treated a pediatric patient without any connective tissue disorder or trauma who presented with an incidental finding during heart auscultation by a pediatrician. CT angiography and DSA are the standard tools to diagnose and reveal the anatomy of vasculature and to plan treatment. Treatment options include ligation, isolation, balloon embolization, onyx embolization, and coil embolization [5,3,7-10]. There is no single standardized treatment option for V1-segment vertebral artery fistula. The anatomical location at the C7-Th1 level might be difficult for end-to-side anastomosis of vertebral artery with carotid artery, especially in a child. We decided upon coil embolization of the fistula. We could reconstruct the parent vessel. While endovascular modalities have a risk of embolic stroke, our patient tolerated the procedure well. The fistula was completely occluded and patient had no adverse events. A long-term follow-up MR-angiography in 2018 showed unchanged occlusion of both dissecting aneurysm and fistula. The patient currently has no clinical symptoms and is attending school in third grade.

## Conclusion

Endovascular coiling is a fast, effective, and reliable treatment modality in pediatric cases of V1-segment vertebral artery making a fistula with the adjacent vein.

## Declaration

**Ethics approval and consent to participate:** All procedures performed in this study involving human participants were in accordance with the ethical standards of the research committee of University of Helsinki and with the 1964 Helsinki declaration and its later amendments or comparable ethical standards. An approval from local ethical committee for an anonymised case report was not necessary.

**Consent for publication:** The parents of the child were provided written informed consent to participate their child in this study and publication. Images or pictures without patient identity are used.

## Funding

We are thankful to the Ehrnrooth Foundation for funding to SM

for a clinical vascular and skull base fellowship at the department of Neurosurgery in Helsinki University Hospital.

## Acknowledgement

We are thankful to Ehrnrooth foundation for supporting SM for the clinical skull base and vascular fellowship.

## References

1. Oderich GS, Sullivan TM, Bower TC, Gloviczki P, Miller DV, Babovic-Vuksanovic D, et al. Vascular abnormalities in patients with neurofibromatosis syndrome type I: clinical spectrum, management, and results. *J Vasc Surg.* 2007;46(3):475-84.
2. Shang EK, Fairman RM, Foley PJ, Jackson BM. Endovascular treatment of a symptomatic extracranial vertebral artery aneurysm. *J VascSurg.* 2013;58(5):1391-3.
3. Ronchey S, Serrao E, Kasemi H, Fazzini S, Mangialardi N. Endovascular treatment of extracranial vertebral artery aneurysm and aberrant right subclavian artery aneurysm. *J Cardiovasc Surg (Torino).* 2014;55(2):265-9.
4. Hiramatsu H, Matsui S, Yamashita S, Kamiya M, Yamashita T, Akai K, et al. Ruptured extracranial vertebral artery aneurysm associated with neurofibromatosis type I. *Neurol Med Chir (Tokyo).* 2012;52(6):446-9.
5. Kollmann D, Kinstner C, Teleky K, Wressnegger A, Koppensteiner R, Huk I, et al. Successful treatment of a ruptured extracranial vertebral artery aneurysm with onyx instillation. *Ann Vasc Surg.* 2016;36:290.e297-290.e210.
6. Sumimura J, Nakao K, Miyata M, Kamiike W, Yokota H, Kawashima Y. Vertebral aneurysm of the neck. *J Cardiovasc Surg (Torino).* 1988;29(1):63-5.
7. Ishimitsu H, Namba S, Tsuboi M. [Unilateral extracranial ligation of the vertebral artery as a treatment for a vertebral aneurysm (author's transl)]. *No ShinkeiGeka.* 1978;6(8):815-20.
8. Ullery BW, Foley PJ, Brinster CJ, Pochettino A, Fairman RM. A novel two-stage surgical approach for the treatment of symptomatic supra-aortic artery aneurysms. *Vascular.* 2012;20(4):236-40.
9. Xu N, Zhang K, Meng H, Liu T, Wang H. Treatment of spontaneous dissecting aneurysm in extracranial vertebral artery with covered stent. *World Neurosurg.* 2018;110:e330-2.
10. Zhang H, Zhao Y, Naha G, Hou C, Wang Z, Yang X. Successful management of extracranial vertebral artery aneurysm by artificial vessel reconstruction. *World Neurosurg.* 2018;116:249-54.