Clinics in Surgery

Case Report
Published: 24 Feb, 2021

Transverse Congenital Transmesocolic Hernia: A Case Report and Review of the Literature

Nolasco Vaz J[1], Dias R[2], Faria A[1], Sousa M[1], Timóteo J[1], Fernandes S[1], Nogueira F[1] and Coutinho J[1]*

[1]Department of General Surgery, Centro Hospitalar Universitário Lisboa Norte, Portugal

[2]Department of Radiology, Centro Hospitalar Universitário Lisboa Norte, Portugal

Abstract

Internal Hernia (IH) is a rare cause of Small Bowel Obstruction (SBO) associated with a high risk of strangulation and mortality if left untreated. Due to increasing complex abdominal surgeries, the incidence of acquired IH has also increased over the years as opposed to congenital IH that remain relatively unchanged. Regarding the several types of IH, congenital transmesocolic hernia of the transverse colon is a very rare type with only few cases previously reported in the literature.

We here in report the case of a 77-year-old female patient who presented to our emergency department with an acute abdominal pain and vomiting. The plain abdominal radiograph demonstrated signs of SBO and the abdominal computed tomography revealed findings highly suggestive of an IH. A congenital transmesocolic hernia of the transverse colon was confirmed on laparotomy with reduction and closure of the defect leading to full recovery of the patient. In this case report, the clinical pictures and radiological features are highlighted together with a review of the literature.

Although CT is currently the mainstay imaging in the workup of SBO, its accuracy to preoperatively diagnose and distinguish among several types of IH remain rather low. Thus, when an IH is suspected, prompt surgical management can avoid bowel ischemia and reduce complications. A high conversion rate to an open approach is often needed due to work space limitations.

Keywords: Transverse transmesocolic hernia; Congenital internal hernia; Small bowel obstruction

OPEN ACCESS

***Correspondence:**
Joana Nolasco Vaz, Department of Surgery, Centro Hospitalar Universitário Lisboa Norte, Avenida Professor Egas Moniz, 1649-035, Lisboa, Portugal, Tel: +351-963157940;
E-mail: j.nolascovaz@hotmail.com

Received Date: *15 Jan 2021*
Accepted Date*: 19 Feb 2021*
Published Date*: 24 Feb 2021*

Citation:
Nolasco Vaz J, Dias R, Faria A, Sousa M, Fernandes S, Nogueira F, et al. Transverse Congenital Transmesocolic Hernia: A Case Report and Review of the Literature. Clin Surg. 2021; 6: 3082.

Abbreviations

ARDS: Acute Respiratory Distress Syndrome; CRP: C-Reactive Protein; CT: Computed Tomography; IH: Internal Hernia; SBO: Small Bowel Obstruction

Introduction

An IH is defined as the protrusion of abdominal viscera through a peritoneal or mesenteric aperture within the confines of the abdominal cavity. Acquired transmesocolic hernias secondary to abdominal surgery are becoming more common, but congenital transverse transmesocolic hernias remain extremely rare. Given their non-specific symptoms and imaging findings, preoperative diagnosis is particularly challenging.

We herein report a case of congenital transverse transmesocolic hernia in a female patient presenting with SBO and we review the most relevant clinical, imaging and surgical features among the published literature.

Case Presentation

A 77-year-old female patient with history of arterial hypertension, dyslipidemia and a median laparotomy for an emergent cholecystectomy 18 years earlier was admitted in the emergency department with abdominal pain and vomiting for 3 days. She also referred chronic constipation, aggravated in the last few months. A colonoscopy performed 3 years earlier revealed diverticulosis. On physical evaluation her abdomen was tender but with negative Blumberg sign. Laboratorial workup pointed an inflammatory response with leukocytosis (16520/µL), elevated C-reactive protein (4.18 mg/dL) but normal lactate (10 mg/dL). A plain abdominal radiograph obtained at admission demonstrated signs of SBO (Figure 1) and the patient was started on conservative measures with nasogastric drainage and intravenous hydration. A non-enhanced Computed Tomography (CT) (Figure 2) subsequently performed revealed multiple dilated and predominantly fluid-filled small

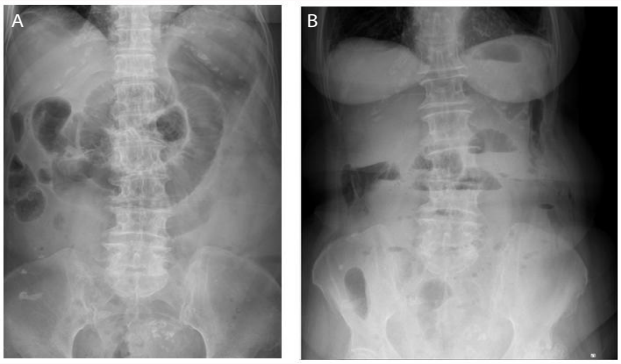

Figure 1: Plain abdominal radiograph. A) Supine abdominal radiograph show dilated small-bowel loops partially filled with gas outlining the valvulae conniventes and clustered centrally. Distended stomach is also noticed. B) Upright abdominal radiograph shows multiple and large air fluid levels that correlates with same dilated small bowel lops seen on supine radiograph.

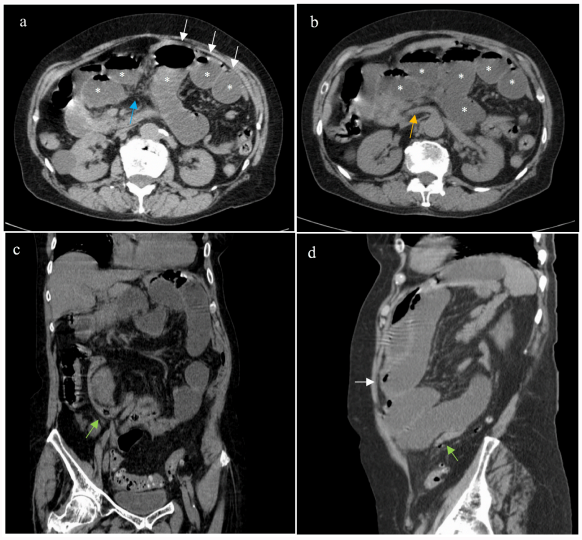

Figure 2: Abdominal non-enhanced CT. Multiple dilated and predominantly fluid-filled small bowel loops (*) abnormally clustered in the upper abdominal quadrants with the obstructed loops directly abutting the abdominal wall (white arrow). It was also noticed an inferior displacement of the transverse colon (green arrow) and the superior mesenteric artery was displaced to the right (orange arrow) with crowding, stretching, engorgement, and displacement of its visceral branches (Blue arrow).

bowel loops abnormally clustered in the upper abdominal quadrants directly abutting the abdominal wall and displacement of the overlying omental fat. It was also noticed an inferior displacement of the transverse colon and the superior mesenteric artery was displaced to the right with crowding, stretching, engorgement, and displacement of its visceral branches. These findings were consistent with an internal hernia. In addition, subtle signs of bowel ischemia were noticed by the presence of mesenteric edema and intraperitoneal fat stranding. The patient underwent median laparotomy that confirmed a transverse transmesocolic hernia, with almost all the small bowel herniated in the lesser sac, through a dilated angle of Treitz (Figure 3). There were no other findings or evidence of mal-rotation. Bowel viability allowed hernia content reduction and defect closure. Post-operative ileus complicated her stay, but on the 6th post-operative day she was fully recovered and discharged. On follow up the patient denied complaints and clinical examination was innocent.

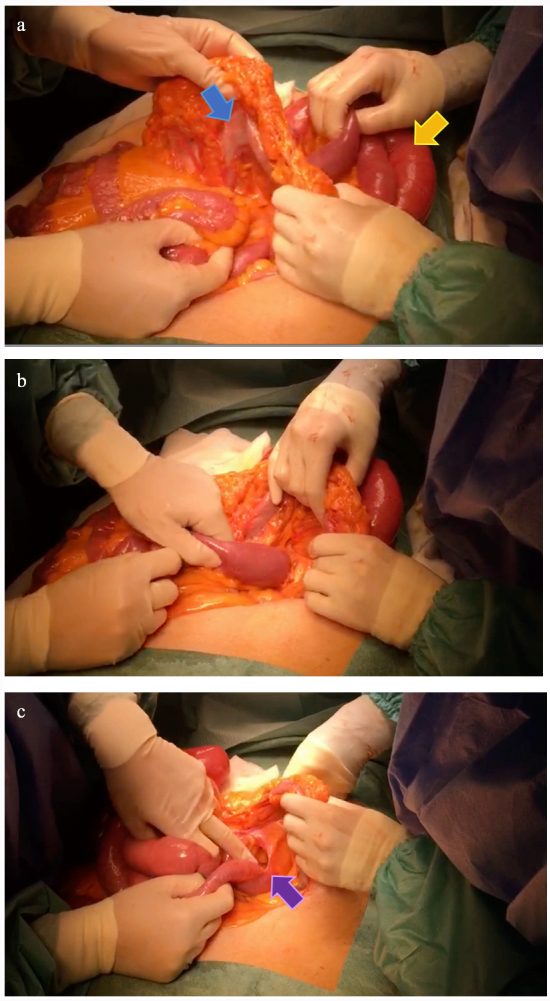

Figure 3: Transverse colon (blue arrow) transmesenteric hernia reduction. Note the dilated small bowel in open lesser sac (yellow arrow). Transmesocolic 5 cm × 5 cm defect (purple arrow) above Treitz angle, to the left of the middle colic artery.

Table 1: Classification and incidence of congenital internal hernia.

Retroperitoneal	Intraperitoneal
Paranormal opening	Anomalous opening
Paraduodenal / mesocolic (39-53%) - Left (Fossa de Landzert) (75%) - Right (Fossa de Waldeyer) (25%) Pericecal (6-13%) Intersigmoid (6%)	Transmesenteric - Small bowel mesenterium (14,6%) - Colonic mesenterium (13,7%) Transomental (1-4%) Broad ligament (4-7%) Falciform ligament
Normal Opening	
Winslow's Foramen (8%)	

Discussion

IH incidence is reported between 0.2% to 0.3% of autopsies [1] being responsible for 0.6% to 9.6% of intestinal obstruction [1-9].

The hernial orifice may be a preexisting anatomic structure or a pathologic defect of the mesentery or peritoneum, either acquired or congenital [1,10-12]. Given its rarity, congenital IH classification remains under debate [13,14], but their nomenclature is determined

Index Table: Review of reported cases in literature.

Author	S/A	Clinical Symptoms/ Signs	Previous surgeries / trauma	Chronic complaints	Image findings	Pre-Op. diagn.	Hernia content	Volvulus/ Necrosis	Surgical Approach	R
2000 Fujiwara et al. [40]	F 65	Vomiting + abdominal pain	HT	-	X-ray: air- fluid levels in the gastric lesser curvature	No	Small bowel (from 50cm Treitz to 70cm from ICV)	No *Distal ileal stenosis from ovaric adhesion	Open reduction + stenosis resection + closure defect	FR
2004 Delebecq et al. [43]	M	Vomiting + abdominal pain	-	Similar complaints for 8y	CT: Small bowel trapped between stomach and pancreas	-	-	-	-	-
2004 Neto et al. [44]	M 68	Vomiting + abdominal pain + abdominal lump	No	Similar complaints for 6w	Non solid tumor near pancreatic tail	No	Small bowel	No	Open reduction + closure defect	FR
2005 Chou et al. [45]	F 17	Abdominal pain	No	Similar attack 1y earlier	Small bowel abnormally located RUQ, cephalad to transverse colon + stretched vessels	Yes	Small bowel (150m)	No	Open reduction + closure defect	FR
2006 Kandpal et al. [46]	M 26	Vomiting + abdominal pain	No	Similar complaints for 8y	Encapsulated clusters of small-bowel loops in lesser sac + caudally displaced transverse colon + engorged mesenteric vessels	Yes	Small bowel	-	-	-
2007 Tauro et al. [47]	F 19	Vomiting + abdominal pain	No	No	Dilated ileum with signs of strangulation	No	Ileum + caecum	Necrosis	Open resection + closure defect	FR
2007 Tauro et al. [47]	M 25	Vomiting + abdominal pain	No	Similar complaints	X-ray: air fluid levels US: Dilated small bowel + minimal ascites	No	Small bowel	No	Open reduction + closure defect	FR
2008 Liu et al. [48]	F 48	Vomiting + abdominal pain + constipation	No	-	Distended fluid-filled proximal jejunum in lesser sac + displaced stomach and transverse colon + displaced and twisted mesenteric vessels	No	Small bowel (80cm jejunum)	Volvulus	Open reduction + resection + closure defect	FR
2012 Hashimoto et al. [49]	F 19	Vomiting + abdominal pain	No	-	Closed loops of obstructed small bowel, suggesting an internal hernia + increased wall thickness + increase in mesenteric density	No	Small bowel (40cm ileum)	No	Open reduction + closure defect	FR
2012 Nakamura et al. [50]	M 72	Vomiting + abdominal pain	No	-	Dilatated small bowel + enhanced wall	No	Small bowel	No *Severe stenosis	Lap → Open Resection + closure defect	FR
2012 Paraschiva et al. [51]	F 44	No symptoms "Mesenteric tumor" discovered during staging for breast cancer	No	-	Clustered small bowel loops + mesenteric vessel abnormality	Yes	Small bowel	No *Mesenteric cyst	Open reduction + enterectomy + closure defect	FR
2013 Edwards and Al-Tayar [52]	M 32	Nausea + abdominal pain	-	Similar attack	Encapsulated dilated small bowel in RUQ + pneumatosis intestinalis	No	Small bowel (100cm)	No	Open reduction + closure defect	FR
2014 Alaker and Mathias [33]	F 55	vomiting + abdominal pain + constipation	No	No	Whirlpool sign	No	Terminal ileum + ascending colon + proximal transverse colon	Volvulus No necrosis	Open reduction + closure defect	FR
2014 Kundaragi et al. [53]	M 55	Vomiting + abdominal pain + distention	No	-	Non-clustered, Non-encapsulated dilated small bowel loops ventral to transverse colon + large stretched stomach	Yes	Small bowel	No	Open reduction + closure defect	FR
2015 Haramura et al. [54]	F 83	Abdominal pain	No	-	Left obturator hernia	No	Small bowel	No	Laparoscopic reduction	-
2015 Subasinghe et al. [55]	F 48	Vomiting + abdominal pain	Cesarian	-	X-ray: air fluid levels	No	Small bowel	No	Open reduction + closure defect	FR
2015 Kalayci et al. [56]	F 20	Vomiting + abdominal pain	No	No	Dilated jejunum + increased wall thickness	No	Small bowel (all except last 40cm)	No	Open reduction + closure defect	FR
2015 Kishiki et al. [57]	M 61	Abdominal pain	No	Similar complaints	Clustered encapsulated dilated small bowel loops	No	Small bowel	No	Lap reduction + closure defect	FR
2017 Chatterjee et al. [58]	F 40	Vomiting + abdominal pain + constipation + abdominal lump	No	Similar complaints for 2y	Cluster of small bowel obstruction above transverse colon + downwards transverse colon + stretched mesenteric vessels	No	Small bowel	No	Open reduction + closure defect	FR
2019 Aparício et al. [59]	F 92	Abdominal pain + distention	No	-	Sigmoid volvulus + transmesocolic defect	Yes	Sigmoid	Volvulus + necrosis	Open Hartmann	FR

2019 Danial et al. [60]	F 25	Nausea + abdominal pain + distension + constipation	No	Similar complaints for 2y	X-ray: air- fluid levels within transverse colon US: intraabdominal fluid	No	Small bowel	Malrotation No	Lap → Open Ladd's procedure + reduction + closure defect	FR
2020 Beh et al. [61]	F 93	Bowel obstruction	-	Recurrent sigmoid volvulus	Sigmoid volvulus + transmesocolic defect *Previous 1year CT scan retrospectively reviewed with transmesocolic defect	Yes	Sigmoid	Necrosis	Open Hartmann	FR
2020 Montovano et al. [39]	M 65	Vomiting + abdominal pain + distention	Lap appendect. + cholecyst.	-	Dilated jejunum with air-fluid levels in RUQ + inferiorly displaced transverse colon + displaced mesenteric vessels	No	Small bowel	No	Lap → Open reduction + closure defect	FR
2020 Montovano et al. [39]	M 57	Vomiting + abdominal pain + constipation	Lap inguinal hernia repair	-	Dilated small bowel + inferiorly stretched transverse colon	No	Small bowel	No	Lap → Open reduction + closure defect	FR
2020 Kulkarni et al. [62]	F 54	Bowel obstruction	HT + RT	Similar complaints for 2m	Displaced stomach and transverse colon	No	Small bowel	No	Lap reduction + closure defect	FR
Present case	F 77	Bowel obstruction	Cholecyst.	No	Dilated small bowell clustered upward + right displacement of SMA + inferior displacement of transverse colon	No	Small bowel	No	Open reduction + closure defect	FR

by the location of its orifice (Table1) [15-20].

Transmesenteric hernias have become more common due to increased frequency of surgical procedures, especially those with Roux-en-Y loop construction [2,21]. Indeed, acquired transmesenteric hernias are expected in 5% of patients undergoing gastric bypass for morbid obesity, with greater incidence with retrocolic roux limb and unclosed defects [22,23]. In some case series, acquired postsurgical transmesenteric hernia represent up to 57% to 80% of all IH [19,24].

Contrarily, the incidence of congenital transmesenteric defects remains unchanged, around 10% to 15% of reported IH [19,25]. Most series present transmesenteric hernias without specifying their location (small bowel *vs.* mesocolon) [25] limiting the access to transmesocolic hernia real incidence.

The etiology of congenital transmesocolic hernia remains unclear. In 1919 Pringle suggested that the area of transverse mesocolon to the left of the middle colic vessels would be similar to Treves's avascular 'field' [26,27]. If not the result of developmental thinning/reabsorption of an avascular area during rapid mesenteric lengthening, congenital anomalies like partial regression of the dorsal mesentery might explain the defect [1,27-30]. The increased association of transmesenteric herniation with small bowel atresia further supports the concept of vascular anomalies [10,17].

The herniation process itself might be explained by a pulsion theory (abdominal compression during Valsalva maneuver) or a traction/negative pressure theory, the latter caused by the presence of peptic ulcer [15,26] and an aspiration pump-like action of the diaphragm during respiratory movements [27,31]. The correlation with peptic ulcer disease is not mentioned in reports published after the proton pump inhibitors era, and was not evident in any case of the present review. The propulsive effect of peristalsis eventually forces more loops through the mesenteric defect and the distention of the protruded loops incarcerates the bowel [1].

Loebl first reported transmesocolic hernias in 1844, and until 1949 there were no more than 71 cases in the literature [18,27], the majority located in the transverse mesocolon [26]. From 2000 until 2020 we found 26 cases of congenital transverse transmesocolic hernia in adult population index table. Twenty-four cases in Japanese literature (from 1988 until 2012) were excluded due to linguistic barriers.

Amongst 26 cases, 74% denied previous trauma or abdominal surgery and 26% referred surgeries unrelated to the mesocolon defect.

Although other congenital IH occur more frequently in men (3:2) [3,15,20], transmesocolic hernias have a female preponderance (2.25:1) [18,20,27,31]. In concordance with previous literature, we found a female preponderance with 16 female (62%) and 10 male (38%) cases.

Congenital IH can occur at all ages although with a preference between 4th and 5th decades [20,27,31]. Some authors report that retroperitoneal IH are more frequently encountered in adults, whereas transmesenteric are more common in the pediatric age [12]. Regarding that we excluded pediatric cases, we found an age average of 49 (ranging from 18 to 93), with 65% in their forties or older.

In 88% of the cases the hernia defect was on the left of the middle colic artery and the hernial content was exclusively small bowel in 84%, usually in almost all its extension. In 8% only sigmoid colon was incarcerated and in 8% the distal small bowel and ascending colon had herniated together.

IH may have a wide range of manifestations from asymptomatic to constant vague epigastric pain, intermittent colicky pain to acute abdomen [10]. The pain is frequently postprandial, worsened by large meals, and it can subside spontaneously as a result of intermittent herniation [17,21,24,32].

Abdominal pain was present in 96% of the cases of the present review, associated with nausea and vomiting in 85%. In two patients there was evidence of an abdominal lump. One patient was asymptomatic and the diagnose was made during breast cancer staging.

In 42% there was a history of recurrent complaints of intermittent crampy abdominal pain of occlusive character dating back months or years.

Symptom severity is related to the presence of hernia complication like incarceration, strangulation or volvulus [10,31]. The lack of hernial sac in transmesenteric hernias makes them more prone to have protrusion of considerable lengths of bowel and consequently higher rates of reported volvulus (up to 50%) and ischemia (40%) [1,2,10,21,24,33,34]. In this report volvulus and necrosis incidence was only 12% and 15% respectively.

In patients with symptoms of bowel occlusion, CT should be the first imaging modality. The variable location and lack of encapsulation of hernia content within a limiting hernia sac makes the diagnosis of transmesenteric hernia more difficult, with an average CT accuracy of 77%, sensitivity of 63% and specificity of 76% [21]. Previous studies have identified the following predictor signs of transmesenteric hernia on CT [3,21,35,36]**:** i) cluster with or without dilatation of small bowel in abnormal position; ii) crowding, stretching, displacement and engorgement of mesenteric vessels; iii) right or left displacement of the main mesenteric trunk lateral to the inferior vena cava or to the aorta respectively; iv) displacement of adjacent structures by mass effect (caudal/dorsal displacement of the transverse colon).

Abnormal bowel-wall enhancement or thickening and mesenteric vessel engorgement or fluid are signs of ischemia [3] and the presence of the whirl sign is highly specific for volvulus [21,24].

The scarcity of this pathology associated with the intermittent and nonspecific character of its clinical symptoms may render the diagnosis extremely difficult with the majority made at surgery or autopsy [20,21,24,25,30].

Even in the presence of suspicious or highly characteristic CT scan images in 77%, in only 23% was the diagnosis made preoperatively.

IH approach should always be surgical, with conservative treatment resulting in 100% mortality [25]. Surgery is most of the times diagnostic and therapeutic. Laparoscopy is an optional though conversion due to limited work space in the presence of dilated bowel is a reality [37-40]. We report a 57% conversion rate out of the 27% patients operated with minimal invasive surgery.

The viability of the bowel defines the strategy and the outcome. In the presence of viable bowel, reduction and closure of the defect is usually straightforward with care to preserve vessels in the edge of the defect. If the bowel is ischemic, resection with or without primary anastomosis is necessary [27,30,41].

In this review there are 7 reported enterectomies, 4 as result of bowel ischemia (2 as a volvulus consequence). The remaining resections were explained by the presence of stenosis (2 patients) and a mesenteric cyst.

A recent series mortality was exclusively the result of sepsis predominantly with *Pseudomonas aeruginosa* isolates and therefore the authors recommend the use of broad-spectrum antibiotics including anti-pseudomonas regimen [2]**.**

The mortality rate in cases with viable bowel reduction has varied from 0.3 to 6 percent [30] but when strangulation is present, mortality ranges from 30% to 70% in earlier reports [30,42] to 4% to 10% in recent series [1,17,24].

Age (>50), longer time to operation (>3 days), massive necrosis (>1 meter) and postoperative ARDS are statistically significant mortality risk factors. Given its frequent presentation with volvulus and ischemia, transmesenteric hernia has higher mortality rates than other congenital IH [32].

Despite 50% of patients being older than 50 years, the mortality rate was 0%, even in the presence of ischemia and resection. There was no information available on morbidity namely post-operative ileus or nutritional deficiencies/weight loss after bowel resection.

Conclusion

Transverse transmesocolic hernia is rare clinical entity with an extremely difficult pre-operative diagnosis. It should be considered in any patient with acute bowel obstruction who does not have an external hernia or a previous history of intra-abdominal surgery. CT with clusters of small-bowel loops in the lesser sac with caudally displaced transverse colon and engorged mesenteric vessels should elicit the diagnosis. The treatment is surgical and consists in hernia reduction and closure of the defect, with a good prognosis.

Authors Contribution

- Joana Vaz: Responsible for planning and conducting the review, collecting and interpreting data and drafting the manuscript.
- Ricardo Dias: Responsible for image content and radiology consultation. Reviewed the final version.
- Alda Faria and Mauro Sousa: Responsible for collecting and interpret data and review of the final version.
- Sara Fernandes and Filipa Nogueira: Responsible for critical review, important intellectual content and approval of the final version.
- João Coutinho: Responsible for the approval of the final version.

References

1. Johnson JR. Internal Hernia. Arch Surg. 1950;60(6):1171-82.
2. Fan HP, Yang AD, Chang YJ, Juan CW, Wu HP. Clinical spectrum of internal hernia: A surgical emergency. Surg Today. 2008;38(10):899-904.
3. Zaiton F, Al-Azzazy MZ, Ahmed AS, Amr WM. MDCT signs predicting internal hernia and strangulation in patients presented to emergency department with acute small bowel obstruction. Egypt J Radiol Nucl Med. 2016;47(4):1185-94.
4. Rooney JA, Carroll JP, Keeley JL. Internal hernias due to defects in the meso-appendix and mesentery of small bowel, and probable Ivemark syndrome: Report of two cases. Ann Surg. 1963;157(2)254-8.
5. Shannon R. Strangulating intestinal obstruction: A review of 115 cases. Aust N Z J Surg. 1971;38(1):21-3.
6. Moses W. Acute obstruction of small intestine: One hundred and eighteen cases. N Engl J pof Med. 1946;234:78-81.
7. Mclver M. Acute intestinal obstruction: Seventh installment part II: Diagnosis and treatment. Am J Surg. 1933;21(1):143,145-71.
8. Sufian S, Matsumoto T. Intestinal obstruction. Am J Surg. 1975;130(1):9-14.
9. JAMA. Intestinal obstruction. Physiological, pathological and clinical considerations with emphasis on therapy, including description of operative procedures. 1955.
10. Martin LC, Merkle EM, Thompson WM. Review of internal hernias-radiographic and clinical findings. AJR Am J Roentgenol. 2006;186(3).703-17.
11. Takeyama N, Gokan T, Ohgiya Y, Satoh S, Hashizume T, Hataya K, et al. CT of Internal Hernias. Educ Exhib. 2005;25(4);997-1015.
12. Meyers MA. Internal abdominal hernias. Dynamic radiology of the abdomen Springer, New York, NY. 1982.
13. Willwerth BM, Zollinger RM, Izant RJ. Congenital mesocolic (paraduodenal) hernia. Embryologic basis of repair. Am J Surg. 1974;128(3):358-61.
14. Doishita S, Takeshita T, Uchima Y, Kawasaki M, Shimono T, Yamashita A, et al. Internal hernias in the era of multidetector CT: Correlation of imaging and surgical findings. Radiographics. 2016;36:88-106.

15. Steinke CR. Internal hernia. Arch. Surg. 1932;25(5):909-25.

16. Ghahremani GG. Internal abdominal hernias. Surg Clin. North Am. 1984;64(2):393-406.

17. Shaffner LS, Pennell TC. Congenital internal hernia. Surg Clin North Am. 1971;51(6):1355-9.

18. GH Hansmann SAM. Intra-abdominal Hernia. Arch Surg. 1946;973-6.

19. Ghiassi S, Nguyen SQ, Divino CM, Byrn JC, Schlager A. Internal hernias: Clinical findings, management, and outcomes in 49 nonbariatric cases. J Gastrointest Surg. 2007;11(3):291-5.

20. Gullino D, Giordano O GE. Les hernies internes de l'abdomen. 1993;130:179-95.

21. Blachar A. Radiologist performance in the diagnosis of internal hernia by using specific CT findings with emphasis on transmesenteric hernia. Radiology. 2001;221(2):422-8.

22. Ford SAR. Diagnosis of transmesocolic internal hernia as a complication of retrocolic gastric bypass- CT imaging criteria. Br Med J. 2014;52-5.

23. Obeid A, McNeal S, Breland M, Stahl R, Clements RH, Grams J. Internal hernia after laparoscopic roux-en-Y gastric bypass. J. Gastrointest Surg. 2014;18(2):250-5.

24. Federle ABMP. Internal hernia: An increasingly common cause of small bowel obstruction. Semin. Ultrasound CT MR. 2002;23(2):174-83.

25. Mock CJ, Mock HE Jr. Strangulated internal hernia associated with trauma. AMA Arch Surg. 1958;77(6):881-6.

26. Fiddian RV. Herniation through mesenteric and mesocolic defects. Br J Surg. 1961;49:186-8.

27. Macrae RCB. Spontaneous herniation through the transverse mesocolon. Br J Surg. 1952;39(158):570.

28. Moudgil A, Pandove PK, Singh A, Pandove M, Sharda D, Sharda VK, et al. An unusual case of transverse mesocolic internal hernia with abnormality of both hands and high arched feet. Int J Surg Case Rep. 2015;6C:226-9.

29. Treves F. The Anatomy of the intestinal canal and peritoneum in man. Br Med J. 1885;470-4.

30. Newsom BD, Kukora JS. Congenital and acquired internal hernias: Unusual causes of small bowel obstruction. Am J Surg. 1986;152(3):279-85.

31. Stewart JOR. Lesser sac hernia. Br J Surg. 1962;50(221):321-6.

32. Akyildiz H, Artis T, Sozuer E, Akcan A, Kucuk C, Sensoy E, et al. Internal hernia: Complex diagnostic and therapeutic problem. Int J Surg. 2009;7(4):334-7.

33. Alaker M, Mathias J. Internal herniation through a defect in the transverse mesocolon. BMJ Case Rep. 2014;2014:bcr2013202753.

34. Lanzetta MM, Masserelli A, Addeo G, Cozzi D, Maggialetti N, Danti G, et al. Internal hernias: A difficult diagnostic challenge. Review of CT signs and clinical findings. Acta Biomed. 2009;90(5-S):20-37.

35. Alvarez LC. Abdominal internal hernias : Cadaver help us to understand them. Eur Soc Radiol. 2013;1-16.

36. Zissin R, Hertz M, Gayer G, Paran H, Osadchy A. Congenital internal hernia as a cause of small bowel obstruction: CT findings in 11 adult patients. Br J Radiol. 2005;78(933):796-802.

37. Capito C, Podevin J, Lascarrou JB, Lehur PA, Armstrong O. Large congenital transmesenteric hernia: A missed small-bowel atresia? Hernia. 2009;13(2):209-11.

38. Cao Y, Isogaki J, Kohga A, Okumura T, Yamashita K, Suzuki K, et al. Transmesenteric hernia with two mesenteric defects in an adult. J Surg Case Rep. 2018;2018(11):rjy318.

39. Montovano M, Chernock B, Merchant AM, Shapiro M, Oliver JB. The rare middle mesocolic hernia. Am Surg. 2020.

40. Fujiwara T, Ohno Y, Sasaki A, Suzaki N, Matsuo Y. Internal hernia with triple hiatus of congenital origin: Report of a case. Surg Today. 2000;30(10):954-8.

41. Cabrales-Vega R. Hernia transmesentérica. Revisión del tema a raíz de un caso exótico de infarto intestinal en un adulto. Iatreia. 2015;28(4):410-9.

42. Janin Y, Stone AM, Wise L. Mesenteric hernia. Surg Gynecol Obstet. 1980;150(5):747-54.

43. Delebecq T, Bourneville M, Guillemot F, Dugué T. Diagnostic d' une hernie interne trans-mésocolique par tomodensitométrie. J Chir. 2004;141(5):332.

44. de Castro Neto LR, Figueiredo JA, de Almeida Barbosa C, Lázaro da A. Hérnia interna transmesocólica congénita - Diagnóstico transoperatório. 2004;14(2):122-4.

45. Chou CK, Mak CW, Wu RH, Chang JM. Combined transmesocolic–transomental internal hernia. AJR. 2005;184:1532-4.

46. Kandpal H, Sharma R, Saluja S, Sahni P, Vashisht S. Combined transmesocolic and left paraduodenal hernia: Barium, CT and MRI features. Abdom Imaging. 2007;32(2):224-7.

47. Tauro LF, Vijaya G, D'Souza CRS, Ramesh HC, Shetty SR, Hegde BR, et al. Mesocolic hernia: An unusual internal hernia. Saudi J Gastroenterol. 2007;13(3):141-3.

48. Liu ZY, Wang Y, Liang CH. Lesser sac herniation through a defect in the transverse mesocolon: CT findings. Br J Radiol. 2008;81(962):e50-2.

49. Hashimoto D, Hirota M, Sakata K, Yagi Y, Baba H. Adult transmesenteric hernia: Report of two cases. Surg Today. 2012;42(5):489-492.

50. Nakamura K, Ohyama M, Yamamoto N, Shimada M, Oka H. A case of transverse mesocolon hernia kenichi. J Abdomin Emerg Med. 2012;32(6):1097-101.

51. Paraschiva P, Vagner SR, Stănilescu S, Burcoş T, Cristian D. Unusual case of transmesocolic hernia containing a mesenteric tumor. J Surg Sci. 2017;4:69-73.

52. Edwards HM, Al-Tayar H. A transmesenteric congenital internal hernia presenting in an adult. J Surg Case Rep. 2013;2013(12):rjt099.

53. Kundaragi NG, Vinayagam S, Mudali S. Stretched bowel sign in combined transmesocolic and transomental internal hernia: A case report and review of literature. Indian J Radiol Imaging. 2014;24(2):171-4.

54. Haramura T, Fujita F, Torashima Y, Sakimura C, Kuroki Y, Eguchi S. A case of transmesocolic hernia diagnosed and treated using laparoscopic surgery. J Jap College Surg. 2015;40(2):328-32.

55. Subasinghe D, Keppetiyagama CT, Samarasekera DN. Jejunal obstruction due to a variant of transmesocolic hernia: A rare presentation of an acute abdomen. BMC Surg. 2015;15:47.

56. Kalaycı O, Yazıcı A, Yandı M, Topaloğlu S. Boğulmuş doğumsal mezenterik fıtık: Olgu sunumu. Ulus Travma Acil Cerrahi Derg. 2015;21(5):410-3.

57. Kishiki T, Mor T, Hashimoto Y, Matsuoka H, Abe N, Masaki T, et al. Laparoscopic repair of internal transmesocolic hernia of transverse colon. Case Rep Surg. 2015;2015:853297.

58. Chatterjee S, Nayak SD, Mitra A. Congenital middle mesocolic hernia – An unusual cause of small bowel obstruction. Hell J Surg. 2017;89:52-4.

59. Aparício DJ, Leichsenring C, Pignatelli N, Germano A, Ferreira S, Nunes V. Transmesocolic hernia with sigmoid colon strangulation without surgical history: A series of two case reports. J Surg Case Rep. 2019;2019(3):rjz073.

60. Danial AK, Alsaman MZB, Zazo R, Mazketly M, Kitaz MN, Alobied M, et al. A unique case of congenital transmesocolic hernia with malrotation in a 25-year-old female: A case report. J Surg Case Rep. 2019;2019(10):rjz280.

61. Beh HN, Ongso YF, Koong DB. Transmesocolon internal hernia masking as simple sigmoid volvulus. J Surg Case Rep. 2020;2020(3):rjaa017.

62. Kulkarni GV, Premchandani D, Chitnis A, Katara A, Bhandarkar DS. Laparoscopic repair of a combined transmesocolic, transomental hernia. J Minim Access Surg. 2020;16(1):83-6.