



## Transvaginal Peritoneocele Repair with Anterior Levatorplasty in Patients with a Rectocele and an Enterocele

Kotaro Maeda<sup>1\*</sup>, Yoshikazu Koide<sup>2</sup>, Hidetoshi Katsuno<sup>3</sup>, Tsunekazu Hana<sup>2</sup>, Koji Masumori<sup>2</sup>, Hiroshi Matsuoka<sup>2</sup>, Tomoyoshi Endo<sup>3</sup> and Yeong Cheol Cheong<sup>2</sup>

<sup>1</sup>Department of Surgery, International Medical Center, Fujita Health University Hospital, Japan

<sup>2</sup>Department of Surgery, Fujita Health University School of Medicine, Japan

<sup>3</sup>Department of Surgery, Fujita Health University Okazaki Medical Center, Japan

### Abstract

Enterocele is defined as a herniation of the peritoneal sac between the vagina and the rectum. Its predisposing conditions include a peritoneocele or a deep peritoneal sac which induce a rectal prolapse and the enterocele. Enteroceles and rectoceles often contribute to the symptoms of vaginal mass and pelvic discomfort. The combination of a rectocele and an enterocele as pelvic organ prolapses is not infrequent. However, the literature data on possible simultaneous treatments of those two conditions is scarce. We herein report a new and simple procedure for repairing the enterocele during a transvaginal anterior levatorplasty with posterior colporrhaphy for the rectocele repair. The technique includes performing an excision of the peritoneal sac with high ligation and attaching the uterine cervix and/or cardinal ligament to the upper most part of the approximation of the levator muscles in order to reinforce and lift the deep peritoneal sac. Hence, this procedure allows for a transvaginal repair of both enterocele and rectocele. The visualization of an enterocele is facilitated by pasting the barium to the posterior vaginal wall during defecography.

**Keywords:** Rectocele; Peritoneocele repair; Enterocele repair; Anterior levatorplasty; Transvaginal approach

### OPEN ACCESS

#### \*Correspondence:

Kotaro Maeda, Department of Surgery,  
International Medical Center, Fujita  
Health University Hospital, 1-98,  
Kutsukake, Toyoake, Aichi, 470-1192,  
Japan, Tel: +81-562-93-9025; Fax:  
+81-562-93-8723;

E-mail: kmaeda@fujita-hu.ac.jp

Received Date: 01 Jul 2020

Accepted Date: 24 Jul 2020

Published Date: 29 Jul 2020

#### Citation:

Maeda K, Koide Y, Katsuno H, Hana T, Masumori K, Matsuoka H, et al. Transvaginal Peritoneocele Repair with Anterior Levatorplasty in Patients with a Rectocele and an Enterocele. *Clin Surg.* 2020; 5: 2883.

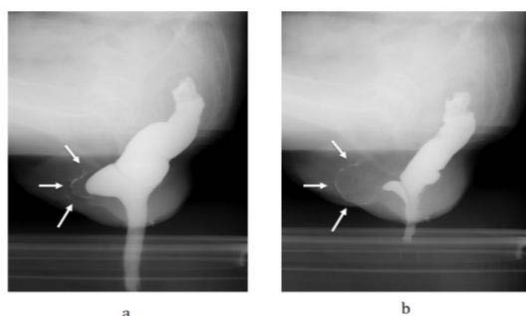
**Copyright** © 2020 Kotaro Maeda. This is an open access article distributed under the Creative Commons Attribution License, which permits unrestricted use, distribution, and reproduction in any medium, provided the original work is properly cited.

### Introduction

Enterocele is defined as a herniation of the peritoneal sac between the vagina and the rectum [1], and peritoneocele or deep peritoneal sacs are its predisposing conditions (as they may induce a rectal prolapse and the enterocele). Enteroceles are associated with pelvic discomfort, which includes the feeling of prolapse heaviness and pelvic pressure [2,3], obstructed defecation [1], and the presence of a vaginal mass. Mellgren et al. [4] analyzed the defecography outcomes of 2,816 patients with defecation disorders. Their study revealed that 23% of those patients had no detectable underlying conditions, while 31% of them suffered from rectal intussusception, 13% had a rectal prolapse, 27% had a rectocele and 19% had an enterocele. Thus, rectoceles and enteroceles are not uncommon in patients with defecation disorders. By utilizing the dynamic pelvic three-dimensional computed tomography, Okamoto et al. [5] demonstrated that 4 of 8 patients with a rectocele also had an enterocele. Thus, a combination of pelvic organ prolapses - the rectocele and the enterocele, is rather common. Medical interventions for the enterocele include an abdominal obliteration of the pelvic inlet [1], a transvaginal approach [6], an abdominal vaginal suspension technique [7] and a combined rectovaginopexy [8], amongst others. However, approaches aiming at a simultaneous repair of the combined rectocele and enterocele have not been well-documented [9]. We herein report a novel and uncomplicated technique for repairing the enterocele during a transvaginal anterior levatorplasty with posterior colporrhaphy for the rectocele repair. During the procedure, an excision is made in the peritoneal sac with high ligation and attaching the uterine cervix and/or cardinal ligament (transverse cervical ligament) to the upper most part of the approximation of the levator muscles. This reinforces and lifts up the deep peritoneal sac. Furthermore, we describe a simple and easy technique for the visualization of enteroceles.

### Selection of Patients

Patients, who presented with symptoms of a vaginal mass and/or pelvic discomfort, including



**Figure 1:** Preoperative defecography with barium contrast of the posterior vaginal wall. a) The rectocele is well visualized during straining. b) The enterocele becomes visualized with evacuation of the rectocele due to further straining.

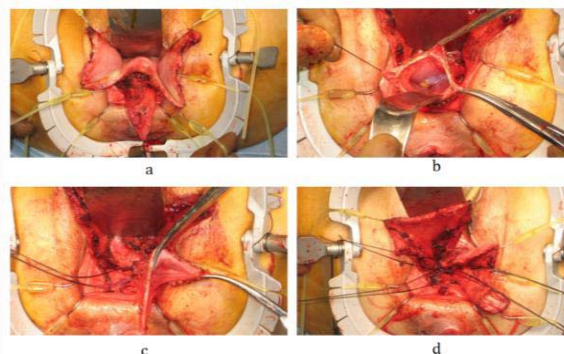
the feeling of prolapse and pelvic pressure, were subjected to defecography. Prior to the investigation, the barium powder with small amount of water was pasted to the posterior vaginal wall. This technique has been routinely used in our institute for the detection of enteroceles. In cases when the presence of an enterocele was suspected due to the observed excessive space between the rectocele and the posterior vaginal wall (Figure 1), the peritoneocele repair was considered to be performed during the transvaginal anterior levatorplasty with the posterior colporrhaphy for a rectocele.

## Surgical Procedure

Transvaginal anterior levatorplasty with posterior colporrhaphy was performed as described by Maeda et al. [10]. Following the bowel preparation by whole gut lavage, the operation was performed with the patient under general anesthesia in the lithotomy position. A transverse incision was initially made in the posterior vaginal wall just above the sphincter muscles, and a sharp and blunt dissection was made between the posterior wall of the vagina and the anterior wall of the rectum. Following, a vertical or an inverse V-shaped or U-shaped incision was added in the posterior vaginal wall above the transverse incision to facilitate a full exposure of both limbs of the puborectalis and pubococcygeal muscles on both sides of the midline, upwards and behind the level of the posterior fornix. During the dissection between the posterior wall of the vagina and the anterior wall of the rectum, the lower edge of the deep peritoneal sac was confirmed. Then, the sac was dissected posteriorly and anteriorly to expose its full length up to the retroperitoneal part of the uterine cervix (Figure 2a). Swabs were often used in order to exclude the protruding anterior rectal wall from the field. Following the opening of the peritoneal sac by pushing the intestine back to the abdominal cavity (Figure 2b), double-suture ligations were performed at the level of the retroperitoneal part of the uterine cervix (Figure 2c) accompanied by transection of the excessive peritoneal sac. After approximating both limbs of the puborectalis and pubococcygeal muscles, four to five sutures with non-absorbable one size threads were performed between the upper most part of the approximation of the levator muscles and the retroperitoneal part of the uterine cervix and/or the connective tissue of the cardinal ligament, and then securely tied to reinforce and lift up the deep peritoneal sac (Figure 2d).

## Results

Eight patients (a median age of 71 years; range: 64 to 89) underwent the above-described surgical procedure between January 2013 and September 2019. The presence of a vaginal mass was the main



**Figure 2:** Transvaginal peritoneocele repair during the anterior levatorplasty for a rectocele and an enterocele. a) Deep peritoneal sac was dissected posteriorly and anteriorly to expose its full length up to the retroperitoneal part of the uterine cervix. b) Peritoneal sac was opened, and the intestine was pushed back to the abdominal cavity. c) Double suture ligations were performed at the level of the retroperitoneal part of the uterine cervix followed by the transection of the excessive sac. d) Sutures were performed between the upper most part of the approximation of the levator muscles and the retroperitoneal part of the uterine cervix and/or the connective tissue of the cardinal ligament.

symptom in 7 patients, and pelvic discomfort including the feeling of prolapse and pelvic pressure was the complaint of the remaining patient. Enteroceles with rectoceles were diagnosed preoperatively by defecography in 7 patients, and the diagnoses were confirmed intraoperatively. A deep pelvic sac (peritoneocele) was confirmed in the 8<sup>th</sup> patient during the dissection between the posterior wall of the vagina and the anterior wall of the rectum in anterior levatorplasty for the rectocele, and no enterocele was detected during the procedure. A rectal injury occurred in one patient and was sutured during the surgery without further post-operative complications. Of note, this patient had twice undergone a vaginal surgery for the rectocele, performed by a gynecologist. The median operation duration time and bleeding volume were 93 (range 60 to 157) minutes and 92 (range 63 to 226) mL, respectively. No deaths occurred during or after the surgeries. Following the procedure, the symptoms of a vaginal mass and pelvic discomfort disappeared in all 8 patients. In one patient, the enterocele reoccurred 5 months after the first surgery at the posterior part of the uterine cervix in a form of a vaginal mass. A transvaginal enterocele repair was performed again in this patient, and no further symptoms occurred in the next 14 months. The median patient follow-up period was 27 (range 8 to 46) months.

## Discussion

The exact prevalence of an enterocele is unknown [1]. Some studies indicate that 44.5% of patients presented with dysfunction in their pelvic floor have enteroceles [7], while other sources point out that enteroceles are uncommon [1]. The frequency of a symptomatic enterocele is also undetermined. It was reported that almost two-third of women with a symptomatic enterocele had previously undergone a hysterectomy [6]. In line, two of 8 patients who participated in our study had undergone a hysterectomy. Enteroceles are associated with obstructed defecation, symptoms of pelvic discomfort [1,6] and the presence of a vaginal mass. Seven of 8 patients in our study had complaints concerning vaginal masses. All of these patients were defecographically diagnosed with an enterocele with a rectocele, and those diagnoses were confirmed intraoperatively. Only a rectocele was diagnosed preoperatively in a patient with pelvic discomfort; however a peritoneocele was discovered during the surgery and was

subsequently repaired. We believe that the peritoneocele did not contribute to the symptoms observed in this patient. Diagnosis of an enterocele is usually made during defecography and peritoneography with the use of the contrast in the intestine and presents as the descent of the intestine into the deep peritoneal sac. In 7 patients who participated in our study, the presence of an enterocele was suggested preoperatively by the results of defecography with barium pasted to the posterior vaginal wall which revealed an excessive space between the rectocele and the posterior vaginal wall. An enterocele was confirmed in these patients intraoperatively. Therefore, the approach described here could constitute a simple and straightforward diagnostic tool for enteroceles. The repair of an enterocele is considered in the presence of associated symptoms. Both the rectocele and the enterocele were considered to contribute to the presence of a vaginal mass in 7 of 8 patients in this study. The majority of enterocele repair strategies require an abdominal approach and are more invasive [1,7,8]. Reports of repairs of the combined rectocele and enterocele are rare. For instance, a combined abdominoperineal repair has been described [9], but it relied on the abdominal approach. The repair of the enterocele described here resembles an inguinal hernia repair which is achieved by high ligation of the hernia sac and the reinforcement of the hernia outlet. In our approach, the reinforcement was achieved by suturing the upper most part of the approximation of the levator muscles and the retroperitoneal part of the uterine cervix and/or the connective tissue of the cardinal ligament. The patient who experienced the enterocele recurrence recognized that the threads snapped while she was straining. Thus, the reinforcement was working until the enterocele recurrence, and the re-reinforcement has worked well after the second repair. Therefore, the procedure described here can be a feasible and minimally invasive surgical option for the treatment of an enterocele with a rectocele.

## References

1. Oom DMJ, van Dijk VRM, Gosselink MP, van Wijk JJ, Schouten ER. Enterocele repair by abdominal obliteration of the pelvic inlet: Long-term outcome on obstructed defecation and symptoms of pelvic discomfort. *Colorectal Dis.* 2007;9:845-50.
2. Gosselink MJ, van Dam JH, Huisman WM, Ginai AZ, Schouten WR. Treatment of enterocele by obliteration of the pelvic inlet. *Dis Colon Rectum.* 1999;42:940-4.
3. Jean F, Tanneau Y, Le Blanc-Louvry I, Leroi Am, Denis P, Michot F. Treatment of enterocele by abdominal coloporectosacropexy - efficacy on pelvic pressure. *Colorectal Dis.* 2002;4:321-5.
4. Mellgren A, Bremmer S, Johansson C, Dolk A, Uden R, Ahlback SO, et al. Defecography. Results of investigations in 2816 patients. *Dis Colon Rectum.* 1994;37:1133-41.
5. Okamoto N, Maeda K, Kato R, Shyoshi S, Sato H, Ryuji H. Dynamic pelvic three-dimensional computed tomography for investigation of pelvic abnormalities in patients with rectocele and rectal prolapse. *J Gastroenterol.* 2006;41:802-6.
6. van der Plas-de Konig YW, Vierhout ME. Low rate of recurrence at a follow-up study of vaginal repair of enterocele. *Ned Tijdschr Geneesk.* 2001;145:366-70 [Article in Dutch].
7. Cronje HS, De Beer JA, Bam R. The pathophysiology of an enterocele and its management. *J Obstet Gynaecol.* 2004;24:408-13.
8. Silvis R, Gooszen HG, Kahraman T, Groenendijk AG, Lock MT, Italiander MV, et al. Novel approach to combined defaecation and micturition disorders with rectovaginoscopy. *Br J Surg.* 1998;85:813-7.
9. Pescatori M, Pulvirenti d'Urso A, Tagarello G. Combined abdominoperineal repair of enterocele and rectocele. *Tech Coloproctol.* 2001;5:124.
10. Maeda K, Maruta M, Hanai T, Sato H, Masumori K, Koide Y, et al. Transvaginal anterior levatorplasty with posterior colporrhaphy for symptomatic rectocele. *Tech Coloproctol.* 2003;7:181-5.