Clinics in Surgery

Clinical Video
Published: 08 Oct, 2021

Torcular Dural Arteriovenous Fistula (DAVF) Completely Obliterated by Surgical Clipping: Operational Video

Papadakos D, Zampakis P, Theofanopoulos A, Constantoyannis C and Panagiotopoulos V*

Departments of Neurosurgery and Endovascular Neurosurgery/Interventional Neurology, University Hospital of Patras, Greece

Keywords

Dural arteriovenous fistula; Torcular DAVF; Supracerebellar approach; Suboccipital mini craniectomy

Abbreviations

CT: Computed Tomography; CTA: Computed Tomographic Angiography; DAVF: Dural Arteriovenous Fistula

Background

Intracranial Dural Arteriovenous Fistulae (DAVF) account for about 10% to 15% of all intracranial arteriovenous lesions [1]. DAVFs of the posterior fossa can present with either acute hemorrhage, pulsatile tinnitus or symptoms depending on their drainage pattern including intracranial hypertension, cerebral edema, and hydrocephalus and cranial nerve palsies [2].

Case Description

We present a case of a 58-year-old male who presented to our department with sudden-onset severe headache and nuchal rigidity. There was no altered level of consciousness. CT scan revealed intraparenchymal hemorrhage into the left cerebellar lobe; CTA identified the source as a ruptured torcular DAVF. Digital subtraction angiography further defined the DAVF as type IV according to Cognard classification, supplied by transosseous branches of the left occipital artery and draining retrogradely into the inferior vermian vein. Emergency endovascular embolization was attempted; however sufficient occlusion was not achieved. The patient therefore underwent

Figure 1:

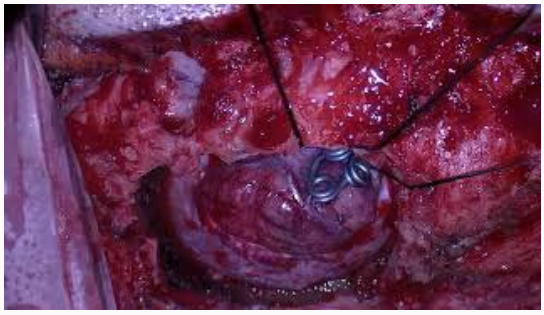

Figure 2:

OPEN ACCESS

Correspondence:
Vasileios Panagiotopoulos, Main Surgeon, Department of Neurosurgery, University Hospital of Patras, 26504 Patra, Greece, Tel: +302610999752; E-mail: baspan@upatras.gr

Received Date: *30 Aug 2021*
Accepted Date*: 05 Oct 2021*
Published Date*: 08 Oct 2021*

Citation:
Papadakos D, Zampakis P, Theofanopoulos A, Constantoyannis C, Panagiotopoulos V. Torcular Dural Arteriovenous Fistula (DAVF) Completely Obliterated by Surgical Clipping: Operational Video. Clin Surg. 2021; 6: 3326.

Copyright *© 2021 Panagiotopoulos V. This is an open access article distributed under the Creative Commons Attribution License, which permits unrestricted use, distribution, and reproduction in any medium, provided the original work is properly cited.*

a left lateral suboccipital mini craniectomy in the prone position, whereupon successful clip ligation of the DAVF was achieved through the supracerebellar route. The patient's postoperative course was uneventful without complications or any neurological deficit. Postoperative angiography revealed complete obliteration of the DAVF without residual arteriovenous shunting.

Conclusion

Torcular DAVFs are rare lesions located at the midline of the posterior margin of the falcotentorial junction. Surgical disconnection of the draining vein at its origin is feasible through suboccipital mini craniectomy providing complete occlusion of the dural arteriovenous fistula.

Video Link - https://youtu.be/ohHedRm46gg

References

1. Newton TH, Cronqvist S. Involvement of dural arteries in intracranial arteriovenous malformations. Radiology. 1969;93(5):1071-8.
2. Sundt TM Jr, Piepgras DG. The surgical approach to arteriovenous malformations of the lateral and sigmoid dural sinuses. J Neurosurg. 1983;59(1):32-9.