



## The Free Radial Forearm Flap versus the Pedicled Pectoralis major Myocutaneous Flap for Quality Reconstruction of Oesophageal and Hypopharyngeal Defects and Literature Review

Athanasios Karonidis<sup>1\*</sup>, Dimosthenis Tsoutsos<sup>1</sup>, Sotiris Papouliakos<sup>2</sup>, Evangelia Zaharioudaki<sup>2</sup>, Athanasia Marinou<sup>2</sup> and Zisis Pappas<sup>2</sup>

<sup>1</sup>Department of Plastic Surgery, General Hospital of Athens G Gennimatas, Greece

<sup>2</sup>Department of Otorhinolaryngology, General Hospital of Athens G Gennimatas, Greece

### Abstract

**Background:** The aim of this study is to assess the efficacy of free radial forearm flap and pectoralis major flap for the reconstruction of hypopharyngo-oesophageal defects, highlighting the technical feasibility, complications, functional outcome and literature review.

**Methods:** From 2012 to 2016, twelve patients with laryngeal carcinoma underwent laryngectomy, hypopharyngeal esophagectomy, and reconstruction of pharyngo-oesophageal defects with free radial forearm flap in eight cases and pedicled pectoralis major myocutaneous flap in four cases. Ten patients had partial defect, and two patients had total circumferential defect. The flap selection was based on the general condition of the patient. The patients with better general condition underwent microvascular free RFF reconstruction in contrast to debilitating patients who had PM reconstruction.

**Results:** All flaps survived. The successful outcome was confirmed by swallowing test with gastrographin, and associated with oral alimentation, good uncomplicated swallowing and improved quality of life. Two patients with radial forearm flap microvascular reconstruction developed fistula formation and done stricture. Two patients with pectoralis major reconstruction developed fistula formation and stricture. Two patients died due to tumour recurrence. Oral alimentation was achieved in eleven patients. The patients who underwent radial forearm flap microvascular reconstruction reported better quality of life in terms of swallowing and cosmetic appearance comparing to pectoralis major reconstruction, whereas there were equal results in terms of speech.

**Conclusion:** The radial forearm flap and the pectoralis major flap safeguard a feasible reconstruction of hypopharyngo-oesophageal neo-tube and provide satisfactory and consistent functional results. However the free radial forearm flap offers better quality reconstruction and is considered a superior reconstructive option for the patients who can tolerate major surgery.

**Keywords:** Radial forearm flap; Pectoralis major flap; Pharyngoesophageal defects; Cervical oesophagectomy, Laryngeal cancer, Microsurgery

### Introduction

Regional pedicled flaps and free flaps have been employed to reconstruct pharyngoesophageal defects following major cancer resection. Among the flaps most commonly used are the 'skin' flaps such as the pedicled Pectoralis Major (PM) musculocutaneous flap and the free Radial Forearm Flap (RFF). The choice of the best reconstructive option is still controversial. The aim of this study is to assess the efficacy of RFF and PM flap for the reconstruction of hypopharyngo-oesophageal defects, highlighting the technical feasibility, complications, functional outcome and literature review.

### Patients and Methods

From 2012 to 2016, twelve patients (eleven males, one female) aged 66 years in average with laryngeal carcinoma, underwent laryngectomy, esophagectomy, hypo pharyngectomy, and neck dissection. The oesophageal and hypopharyngeal defects were reconstructed with free RFF in eight

### OPEN ACCESS

#### \*Correspondence:

Athanasios Karonidis, Department of Plastic Surgery, Microsurgery and Burns Unit, General Hospital of Athens G Gennimatas, Sifnou 33 Agia Paraskevi 15343, Athens, Greece, Tel: 00306936798945; Fax: 00302107709851;

E-mail: thanasiskaronidis@hotmail.com

Received Date: 29 May 2017

Accepted Date: 04 Jul 2017

Published Date: 11 Jul 2017

#### Citation:

Karonidis A, Tsoutsos D, Papouliakos S, Zaharioudaki E, Marinou A, Pappas Z. The Free Radial Forearm Flap versus the Pedicled Pectoralis major Myocutaneous Flap for Quality Reconstruction of Oesophageal and Hypopharyngeal Defects and Literature Review. *Clin Surg*. 2017; 2: 1553.

**Copyright** © 2017 Karonidis A. This is an open access article distributed under the Creative Commons Attribution License, which permits unrestricted use, distribution, and reproduction in any medium, provided the original work is properly cited.

**Table 1:** Demographics and descriptive.

N	Age (y)	Sex	Stage	PreopRx	Recon	Defect	NGT	Gastrostomy
1	52	Male	III	No	RFF	P	Yes	No
2	62	Male	II	Yes	RFF	C	Yes	Yes
3	59	Male	II	No	RFF	P	Yes	No
4	80	Male	III	Yes	RFF	P	Yes	No
5	82	Male	III	Yes	RFF	P	Yes	No
6	57	Female	III	Yes	RFF	P	Yes	Yes
7	70	Male	III	No	RFF	P	Yes	No
8	67	Male	III	Yes	RFF	C	Yes	No
9	55	Male	II	Yes	PM	P	Yes	No
10	67	Male	III	Yes	PM	P	Yes	No
11	57	Male	II	Yes	PM	P	Yes	Yes
12	60	Male	II	Yes	PM	P	Yes	Yes
<b>Total: 12</b>	Average: 64 y	Males: 11 Females: 1			RFF: 8 PM: 4	P: 10 C: 2	100%	

y: years; Preop Rx: Preoperative radiotherapy; Recon: Reconstruction; NGT: Nasogastric tube; P: Partial; C: Circumferential

**Table 2:** Flap comparison.

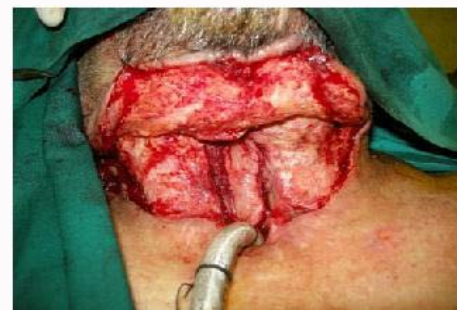Flap	Dissection	Skin paddle	Thinness/ inset	Bulk	Swallowing	Voice	Morbidity	Cosmesis	ICU bed
RFF	+	+	+	+	+	+	-	+	-
ALT	-	+	-	+/-	+	+	+	+	-
PM	+	+/-	-	-	+/-	+/-	-	-	+
Jejunum	-	-	+	+	+	-	-	+	-

(+): advantage; (-): disadvantage

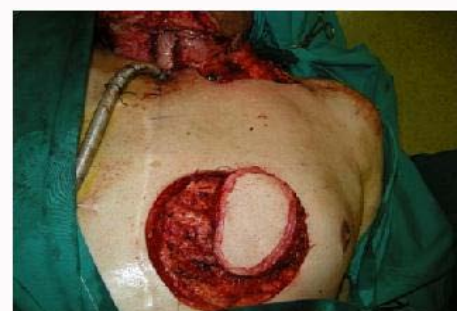patients and with pedicled PM flap in four patients (Table 1). In nine cases the resection and the reconstruction were performed at the same operating time, whereas in three cases the reconstruction was performed a few weeks after the resection. Nine patients had preoperative radiotherapy. Ten patients had partial defect ranging from 50% to 80% of the circumference (Figures 1a and 2a), which were reconstructed with free RFF in six cases and with PM flap in four cases. Two patients had total circumferential defects and were reconstructed with free RFF (Figure 3a). In cases where the resection and reconstruction were performed at the same operating time, the average operating time was 13 h for the RFF reconstruction, whereas for PM reconstruction was 9 h. The patients who underwent microvascular RFF reconstruction were admitted postoperatively in the ICU for the first two or three days and then they were transferred to the ward. We performed gastrostomy only in four patients at the same operating time, whereas all the other patients were fed via nasogastric tube. Maximum follow-up was 30 months.

### Flap dissection and neo-tube reconstruction

The musculocutaneous PM flap is a type V Mathes-Nahai classification flap, based on the pectoral branch of thoracoacromial artery and venae comitantes as the dominant pedicle [1]. The PM flap is used for partial hupo pharyngoesophageal defects. The skin island is used for the 'lining' and a 6 - 8 × 10 cm skin 'patch' is usually sufficient. The muscle can provide wound cover and a bed for skin grafting (Figures 1a-1e). The RFF is a fasciocutaneous type B Mathes-Nahai flap based on the radial artery and venae comitantes and cephalic vein as the dominant pedicle [1]. The flap design should be tailored to the size of the defect. For partial defects a 'patch' 6 - 8 × 10 cm of skin island is usually sufficient (Figures 2a,b). For circumferential defects

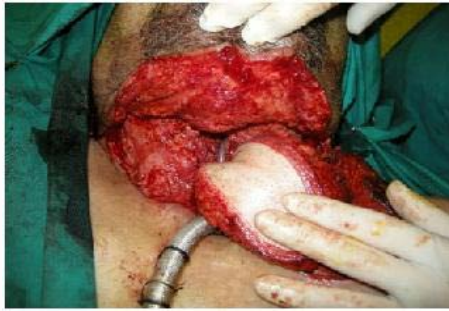

**Figure 1a:** Partial oesophageal defect where the anterior wall has been resected and the posterior wall was present.

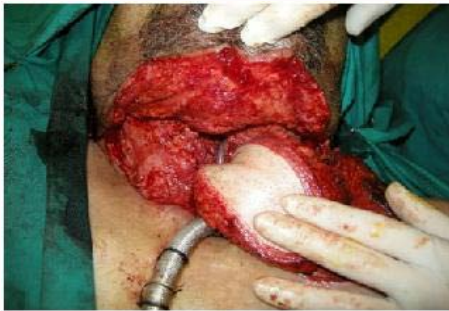

**Figure 1b:** The dissection of PM flap has been completed.

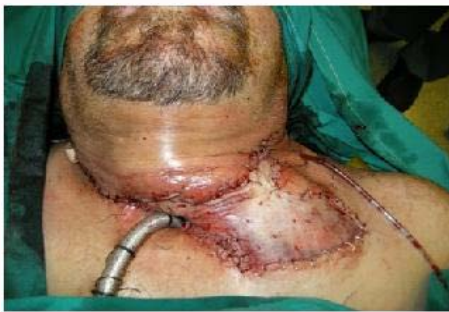a larger flap up to 10×12 cm may be required, if the defect involves the hypopharynx from the tongue base and the cervical oesophagus (Figures 3a, 3b). A suprafascial dissection from distal to proximal



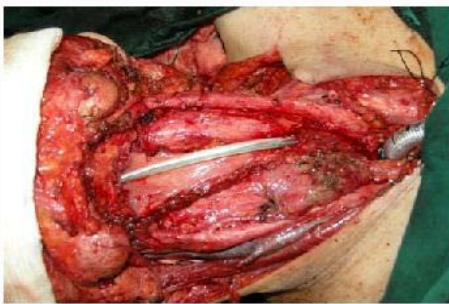**Figure 1c:** The PM flap has been inset partially at the oesophageal defect.



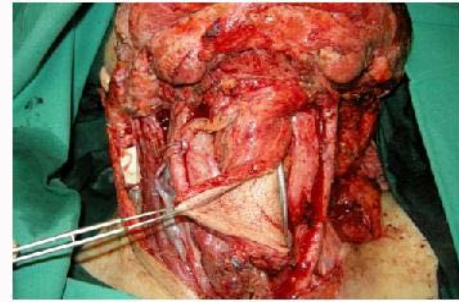**Figure 1d:** The inset of PM flap has been inset completed.



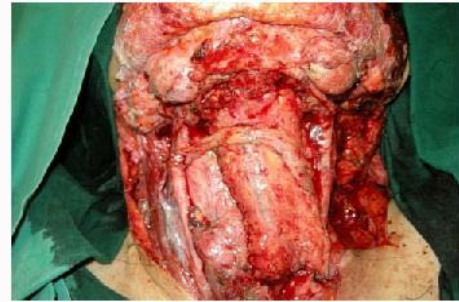**Figure 1e:** A skin graft was placed over the PM muscle.



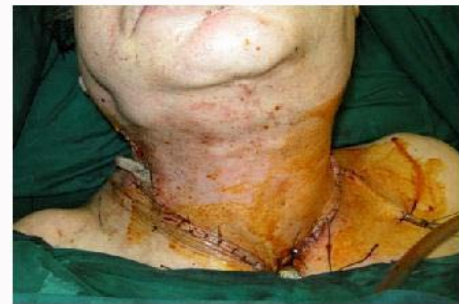**Figure 2a:** Partial hypo pharyngo-oesophageal defect where the anterior and lateral walls have been resected and the posterior wall was present. The nasogastric tube has been placed.



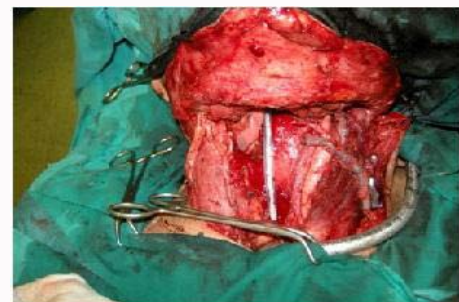
**Figure 2b:** The radial forearm flap has been sutured with the oesophageal stump inferiorly and oropharynx superiorly, whereas the flap pedicle was anastomosed with the superior thyroid vessels.



**Figure 2c:** The flap inset was completed and the neo-tube was created.



**Figure 2d:** The neck skin flap was closed primarily.

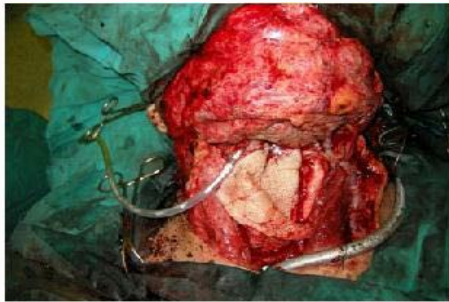


**Figure 3a:** Circumferential hypopharyngo-oesophageal defect. Note the hypopharyngeal stump superiorly and oesophageal stump inferiorly.

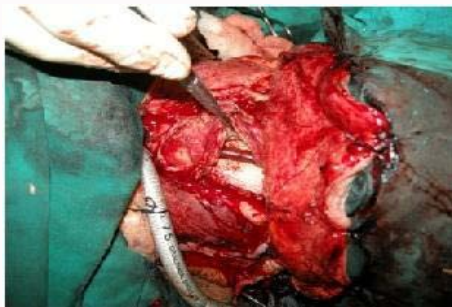is performed. During inset, the flap is sutured to the oesophageal stump inferiorly, preferably before vascular anastomosis (Figures 2b, 3b and 3c). The flap edges are de-epithelialized for 0.5 cm - 1.0 cm and sutured double layered to 'seal' the tract, aiming to prevent the fistula formation [2,3] (Figures 2b and 3c). A nasogastric tube is passed through the neo-tube for decompression, stenting and feeding (Figures 2a, 2b and 3c). After the completion of vascular anastomosis

in partial defect, the skin island flap is sutured to the remaining posterior wall. In circumferential defect the vertical line is sutured. Then the flap is anastomosed to hypopharyngeal stumps superiorly (Figures 2c and 3d). In cases of total circumferential defects the lateral edges of the flap/neo-tube are sutured to the raw prevertebral fascia to enhance the immobility of the neo-tube and reduce potential complications (Figure 3d). The neck skin flaps are sutured and closed

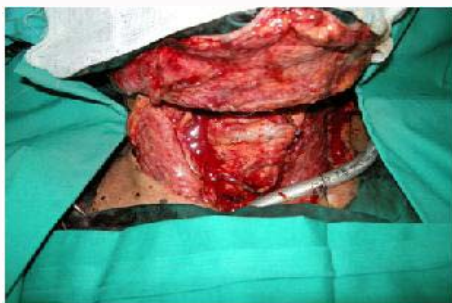



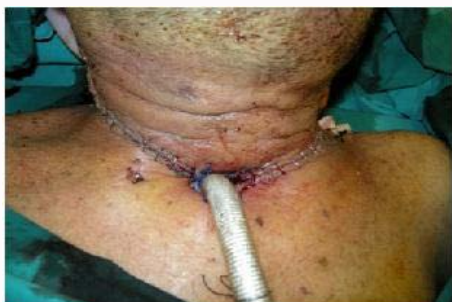**Figure 3b:** A large skin island was required to reconstruct the neo-tube. The radial forearm flap has been sutured with the oesophageal stump inferiorly.



**Figure 3c:** The flap edges were de-epithelialized and sutured double layered.



**Figure 3d:** The reconstruction of the circumferential defect was completed and the neo-tube was created.

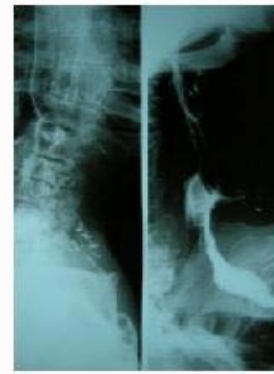

**Figure 3e:** The neck skin flap was closed primarily.

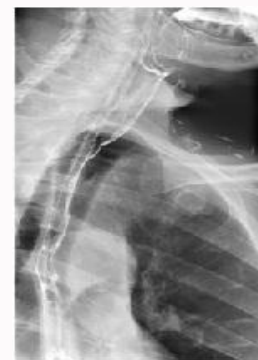primarily, reconstructing the tracheostoma (Figures 2d and 3e).

## Results

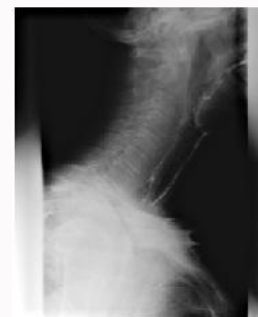All flaps survived. The integrity and continuity of the alimentary tract was confirmed by swallowing test with gastrografin (Figure 4a-4c). The successful outcome was associated with oral alimentation, good uncomplicated swallowing and improved quality of life. Two patients with RFF reconstruction had flap anastomotic dehiscence



**Figure 4a:** The reconstruction of a partial defect and continuity of the alimentary tract was confirmed by swallowing test with gastrografin.



**Figure 4b:** The continuity of the alimentary tract in reconstruction of a circumferential defect was confirmed.



**Figure 4c:** The neo-tube was clearly defined.

and fistula formation. The first was treated conservatively, fed via gastrostomy and finally healed. The second patient who had undergone reconstruction of a circumferential defect was re-explored (Figure 5a) and the flap anastomosis was re-sutured primarily (Figure 5b), whereas he was fed via nasogastric tube for almost four weeks. Stricture was reported in one case and confirmed via endoscopy. A pouch formation at the distal anastomosis was documented in two cases, as there was a diameter discrepancy between the neotube (higher diameter) and the oesophageal stump. Two patients with PM reconstruction complicated with fistula formation and stricture. The first was treated conservatively, fed via gastrostomy and finally healed. The second patient was re-explored and the flap was re-sutured primarily. Two patients died in five and thirteen months. The first died due to tumour recurrence and the second due to lung metastasis respectively. Oral alimentation was achieved in eleven patients. One patient, who underwent PM reconstruction and had radiotherapy

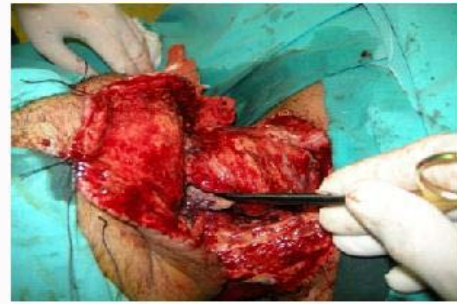preoperatively, was unable to achieve oral diet due to severe stenosis. Patients reported episodes of swallowing dysfunction occasionally, with food sticking at the pouch or the area of distal anastomosis and attacks of hawking, where a degree of stenosis might be developed but not documented in radiographs. All patients were advised to have frequent small meals.

However the patients with RFF microvascular reconstruction reported better quality of life in terms of swallowing and cosmetic appearance comparing to those with PM reconstruction. In cases with PM reconstruction skin grafting was applied over the PM muscle, which might had an adverse effect to the neck motility due to additional scarring and downgraded the cosmetic result. However there were equal results in terms of speech for both types of reconstructions. All the patients were satisfied with the outcome as their quality of life was improved dramatically. All these cases were discussed at the oncologic meeting for further adjuvant treatment.

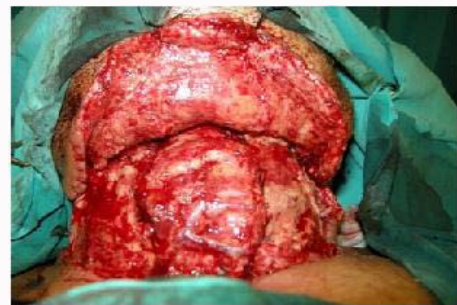## Discussion

The reconstruction of pharyngoesophageal defects is a common sequela following major cancer resection in the cervical region. The aims and priorities of reconstruction include: the wound closure, in terms of restoration of continuity of the alimentary tract and skin wound cover, the function such as swallowing and speech issues, cosmesis, and the overall morbidity. The ideal flaps for head and neck reconstruction should fulfill the following criteria: versatility in design, adequate tissue volume, superior texture, availability of diverse tissue types on one pedicle, potential for re-innervation, large and long pedicle with consistent anatomy, easy and safe flap dissection, feasibility of a 2 team approach, no need for position change, and negligible donor site morbidity [4]. Microsurgery has offered superior reconstructive options and has superseded the regional flaps. The latter are considered as salvage procedure or for patients with a poor state who cannot tolerate major surgery [5]. There is no uniform agreement for the optimal reconstructive method. It should satisfy as many of the following attributes as possible: adequate surgical margins, especially the inferior margin; single stage procedure; low donor site morbidity; high rate of successful tissue transfer; low rate of stenosis or fistula formation; simultaneous transfer to reduce operating time; and surgeons who are experienced with the procedure and handling complications [6]. If all options are available then the flap which best satisfies the reconstructive aims should be the primary choice. Other considerations such as the surgeon's preference, tumour location and size, general condition of the patient, technical feasibility, speech issues, minimum associated morbidity, and patient's preference must be taken into account and guide the decision making. The advantages of fasciocutaneous flaps include the large amount of extra skin paddle with prolonged ischaemia time, safety, without the violation of the abdominal cavity [7]. The radial forearm flap and the ALT flap fulfill most of the aforementioned criteria.

The advantages of the PM flap include the standard anatomy, ease dissection, single stage procedure, low perioperative mortality, high success flap rate, and no need for microsurgical training [8]. The disadvantages are related to the geometry of the flap, making it a suboptimal reconstructive choice. The bulkiness of the flap does not match with the thin and pliable tissue of the hypopharyngeal and oesophageal wall. The large volume and downward traction of the flap may impair the mobility of the tongue, causing problems in swallowing and speech articulation, and the quality of voice rehabilitation is generally poor. This also associated with higher rate



**Figure 5a:** Dehiscence of the proximal anastomosis and fistula formation at a patient who underwent RFF reconstruction for a circumferential defect.



**Figure 5b:** The proximal anastomosis was re-sutured primarily.

of partial flap necrosis, wound dehiscence, pharyngocutaneous fistula formation (average 27%), distal stenosis and stricture (average 17%) comparing to other flaps [2]. The PM musculocutaneous flap is used as a salvage procedure in debilitating patients, for the reconstruction of partial circumferential pharyngoesophageal defects, when a free flap reconstruction is contraindicated [2].

The RFF has many advantages. In surgical practice flap necrosis is rare and therefore it is considered a safe and reliable procedure that provides very well vascularized tissue and rapid healing potential. Although microsurgical training is required, the standard flap anatomy with long and large pedicle aids the speedy dissection. This thin and pliable 'skin' flap is ideal for tubed-shaped reconstruction, or 'patch' cover for partial circumferential defects, a technical consideration that is important for the flap inset. Although the ALT can be thinned, in our experience the RFF is more pliable and flexible and can be better adjusted to proximal and distal stumps. Functional swallowing with free RFF of 90% has been described with prolonged nasopharyngeal transit time [2,9]. The RFF has higher donor site morbidity than ALT, but the peri-operative morbidity and mortality, function, and speech outcomes are similar for both flaps and are superior of those attributed to jejunal flap [9]. Voice rehabilitation is certainly superior by the RFF and other fasciocutaneous flaps such as ALT comparing to visceral flaps [10]. RFF seems that it is best suited for partial defects up to 50% of the circumference of the alimentary tract [11]. Others support this choice even for circumferential defects [12]. In our practice it is the procedure of choice for partial and circumferential defects due to flap geometry and characteristics comparing to the other 'skin' flaps, the ALT and PM. The ALT is preferably used as chimeric with two skin paddles in cases where reconstruction is required for hypopharyngeal and neck skin defects simultaneously. The PM although technically is safer and dissected faster, it is bulky and heavy and associated with higher rate of long term complications such as stenosis and fistula formation. It can

be used only for partial defects and usually requires skin grafting at the neck for skin cover. The corresponding author has performed hypopharyngeal reconstructions with all type of 'skin' flaps. We feel that RFF is the preferable option for a quality reconstruction (Table 2).

Potential complications may be considered as disadvantages but are justified due to the nature of the reconstruction. The RFF donor site morbidity has been always an issue. Suprafascial dissection and/or application of skin-dermal substitute (integra) and skin graft ameliorate the quality of donor site reconstruction. Pharyngocutaneous fistula (10 to 20%) is a potential complication, but edge de-epithelialization and double layered suturing 'seals' the tract and may reduce the rate of fistula formation [2,3]. In cases of circumferential defects the 'horseshoe' confirmation by suturing the lateral edges of the flap to the raw prevertebral fascia further reduces the fistula rate (Figure 2d) [12]. Stricture (10%) may also occur, but careful flap design and inset, well prepared recipient site with adequate surgical margins, 'Z-plasty' interdigitation techniques, and judicious use of salivary bypass stent, all enhance the healing process. Murray et al. [7] have shown that there was no statistical significant difference in fistula and stricture rates between RFF and ALT flap. Additionally there was no statistical significant difference in fistula rate between partial and total circumferential defects with the extra vertical suture line. However the partial reconstruction was associated with lower rate of stenosis. In case of total defect and circumferential reconstruction, fistula may occur along the 'T-junction', the area where the vertical suture line joins the proximal or distal anastomosis and less likely along the vertical line only. The 'T-junction' is considered as an area vulnerable to wound dehiscence due to less vascularity [7]. Although studies have shown almost equal rates for fistula rates between proximal and distal anastomosis [13], we have experienced fistula in proximal anastomosis, a finding which was attributed to the fact that this area is adjacent to the tongue area, more 'mobile' and stretched due to the head and tongue movements, in addition to the corrosive effects of saliva.

Postoperatively our aim was to protect the proximal and distal anastomosis from regurgitation of gastric contents but also to feed the patients adequately and enhance the healing process. We tent to keep a nasogastric tube for stenting, gastric decompression and feeding for 2 to 3 weeks. At that time we assessed the efficacy and integrity of reconstruction by performing swallowing test with gastrografin. Then the patient started oral liquid and soft diet for the first few days. In cases where gastrostomy was performed for feeding, we still used the nasogastric tube for stenting and even decompression if needed, and performed the swallowing test at 2 to 3 weeks as well.

## Conclusion

A consensus treatment strategy for reconstructing the defect following hypo pharyngectomy and cervical oesophagectomy has not been established yet. The procedure of choice depends upon the location and size of the carcinoma as well as the patient's

characteristics and the doctor's experience [6]. The RFF and the PM safeguard a feasible reconstruction of hypopharyngo-oesophageal neo-tube and provide satisfactory and consistent functional results. However the RFF offers better quality reconstruction and is considered a superior reconstructive option for patients who can tolerate major surgery. The successful outcome is associated with oral alimentation, good uncomplicated swallowing and improved quality of life. Lower complication rates can be achieved by applying technical modifications.

## References

1. Mathes SJ, Nahai F. Reconstructive Surgery: Principles, Anatomy & Technique. St. Louis, MO: Quality Medical Publishing. 1997:441-65.
2. Piazza C, Taglietti V, Nicolai P. Reconstructive options after total laryngectomy with subtotal or circumferential hypopharyngectomy and cervical esophagectomy. *Curr Opin Otolaryngol Head Neck Surg.* 2012;20:77-88.
3. Chen YD, Chen HC, Vranckx JJ, Schneeberger AG. Edge deepithelialization: a method to prevent leakage when tubed free skin flap is used for pharyngoesophageal reconstruction. *Surgery.* 2001;130:97-103.
4. Lutz BS, Wei FC. Microsurgical workhorse flaps in head and neck reconstruction. *Clin Plast Surg.* 2005;32:421-30.
5. Kim EK, Evangelista M, Evans GRD. Use of free tissue transfer in head and neck reconstruction. *J Craniofac Surg.* 2008;19:1577-82.
6. Xiao Q, Hu GH, Zhong SX, Qian Y, Zeng Q, Hong SL. Reconstruction of Hypopharynx and Cervical Oesophagus for Treatment of Advanced Hypopharyngeal Carcinoma and Recurrent Laryngeal Carcinoma. *Asian J Surg.* 2010;33:14-9.
7. Murray DL, Novak CB, Neligan PC. Fasciocutaneous free flaps in pharyngoesophageal reconstruction: a critical review of the literature. *J Plast Reconstr Aesth Surg.* 2008;61:1148-56.
8. Vartanian JG, Carvalho AL, Carvalho SM, Mizobe L, Magrin J, Kowalski LP. Pectoralis major and other myofascial/myocutaneous flaps in head and neck cancer reconstruction: experience with 437 cases at a single institution. *Head Neck.* 2004;26:1018-23.
9. Scharpf J, Esclamado RM. Reconstruction with radial forearm flaps after ablative surgery for hypopharyngeal cancer. *Head Neck.* 2003;25:261-66.
10. Robb GL, Lewin JS, Deschler DG, Haughey BH, Brown DH, Langmore SE, et al. Speech and swallowing outcomes in reconstructions of the pharynx and cervical esophagus. *Head Neck.* 2003;25:232-44.
11. Disa JJ, Cordeiro PG. Reconstruction of the hypopharynx and cervical esophagus. *Clin Plast Surg.* 2001;28:349-60.
12. Varvares MA, Cheney ML, Gliklich RE, Boyd JM, Goldsmith T, Lazor J, et al. Use of the radial forearm fasciocutaneous free flap and montgomery salivary bypass tube for pharyngoesophageal reconstruction. *Head Neck.* 2000;22:463-68.
13. Li KK, Salibian AH, Allison GR, Krugman ME, Armstrong W, Wong B, et al. Pharyngoesophageal reconstruction with the ulnar forearm flap. *Arch Otolaryngol Head Neck Surg.* 1998;124:1146-51.