



The Fixation of the Glans Penis and Urethral Catheter to Abdominal Skin Avoids Glans Dehiscence after Distal Hypospadias Surgery

Atan A¹, Karabulut R^{2*}, Turkyilmaz Z² and Sonmez K²

¹Departments of Urology, Gazi University, Turkey

²Departments of Pediatric Surgery, Gazi University, Turkey

Abstract

The most common complication which is found in PubMed is hypospadias fistula but there are very less publications related to Glans Dehiscence (GD) for hypospadias surgery. We presented our technique used to avoid GD in patients who underwent Tubularised Incised Plaque Urethroplasty (TIPU) for hypospadias. Twenty-one pediatric patients who were underwent TIPU techniques were evaluated retrospectively. Before dressing, penis and urethral catheter were fixed to abdominal skin by a traction suture placed to the glans penis to avoid the catheter pressure over the suture line. Circular dressing with elastic bandage was not used. In our cases, GD did not happen.

Keywords: Hypospadias; Glans dehiscence; Urethral catheter fixation

Introduction

Glans Dehiscence (GD) that is defined as complete separation of the glans wings is one of the factors affecting the cosmetic and functional outcomes. It has been overlooked or ignored in most studies. When hypospadias complications are searched in the PubMed, there are more than 2,000 publications and the most common result is about the hypospadias fistula but there are very less publications related to GD. These publications were not directly related to GD. GD is only mentioned as a part of complications in the results. In this paper, we presented our technique used to avoid or to reduce GD in patients who underwent TIPU for hypospadias. In this technique, glans penis and urethral catheter were fixed by a suture to lower abdomen in order to keep the urethral catheter immobile.

Description of Technique

Twenty-one patients (8 months to 18 years) who were under went Tubularised Incised Plaque Urethroplasty (TIPU) operation due to distal (n=5) and mid penile (n=16) hypospadias in pediatric patients. Secondary repairment was done in only 4 patients. Four patients had mild penile chordee. Additional corrective surgery was not required. Urethral catheter was removed between 5 to 8 days.

Standart TIPU method was done using proper polydioxanone sutures for urethral plate over Foley (8F to 12F) urethral catheter in all patients, during hypospadias repairment; glanular wings had been adequately dissected. Before dressing, penis and urethral catheter were fixed to abdominal skin by a traction suture placed to the glans penis to avoid the catheter pressure over the suture line (Figure 1). A single layer of surgical gauze was placed under the penis and surgical gauze that was soaked with nitrofurazon pomade was placed over the penis. GD happened before catheter removal in 1 case with mid penile hypospadias (4.7%). It was due to small glans penis. There was no GD in the cases with distal penile hypospadias.

Discussion

If the urethral catheter is not immobile, it may cause damage on delicate glanular suture line, resulting in wound opening. Snodgrass et al., GD was the most common indication for reoperation among their patient [1]. In a study by El-Hawy, standart TIPU (n=196) was compared to modified TIPU (n=173). GD in whole group was found in 1.89% (2% for Group 1 and 1.7% for Group 2) [2].

GD was found in 32 of 641 patients (5%) despite repairs being done by the same surgeon, sutures and operative technique. GD was 3.6 times higher in patients with proximal versus distal

OPEN ACCESS

*Correspondence:

Karabulut R, Departments of Pediatric Surgery, Gazi University, Ankara, Turkey, Tel: 903122026210; Fax: 90 312 2230528;

E-mail: karabulutr@yahoo.com

Received Date: 19 Nov 2018

Accepted Date: 12 Dec 2018

Published Date: 17 Dec 2018

Citation:

Atan A, Karabulut R, Turkyilmaz Z, Sonmez K. The Fixation of the Glans Penis and Urethral Catheter to Abdominal Skin Avoids Glans Dehiscence after Distal Hypospadias Surgery. *Clin Surg*. 2018; 3: 2260.

Copyright © 2018 Karabulut R. This is an open access article distributed under the Creative Commons Attribution License, which permits unrestricted use, distribution, and reproduction in any medium, provided the original work is properly cited.

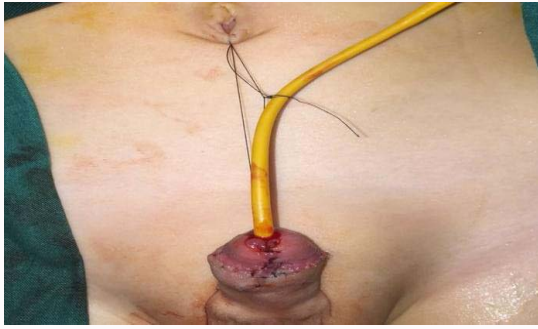


Figure 1: Penis and urethral catheter were fixed to abdominal skin by a traction suture placed to the glans penis to avoid the catheter pressure over the suture line in a patient.

hypospadias. Patients undergoing reoperative (14%) vs. primary TIPU (4%) had a 4.7-fold increased risk of GD [1]. Use of dartos flaps in hypospadias offers no statistically significant advantage over flapless repair for GD rates in another study [3].

Conclusion

Main idea of our study is that the catheter pressure on the anastomotic line will be reduced by glanular and urethral catheter fixation to lower abdominal skin and the wound healing will be better. Our thought was confirmed by our results. A study including a large group of the patients and control group should be done to confirm our results.

References

1. Snodgrass W, Cost N, Nakonezny PA, Bush N. Analysis of risk factors for glans dehiscence after tubularized incised plate hypospadias repair. *J Urol.* 2011;185:1845-9.
2. Abdel-Hamid Mohamid El-Hawy M. Minimal modifications could decrease fistula rate during tubularized incised plate procedure in distal hypospadias repair. *J Pediatr Urol.* 2013;9:789-92.
3. Thomas DT, Karadeniz Cerit K, Yener S, Kandirici A, Dagli TE, Tugtepe H. The effect of dorsal dartos flaps on complication rates in hypospadias repair: a randomised prospective study. *J Pediatr Urol.* 2015;11(1): 23.