



# The Disappearance of Primary Lung Cancer with Liver Metastasis without Gene Mutation after 180 Days Treatment by Lung Cancer Kang

Zhaopu Song, Jing Gao, Yipeng Song, Yuan Li, Yingyi Zhang, Ying Zhang and Suofeng Sun\*

Department of Gastroenterology, Henan Provincial People's Hospital and The People's Hospital of Zhengzhou University, China

## Clinical Image

A 54-year-old male patient was hospitalized at Jingeng Rehabilitation Hospital on August 2020 with complaints of chest tightness and abdominal pain. Given the clinical manifestations, a contrast-enhanced CT scan of the chest and abdomen were performed. The chest CT image showed multiple round low-density shadows of different sizes in both lungs, with a maximum diameter of 2.1 cm (Figure A). The abdominal CT image showed a large area of low-density shadow in the right lobe of the liver, with a maximum diameter of 11.7 cm. In contrast-enhanced CT images of abdomen, we can see large inhomogeneous enhancement in arterial phase and weakened enhancement in portal venous phase, showing the sign of "fast-in-fast-out" (Figure E). The patient was followed up for 6 months. Laboratory and imaging examinations were performed at the same hospital on September 26<sup>th</sup>, October 18<sup>th</sup>, 2020 and January 23<sup>rd</sup>, 2021. Comparing four chest CT images, we can see that the size and number of lesions decreased after treatment (Figures B-D). Similarly, abdominal contrast-enhanced CT images showed that the volume of liver lesions decreased significantly after treatment (Figures F-H). At the latest follow-up, abdominal contrast-enhanced CT scan showed that there was still low-density shadow on the top of the right lobe of the liver, with maximum diameter of 1.5 cm. Chest CT scan showed that the maximum diameter of lung lesions was 0.9 cm. At present, the patient is still in continuous treatment and follow-up, and the symptoms of discomfort basically disappeared.

### OPEN ACCESS

**\*Correspondence:**

Suofeng Sun, Department of Gastroenterology, Henan Provincial People's Hospital, People's Hospital of Zhengzhou University, Zhengzhou 450003, Henan, China, E-mail: sunsuofeng1982@hotmail.com

Received Date: 01 Sep 2021

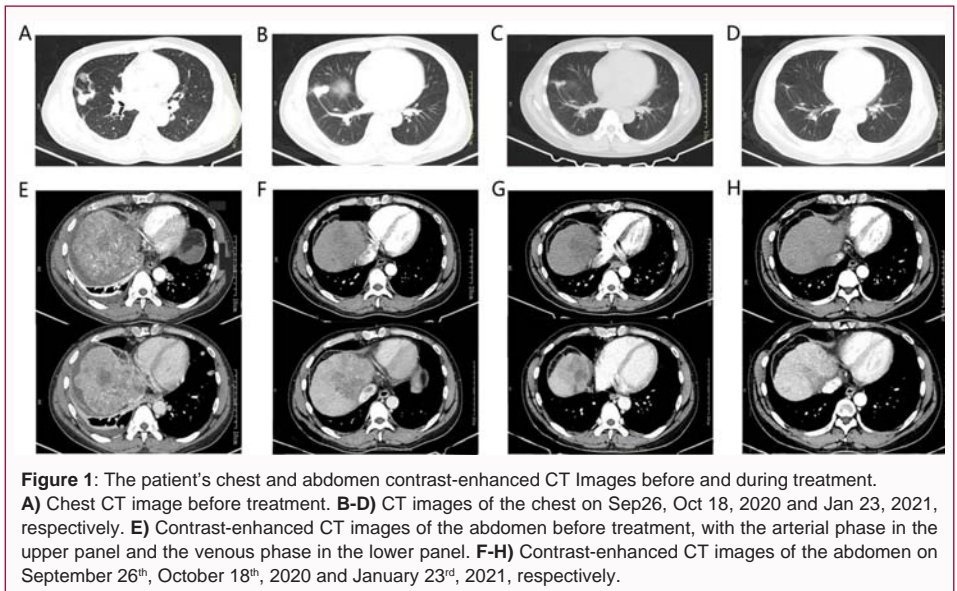
Accepted Date: 05 Oct 2021

Published Date: 12 Oct 2021

**Citation:**

Song Z, Gao J, Song Y, Li Y, Zhang Y, Zhang Y, et al. The Disappearance of Primary Lung Cancer with Liver Metastasis without Gene Mutation after 180 Days Treatment by Lung Cancer Kang. *Clin Surg.* 2021; 6: 3335.

**Copyright** © 2021 Suofeng Sun. This is an open access article distributed under the Creative Commons Attribution License, which permits unrestricted use, distribution, and reproduction in any medium, provided the original work is properly cited.



**Figure 1:** The patient's chest and abdomen contrast-enhanced CT Images before and during treatment. **A)** Chest CT image before treatment. **B-D)** CT images of the chest on Sep26, Oct 18, 2020 and Jan 23, 2021, respectively. **E)** Contrast-enhanced CT images of the abdomen before treatment, with the arterial phase in the upper panel and the venous phase in the lower panel. **F-H)** Contrast-enhanced CT images of the abdomen on September 26<sup>th</sup>, October 18<sup>th</sup>, 2020 and January 23<sup>rd</sup>, 2021, respectively.