



Surgical Treatment of 8 Cases of Atrial Myxoma in Children

Shengliang Zhao^{1,2,3,4}, Zhengxia Pan^{1,2,3,4,5}, Yonggang Li^{1,2,3,4,5}, Yong An^{1,2,3,4,5}, Xin Jin^{1,2,3,4} and Chun Wu^{1,2,3,4,5*}

¹Department of Cardiothoracic Surgery, Children's Hospital of Chongqing Medical University, P.R. China

²Ministry of Education Key Laboratory of Child Development and Disorders, P.R. China

³National Clinical Research Center for Child Health and Disorders (Chongqing), P.R. China

⁴China International Science and Technology Cooperation base of Child Development and Critical Disorders, P.R. China

⁵Chongqing Key Laboratory of Pediatrics, P.R. China

Abstract

Objective: To present our experience on the surgical excision of atrial myxomas in 8 children.

Methods: We retrospectively analyzed the clinical data of 8 children with atrial myxomas admitted to our hospital within the previous 12 years, and we statistically analyzed their clinical manifestations and surgical treatments.

Results: All 8 patients underwent myxoma excision under cardiopulmonary bypass. The 8 patients were followed up for 1 to 11 years, and 1 patient with cerebral infarction combined with hemiplegia of the right limb recovered well after rehabilitation treatment. Two patients had postoperative low cardiac output syndrome, which improved after treatment. None of the 8 children had cerebral embolism, acute heart failure, atrioventricular block or other related complications. There was no recurrence of atrial myxoma in 7 patients, and all patients recovered after surgery. One patient experienced recurrence 5 years after the operation and no recurrence were observed after the second operation.

Conclusion: Although atrial myxoma in children is rare, it may cause cerebral infarction and other multiorgan embolisms. Once atrial myxoma is found, it must be surgically removed as soon as possible, which can not only reduce the risk of severe complications but also increase the possibility of resolution. The surgical removal of tumors under extracorporeal circulation is satisfactory, and there is a risk of recurrence after surgery. Follow-up cardiac ultrasound examinations should be considered after surgery.

Visual Abstract

Key question: To present our experience on the surgical excision of atrial myxomas in 8 children.

Key findings: Cardiac myxoma is a rare clinical entity; the incidence of surgically resected cases is 0.5 to 0.7 per million people, and the prevalence is <5 per 10,000. The reported cases in the literature are mostly in adults. Within the past 12 years, 8 cases of atrial myxoma have been treated in our hospital. Here, we share our experience on the diagnosis and treatment of atrial myxoma in children.

Take-home message: Although atrial myxoma in children is rare, it may cause cerebral infarction and other multiorgan embolisms. The surgical removal of tumors under extracorporeal circulation is satisfactory, and there is a risk of recurrence after surgery.

Keywords: Atrial myxomas; Cardiac tumour; Heart surgery

Introduction

Cardiac myxoma is a rare clinical entity; the incidence of surgically resected cases is 0.5 to 0.7 per million people, and the prevalence is <5 per 10,000 [1]. Atrial myxoma is associated with a risk of embolism caused by tumor thrombus shedding, which can cause hemodynamic abnormalities and endanger the life of patients. Cardiac myxoma should be found early and operated on early. Surgical resection is an effective treatment [2]. The reported cases in the literature are mostly in

OPEN ACCESS

*Correspondence:

Chun Wu, Department of Cardiothoracic Surgery, Children's Hospital of Chongqing Medical University, Ministry of Education Key Laboratory of Child Development and Disorders, China International Science and Technology Cooperation base of Child Development and Critical Disorders, Chongqing Key Laboratory of Pediatrics, Chongqing, 400014, P.R. China, Tel.: +86 23 63633264; Fax: +862363622754;

E-mail: wuchun0312@sina.com

Received Date: 16 Apr 2021

Accepted Date: 10 May 2021

Published Date: 18 May 2021

Citation:

Zhao S, Pan Z, Li Y, An Y, Jin X, Wu C. Surgical Treatment of 8 Cases of Atrial Myxoma in Children. Clin Surg. 2021; 6: 3174.

Copyright © 2021 Chun Wu. This is an open access article distributed under the Creative Commons Attribution License, which permits unrestricted use, distribution, and reproduction in any medium, provided the original work is properly cited.

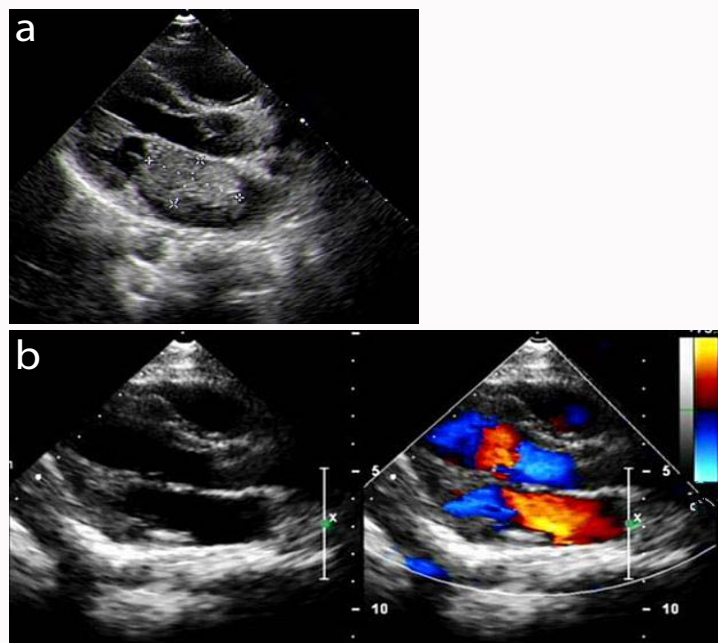


Figure 1: Preoperative (1a) and postoperative (1b) ultrasound examination of atrial myxoma.

adults. Within the past 12 years, 8 cases of atrial myxoma have been treated in our hospital. Here, we share our experience on the diagnosis and treatment of atrial myxoma in children.

Methods

We retrospectively analyzed the clinical data of 8 children with atrial myxomas admitted to the Department of Cardiothoracic Surgery at the Children's Hospital of Chongqing Medical University from January 2010 to January 2021. The Medical Research Ethics Committee of the Children's Hospital Affiliated with Chongqing Medical University approved the study, and written informed consent was obtained from the families of all children.

Operative techniques

All 8 children underwent surgery under hypothermic cardiopulmonary bypass using a median sternotomy incision. In 6 cases of left atrial myxoma, the right atrium-atrial septum incision was used, the right atrium was incised obliquely, the interatrial septum was incised up and down along the foramen ovale, the tumor was lifted toward the right atrium, and the tumour tissue was completely removed. During the operation, the right atrium, right ventricle, left ventricle, mitral valve and tricuspid valve were simultaneously explored. After the tumour was removed, the heart cavity was repeatedly flushed with normal saline.

Results

There were 3 males and 5 females, aged 2 years and 5 months-12 years and 9 months, with a median age of 8.9 years and a body weight of 11 kg to 45 kg (28.2 ± 13.40 kg). There were 2 cases of right atrial myxomas and 6 cases of left atrial myxomas. The clinical manifestations were cough, shortness of breath, and palpitations in 2 patients, weakness in the upper and lower limbs with aphasia in 2 patients, dizziness and fainting in 1 patient, and a significant decrease in exercise tolerance in 1 patient. One patient presented with superior vena cava obstruction syndrome and edema of the head, face, neck and upper limbs, and one patient had cerebral infarction with

hemiplegia of the right limb. There were 7 patients with abnormal ECG findings, 4 patients with sinus tachycardia, 2 patients with T wave changes, 1 patient with abnormal Q waves, and 1 patient without obvious abnormalities. The physical examination revealed that the 8 patients had cardiac murmurs at the apex, including 5 cases of simple diastolic murmurs and 3 cases of simple systolic murmurs. All 8 cases were diagnosed by echocardiography, including 2 cases of right atrial myxoma and 6 cases of left atrial myxoma. The echocardiograms showed that there was an abnormal echo light mass in the atrium with an unclear boundary that moved when the heart contracted and relaxed. See Figure 1 for details. Among the 6 cases of left atrial myxoma, 1 case in the left heart was significantly enlarged. The giant left atrial myxoma almost filled the left atrium, with grape cluster-like changes of varying sizes, a jelly-like substance in the tumour, and the base pedicle in the right upper pulmonary vein below the opening. The pedicle was approximately 0.5 cm wide and 0.3 cm long. In 2 cases, a medium mass was seen in the left atrium; it was approximately 6 cm \times 5 cm in size, 1.5 cm wide at the base, and connected to the anterior mitral valve. In 1 case, tumor tissue measuring 6 cm \times 4 cm was seen in the left atrium and the front end was inserted into the mitral valve opening, causing mitral valve stenosis and insufficiency. The pedicle was located at the root of the anterior mitral valve, with calcification at the base, no obvious boundary, and mural thrombosis. In 2 cases, the left atrium was enlarged, and purple-brown masses measuring 8 cm \times 7 cm \times 6 cm and 6 cm \times 7 cm \times 5.5 cm were seen. Among the 2 cases of right atrial myxoma, 1 case showed a 6 cm \times 7 cm \times 5.5 cm purple-brown mass in the right atrium, with a pedicle width of approximately 1 cm, and 1 case showed 2 cm \times 3 cm tumour-like tissue on the right atrial septal valve. The 8 patients underwent myxoma excision under cardiopulmonary bypass, 2 patients directly underwent foramen ovale suture closure, 4 patients underwent pericardial patch repair due to large atrial septal defects, 3 patients underwent mitral valvuloplasty, and 1 patient underwent tricuspid annulus contraction. The mean time of aortic occlusion was 40.12 min (38 min to 43 min), the mean time of cardiopulmonary bypass was 69.67 min (65 min to 72 min), and the mean time of operation

was 205.36 min (155 min to 265 min). The 8 patients were followed up for 1 to 11 years, and 1 patient with cerebral infarction combined with hemiplegia of the right limb recovered well after rehabilitation treatment. Two patients had postoperative low cardiac output syndrome, which improved after treatment. None of the 8 children had cerebral embolism, acute heart failure, atrioventricular block or other related complications. The pathological diagnosis after surgery was atrial myxoma. There was no recurrence of atrial myxoma in 7 patients, and all patients recovered after surgery. One patient experienced recurrence 5 years after the operation and no recurrence were observed after the second operation.

Discussion

Cardiac myxoma is a primary benign tumour that occurs in approximately 75% of women. The most common site is the left atrium, and the pedicle is often located in the foramen ovale in the atrial septum [3]. A total of 8 patients were included in this study, including 3 males and 5 females; there were 2 cases of right cardiac myxoma and 6 cases of left cardiac myxoma, which is consistent with the results of previous studies. The Etiology of atrial myxoma is still unclear. Some studies have shown that atrial myxoma arises from pluripotent cardiac stem cells; some studies have shown that atrial myxoma may be familial, and in some families, it may be an autosomal recessive disease. Whether the environment or other factors are related to the disease is unclear [4,5]. The clinical symptoms of atrial myxoma are not obvious, and they are often found in physical examinations or after acute cerebral infarction. Tumor activity can block the atrioventricular valve and obstruct blood flow, causing abnormal haemodynamics and even sudden death. Furthermore, these tumors are fragile and easily detach, which can lead to embolism. Therefore, these tumors should be detected early and operated on early, and surgery is an effective treatment method [6,7]. The clinical presentations of atrial myxoma tumors depend on the size, location and activity of the tumour and are non-specific. The common manifestations include palpitations, shortness of breath, chest tightness, cough, syncope and heart failure. Left atrial myxoma may also lead to systemic embolism due to the detachment of a tumour-related thrombus or the presence of a thrombus on the surface of the tumour. Right atrial myxoma may cause fainting and sudden death due to blockage of the tricuspid valve. Obstruction of the upper or inferior vena cava may cause edema of the face or lower extremities. In this study, 2 patients were seen in the Department of Neurology at the beginning of onset due to decreased limb muscle strength. One patient was referred to the neurosurgery department due to cerebral infarction and cerebral vasodilation, and 1 patient was referred to the respiratory medicine department due to cough and shortness of breath. Therefore, early diagnosis is very important. Echocardiography is the simplest and most reliable diagnostic method for this disease. We understand that the tissue of atrial myxoma in children is fragile, and those with incomplete capsules are more likely to be broken. Therefore, the operation needs to be performed with caution to avoid turning and squeezing the heart. The normal atrial septal tissue where the tumour is attached should be clamped when the tumour is resected. We lifted the tumour completely out of the heart cavity to prevent the tumour from breaking. We completely removed the tumour and attached tissues during the operation and carefully checked for any defects after the tumour was removed to prevent tumour fragments from being left. After resection, the defect of the atrial septum or left atrium wall was repaired with a pericardial patch taken in advance if necessary. In

this study, 4 patients underwent pericardial repair due to large atrial septal defects, and 3 patients underwent mitral valvuloplasty due to the large base of the tumor, which can easily damage the left atrium and affect the structure of the mitral valve. One case of a large tumour expanded the tricuspid annulus, so tricuspid annulus contraction was performed. It has been reported in the literature that the recurrence rate of atrial myxoma is 5% to 14%, and secondary recurrence is rare. Only 7 cases of recurrence have been reported in the literature [8,9]. In this study, there was 1 case of recurrence 5 years after surgery. Recurrence occurred because the tumor was incompletely resected, so parts of the tumor remained, and malignant transformation of the tumor and tumor implantation in the heart occurred. Therefore, we should closely follow up patients with atrial myxoma. In centers with clinicians who are highly experienced in performing minimally invasive procedures, thoracoscopic resection of atrial myxoma can be the first choice for surgical treatment of atrial myxoma [10-12]. However, due to the narrow operating space of thoracoscopy, special equipment and peripheral cardiopulmonary bypass are required, and the safety and clinical effects of thoracoscopic atrial myxoma resection remain unclear. Due to differences in surgical field exposure and observation methods, complete tumor resection is not always achieved, as tumor tissue easily detaches during the operation, and incomplete resection may lead to postoperative recurrence or an increased risk of systemic embolism [13-15].

Conclusion

Although atrial myxoma in children is rare, it may cause cerebral infarction and other multiorgan embolisms. Once atrial myxoma is found, it must be surgically removed as soon as possible, which can not only reduce the risk of severe complications but also increase the possibility of resolution. The surgical removal of tumors under extracorporeal circulation is satisfactory, and there is a risk of recurrence after surgery. Follow-up cardiac ultrasound examinations should be considered after surgery.

Declarations

Ethics approval and consent to participate

The Medical Research Ethics Committee of Children's Hospital Affiliated to Chongqing Medical University approved the study, and this study obtained written informed consent from the families of all children.

Availability of data and materials

The datasets used and analyzed during the current study are available from the corresponding author upon reasonable request.

Authors contributions

ZSL analyzed and interpreted the patient data regarding atrial myxoma. JX was responsible for data collation. PZX, AY, and LYG were responsible for part of the design of the paper. PZX, AY, LYG, and WC performed for atrial myxoma surgery. ZSL and WC were major contributors in writing the manuscript. All authors read and approved the final manuscript.

References

1. MacGowan SW, Sidhu P, Aherne T, Luke D, Wood AE, Neligan MC, et al. Atrial myxoma: National incidence, diagnosis and surgical management. *Ir J Med Sci.* 1993;162(6):223-6.
2. Myers P, Konstantinidis S, Karatzas N, Milas F, Panos A. Pericardial synovial sarcoma of the heart; is it always worth operating? *J Cardiovasc Surg (Torino).* 2011;52(5):749-51.

3. Sabiston D, Spencer F. *Surgery of the chest*. New York: A Harcourt Publishers International Company. 2001;2069-85.
4. Scalise M, Torella M, Marino F, Ravo M, Giurato G, Vicinanza C, et al. Atrial myxomas arise from multipotent cardiac stem cells. *Eur Heart J*. 2020;41(45):433245.
5. Roy ANS, Radin M, Sarabi D, Shaoulian E. Familial recurrent atrial myxoma: Carney's complex. 2011;34(2):83-6.
6. Ito S, Endo A, Okada T, Nakamura T, Adachi T, Nakashima R, et al. Acute myocardial infarction due to left atrial myxoma. *Intern Med*. 2016;55(1):49-54.
7. Myers P, Konstantinidis S, Karatzas N, Milas F, Panos A. Pericardial synovial sarcoma of the heart; is it always worth operating? *J Cardiovasc Surg (Torino)*. 2011;52(5):749-51.
8. Dato GMA, Benedictis M, Dato AA, Ricci A, Sommariva L, Paulis R. Long-term follow-up of cardiac myxomas (7-31 years). *J Cardiovasc Surg*. 1993;34(2):141-3.
9. Castells E, Ferran O. Cardiac myxomas: Surgical treatment and recurrence. *J Cardiovasc Surg*. 1990;31(Suppl.):2.
10. Yu S, Xu X, Zhao B, Jin Z, Gao Z, Wang Y, et al. Totally thoracoscopic surgical resection of cardiac myxoma in 12 patients. *Ann Thorac Surg*. 2010;90(2):674-6.
11. Schroder C, Leukhardt WH, Hsiao EM, Farah GM, Markowitz AH. Transaortic video assisted resection of a recurrent left ventricular myxoma. *Ann Thorac Surg*. 2013;95(1):340-2.
12. Panos A, Myers PO. Video-assisted cardiac myxoma resection: basket technique for complete and safe removal from the heart. *Ann Thorac Surg*. 2012;93(4):e109-10.
13. Deshpande RP, Casselman F, Bakir I, Cammu G, Wellens F, Geest R, et al. Endoscopic cardiac tumor resection. *Ann Thorac Surg*. 2007;83(6):2142-6.
14. Owais TA, Farber G, Garbade J, Mohr FW. Excision of a left atrial myxoma via a minimally-invasive technique: A possible routine access. *Interact Cardiovasc Thorac Surg*. 2011;12(5):875-7.
15. Vistarini N, Alloni A, Aiello M, Vigano M. Minimally invasive video-assisted approach for left atrial myxoma resection. *Interact Cardiovasc Thorac Surg*. 2010;10(1):9-11.