



## Surgical Tips for the Conservative Surgical Treatment of Ovarian Endometrioma: An Overview with Video Presentation

Seok Ju Seong and Mi-La Kim\*

Department of Obstetrics & Gynecology, CHA Gangnam Medical Center, CHA University, Republic of Korea

### Abstract

Surgical treatment is the most effective treatment modality for women with endometriosis-related pain or infertility. However, surgical treatment can reduce the ovarian reserve owing to considerable adherence between the ovarian endometrioma and underlying ovarian parenchyma. In this review, we focus on surgical tips for the conservative surgical treatment of ovarian endometrioma to reduce ovarian damage, with and accompanying video presentation.

**Keywords:** Ovarian endometrioma; Surgical treatment; Ovarian reserve

### Introduction

The reported incidence of endometriosis for women of childbearing age ranges from 0.8% to 2%, and the incidence rate is 2-5 times higher in infertile women. About one-third of all women with endometriosis are infertile [1-6]. Endometrioma is defined as endometriosis cysts that form as a result of the accumulation of endometrial tissue within the ovary. It accounts for 35% of benign ovarian cysts and is found in 20% to 40% of patients with endometriosis [7-9]. Endometriomas contain sticky chocolate-colored fluid that originates from previous bleeding within the ovary (Figure 1). They often adhere to the peritoneum of the pelvis, causing the ovary to invaginate, and rarely develop into malignant tumors. While medical treatment can reduce the size of endometriomas by up to 57%, surgical treatment is considered the most effective treatment modality [10].

Surgical treatment is indicated for patients who have dysmenorrhea, pelvic pain, dyspareunia, or are currently undergoing treatment for infertility, for whom an increase in the likelihood of pregnancy after surgery seems promising, as well as for those who are suspected of having rupture or torsion of ovarian tumors. Compared to laparotomy, laparoscopy has the advantages of faster recovery, reduced use of analgesics, a shorter hospital stay, and lower rates of postoperative adhesion compared to laparotomy, with similar pregnancy and relapse rates [11].

While laparoscopy is generally accepted as the standard method of conservative treatment for ovarian endometriomas, the detailed steps involved in the procedure are still controversial. Excessive resection of endometriomas can lead to substantial destruction of normal ovarian tissues, while incomplete surgery can lead to early relapse. Although an increase in natural pregnancy rates can be expected with laparoscopy for infertile patients, the risk of damaging the ovary owing to the surgical procedure must be considered.

Therefore, the present review discusses different types of laparoscopy techniques for the conservative treatment of endometriomas, their advantages and disadvantages, and describes each procedure in detail.

### Surgical Treatment of Endometrioma

Most common conservative treatment of endometrioma is removal or resection of the endometrioma. Sclerotherapy and ablation are also considered as conservative treatment.

#### Drainage and sclerotherapy

Endometriomas are drained under ultrasonic guidance, and rinsed with ethanol, tetracycline, or methotrexate to induce their sclerosis. While this procedure has been reported to produce satisfactory results, it is not recommended since it results in little symptom relief and is associated with high risk of infection, high relapse rates, and risk for peritoneal metastases in the case of patients

### OPEN ACCESS

#### \*Correspondence:

Mi-La Kim, Department of Obstetrics & Gynecology, CHA Gangnam Medical Center, CHA University, 566, Nonhyeon-ro, Gangnam-gu, Seoul 06135, Republic of Korea, Tel: 82234683676; Fax: 8225581112; E-mail: mila76@naver.com

Received Date: 30 Aug 2018

Accepted Date: 02 Oct 2018

Published Date: 05 Oct 2018

#### Citation:

Seong SJ, Kim M-L. Surgical Tips for the Conservative Surgical Treatment of Ovarian Endometrioma: An Overview with Video Presentation. *Clin Surg.* 2018; 3: 2142.

Copyright © 2018 Mi-La Kim. This is an open access article distributed under the Creative Commons Attribution License, which permits unrestricted use, distribution, and reproduction in any medium, provided the original work is properly cited.

**Table 1:** Comparison of the coagulation methods.

Coagulation techniques	Advantage	Disadvantage
Bipolar coagulation	Easy to perform Requires a short time	Produce local inflammation Damage to normal follicle Higher rates of reduced ovarian reserve
Laser ablation	Little smoke -> good vision Little damage to the ovarian tissue	Weak coagulation effect Difficult to understand the exact layer thickness
Suturing	Reduce damage to the normal ovarian tissue by minimizing the coagulation process Reapproximation of the ovarian tissue	Difficult to learn Requires a long time Can damage normal ovarian tissue by suture itself
Hemostatic sealants	Easy to perform Little tissue damage	Expensive Risks of thrombosis or small bowel obstruction Possibility of viral transmission
Vasopressin injection	Hydrodissection & vessel constriction simultaneously : more accurate separation of the cyst wall & prevention of additional removal of normal ovarian tissue Reduce bleeding Reduce operation time	Possibility of delayed bleeding

with malignant ovarian tumors [12,13]. However, the procedure may be useful during the collection of oocytes in patients with reduced ovarian reserve or for those who cannot undergo surgical treatment.

### Drainage and ablation

After making an incision on an endometrioma, its inner wall is cauterized or coagulated with a laser and vaporized with a carbon-dioxide laser. This procedure prevents damage to normal ovarian tissue and relieves pelvic pain. However, in a systematic review that compared ablation to laparoscopy, ablation was associated with lower pregnancy rates and less pain reduction, and had relatively high reoperation and relapse rates [14]. In addition, while ablation is effective for small lesions, it requires a substantial amount of time for large cysts, can cause heat damage to the surrounding tissues and normal ovarian tissues, and does not destroy all cystic walls. Therefore, ablation is currently performed only for sites where removal of ovarian cysts is incomplete.

### Cystectomy

Cystectomy is the most preferred method of surgery over the procedures mentioned above. It is associated with low rates of recurrent endometriomas or symptoms, and higher pregnancy rates [15-17]. Disadvantages of the procedure include ovarian adhesions and reduced ovarian reserve.

Cystectomy involves isolation of the endometrioma from the surrounding adhesions, complete aspiration of cystic contents, and dissection of normal ovarian tissues from the cystic wall using fine tools, followed by stripping of the cystic wall from the normal ovary. It is important to accurately identify the boundary between the normal ovary and the cystic wall before stripping. Boundaries between endometriomas and the normal ovary are often not clearly visible. Careless removal of endometriomas or inadvertent removal of the normal ovarian cortex can lead to loss of follicles and a reduced ovarian reserve. Loss of ovarian reserve can also result from electrocauterization used to stop bleeding after the removal of cystic walls. It is important to accurately identify the boundary between an endometrioma and the normal ovary and minimize the coagulation process by preventing bleeding in order to reduce these risks. Details of the steps involved in laparoscopy are provided below.

First, adhesions around the endometrioma are removed to enable mobilization.

Since endometriomas are accompanied by pelvic endometriosis,

they often adhere to other organs. Even if the adhesion is not severe, endometriomas are often found adherent to the peritoneum of the pelvis. Endometriomas must be free of adhesions before surgery. Second, an incision is made on the endometrioma. An incision must be made on the antimesenteric surface as far away from the hilum of the ovary as possible (Figure 2). Cyst rupture commonly occurs during the removal of adhesions. An incision is made by using scissors or a laser while holding the ruptured area or the normal ovarian cortex with forceps. Ideally, an incision should be made along the longest diameter of the endometrioma. Such an incision not only makes the surgical procedure much easier, but also provides sufficient visibility during the coagulation process.

Third, once an incision is made, the boundary between the ovarian cortex and the cystic wall is identified, and the cystic wall is removed.

Accurate boundary identification reduces damage to the normal ovarian tissue. If the endometrioma has not ruptured, it is recommended to rupture the endometrioma after detaching the ovary from the cystic wall to a certain extent for easier identification of the boundary. If rupture has already occurred, it is recommended to perform detachment where the boundary is more visible through an incision. In case of incomplete removal of endometrioma owing to inaccurate identification of the border, it may be useful to perform cauterization on the cystic wall. Until these procedures, Supplemental Digital Content 1 was presented.

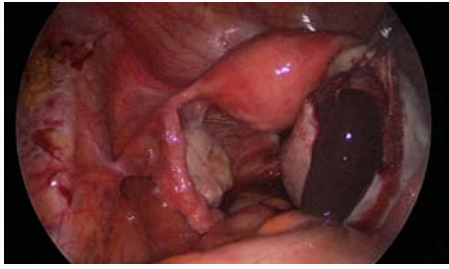And finally, coagulation is performed.

## Coagulation Techniques after Ovarian Cystectomy

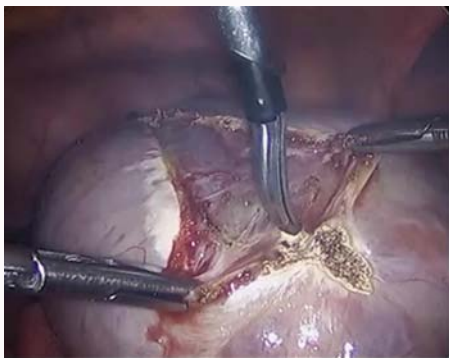
Coagulation techniques include bipolar coagulation, laser ablation, suturing, hemostatic sealant, and vasopressin injection (Table 1). This step is important for conservation of the ovarian reserve.

### Bipolar coagulation technique

Bipolar coagulation is easy to perform and requires a short amount of time, but can produce local inflammation during the coagulation process, and damage normal follicles. Extensive coagulation around the hilum can result in an especially significant loss of follicles due to reduced blood flow into the ovary. Bipolar coagulation is associated with higher rates of reduced ovarian reserve compared to other coagulation techniques.



**Figure 1:** An overview of ovarian endometrioma which contains sticky chocolate-colored fluid that originates from previous bleeding within the ovary.



**Figure 2:** An incision is made on the surface of endometrioma. Usually longitudinal incision on the antimesenteric surface is preferred for the prevention of damage on the hilum area.

### Laser ablation

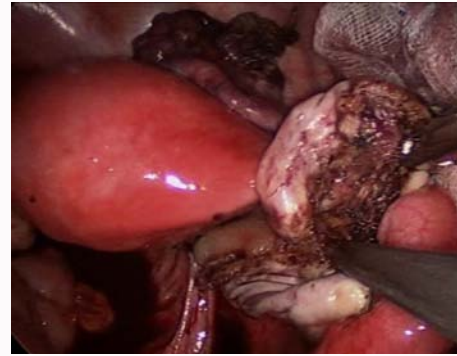
Laser ablation involves shallow tissue vaporization of the glandular epithelium and subjacent stroma. While laser ablation has the advantage of limited smoke production, which ensures good vision, and little damage to the ovarian tissue, it has weak coagulation effects, which makes it difficult to accurately assess the layer thickness [18]. Donnez et al. performed partial cystectomy by stripping for 80% to 90% of endometriomas and proposed a method in which the remaining 10% to 20% of the endometriomas around the hilus, which contains substantial functional ovarian tissue and has a poorly visible cleavage plane, were vaporized with a CO<sub>2</sub> laser. They reported similar volumes and antral follicle counts between the treated ovary and the opposite ovary [19].

### Sutures

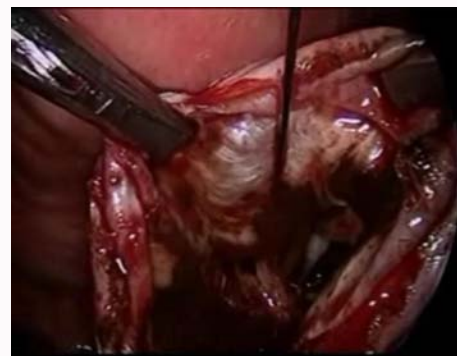Sutures can reduce damage to the normal ovarian tissue by minimizing the coagulation process while reapproximating the ovarian tissue. However, suture techniques are difficult to learn, require a long time if performed by inexperienced surgeons, and can damage normal ovarian tissue. Suture techniques are reported to have a smaller impact on reduced ovarian reserve [20] and similar relapse and pregnancy rates compared to bipolar coagulation [21].

### Hemostatic sealants

The hemostatic sealants with the trade name FloSeal® was approved by the Food and Drug Administration in 1999. Its constituents include thrombin, calcium chloride, and specifically treated or purified gelatin, and it consists of two separate syringes. Once the site of bleeding is identified, a sufficient quantity of FloSeal Matrix is applied by using the tip of a syringe until a small "hill" forms (Figure 3). Two minutes after fixing the FloSeal Matrix onto the lesion by bringing it into contact with the bleeding site with wet gauze, the



**Figure 3:** A hemostatic sealant is applied. On the bleeding site, a sufficient quantity of hemostatic sealant is applied by using the tip of a syringe until a small "hill" forms.



**Figure 4:** Vasopressin injection: 3-4 points on the boundary between the ovarian parenchyma and the cystic wall while avoiding large vessels before separating the cystic wall from the ovary.

gauze is lifted to inspect the lesion. To prevent the blood clot from collapsing, the gauze is removed after the bleeding is stopped. If the gauze becomes stuck to the newly formed blood clot, the clot is rinsed with a saline solution that has not been treated with heparin, and the sponge is carefully removed from the treated site. Once bleeding stops, any substances that did not mix into the blood clot are lightly washed off. The FloSeal® that has fused with the blood clot is not physically separated, and any substances that have mixed with the blood clot are left as they are. The advantages of this procedure are that it is easy to perform and causes little tissue damage [22,23]. A recent systematic review and meta-analysis comparing hemostatic sealants with sutures and bipolar coagulation reported that hemostatic sealants had a smaller influence on ovarian reserve in terms of anti-Müllerian hormone (AMH) [24]. However, hemostatic sealant is expensive and has been reported to cause thrombosis or small bowel obstruction after use. They are also believed to be associated with risk for viral transmission, although no study to date has reported on this association [25-27].

### Vasopressin

The final coagulation technique to discuss is the use of vasopressin. This technique involves injection of a diluted vasopressin solution into 3-4 points on the boundary between the ovarian parenchyma and the cystic wall while avoiding large vessels before separating the cystic wall from the ovary (Figure 4). This method not only enables more accurate separation of the cystic wall through hydrodissection, but also reduces bleeding through the effects of vasopressin. Since the cystic wall is separated precisely, the operation time is reduced,

and the removal of normal ovarian tissue can be prevented. Furthermore, reduced bleeding minimizes unnecessary steps in the coagulation process, thereby reducing damage to ovarian tissue [28-30]. However, Ghafarnejad et al. compared vasopressin and saline injection in a randomized prospective study and found no statistical differences in operation time, frequency of electrocoagulation, or postoperative antral follicle count change [29]. Qiong-Zhen et al. performed prospective randomized study comparing the number of coagulation events, thickness of ovarian tissue removed, and basal follicle-stimulating hormone (FSH) levels in patients with bilateral ovarian endometriomas treated with stripping only, saline injection, or vasopressin injection. Compared to stripping only, the saline-treated group demonstrated a lower frequency of coagulation, less removal of ovarian tissue, and lower preoperative FSH levels, while the vasopressin group had fewer coagulation events and lower preoperative FSH levels than the saline group. However, research on AMH, which reflects the capacity of the ovary to store eggs, is still lacking; therefore, additional randomized controlled trials must be conducted. To date, there has been no report of delayed bleeding after surgery, which is a side effect of vasopressin use.

## Conclusion

Currently, there is no definitive treatment for the optimal management of endometriomas. Pharmacotherapy results in temporary pain relief and prevents relapses, whereas ultrasound-guided drainage has limited effects. While the general consensus is that laparoscopic cystectomy is the most effective conservative treatment for endometriomas, its effects on reducing ovarian reserve remain controversial. The most important steps of this procedure are, first, the separation of the cystic wall from the normal ovarian tissue by accurately identifying the boundary between them; second, removing as much of the cystic wall as possible; and, third, the coagulation. To minimize damage to the ovarian tissue during the coagulation process, it is important to employ various techniques, as described above, according to the situation rather than using a single technique.

## References

- Moen MH, Schei B. Epidemiology of endometriosis in a Norwegian county. *Acta Obstet Gynecol Scand.* 1997;76(6):559-62.
- Abbas S, Ihle P, Köster I, Schubert I. Prevalence and incidence of diagnosed endometriosis and risk of endometriosis in patients with endometriosis-related symptoms: findings from a statutory health insurance-based cohort in Germany. *Eur J Obstet Gynecol Reprod Biol.* 2012;160(1):79-83.
- Gylfason JT, Kristjansson KA, Sverrisdottir G, Jonsdottir K, Rafnsson V, Geirsson RT. Pelvic endometriosis diagnosed in an entire nation over 20 years. *Am J Epidemiol.* 2010;172(3):237-43.
- Ballard KD, Seaman HE, de Vries CS, Wright JT. Can symptomatology help in the diagnosis of endometriosis? Findings from a national case-control study - Part 1. *BJOG.* 2008;115(11):1382-91.
- Leibson CL, Good AE, Hass SL, Ransom J, Yawn BP, O'Fallon WM, et al. Incidence and characterization of diagnosed endometriosis in a geographically defined population. *Fertil Steril.* 2004;82(2):314-21.
- Shakiba K, Bena JF, McGill KM, Minger J, Falcone T. Surgical treatment of endometriosis: a 7-year follow-up on the requirement for further surgery. *Obstet Gynecol* 2008;111(6):1285-92.
- Vercellini P, Chapron C, De Giorgi O, Consonni D, Frontino G, Crosignani PG. Coagulation or excision of ovarian endometriomas? *Am J Obstet Gynecol.* 2003;188(3):606-10.
- Jenkins S, Olive DL, Haney AF. Endometriosis: pathogenetic implications of the anatomic distribution. *Obstet Gynecol.* 1986;67(3):335-8.
- Redwine DB. Ovarian endometriosis: a marker for more extensive pelvic and intestinal disease. *Fertil Steril.* 1999;72(2):310-5.
- Farquhar C, Sutton C. The evidence for the management of endometriosis. *Curr Opin Obstet Gynecol.* 1998;10(4):321-32.
- Pados G, Tsolakidis D, Bontis J. Laparoscopic management of the adnexal mass. *Ann N Y Acad Sci.* 2006;1092:211-28.
- Vercellini P, Vendola N, Boccione L, Colombo A, Rognoni MT, Bolis G. Laparoscopic aspiration of ovarian endometriomas. Effect with postoperative gonadotropin releasing hormone agonist treatment. *J Reprod Med.* 1992;37(7):577-80.
- Donnez J, Nisolle M, Gillet N, Smets M, Bassil S, Casanas-Roux F. Large ovarian endometriomas. *Hum Reprod* 1996;11(3):641-6.
- Alborzi S, Ravanbakhsh R, Parsanezhad ME, Alborzi M, Alborzi S, Dehbashi S. A comparison of follicular response of ovaries to ovulation induction after laparoscopic ovarian cystectomy or fenestration and coagulation versus normal ovaries in patients with endometrioma. *Fertil Steril.* 2007;88(2):507-9.
- Hart R, Hickey M, Maouris P, Buckett W, Garry R. Excisional surgery versus ablative surgery for ovarian endometriomata: a Cochrane Review. *Human Reprod.* 2005;20(11):3000-7.
- Alborzi S, Momtahan M, Parsanezhad ME, Dehbashi S, Zolghadri J, Alborzi S. A prospective, randomized study comparing laparoscopic ovarian cystectomy versus fenestration and coagulation in patients with endometriomas. *Fertil Steril.* 2004;82(6):1633-7.
- Hart RJ, Hickey M, Maouris P, Buckett W. Excisional surgery versus ablative surgery for ovarian endometriomata. *Cochrane Database Syst Rev.* 2008;16(2):CD004992.
- Donnez J, Wyns C, Nisolle M. Does ovarian surgery for endometriomas impair the ovarian response to gonadotropin? *Fertil Steril* 2001;76(4):662-5.
- Donnez J, Lousse JC, Jadoul P, Donnez O, Squifflet J. Laparoscopic management of endometriomas using a combined technique of excisional (cystectomy) and ablative surgery. *Fertil Steril.* 2010;94(1):28-32.
- Benaglia L, Somigliana E, Vighi V, Ragni G, Vercellini P, Fedele L. Rate of severe ovarian damage following surgery for endometriomas. *Hum Reprod.* 2010;25(3):678-82.
- Ferrero S, Venturini PL, Gillott DJ, Remorgida V, Leone Roberti Maggiore U. Hemostasis by bipolar coagulation versus suture after surgical stripping of bilateral ovarian endometriomas: a randomized controlled trial. *J Minim Invasive Gynecol.* 2012;19(6):722-30.
- Song T, Lee SH, Kim WY. Additional benefit of hemostatic sealant in preservation of ovarian reserve during laparoscopic ovarian cystectomy: a multi-center, randomized controlled trial. *Hum Reprod.* 2014;29(8):1659-65.
- Sonmezer M, Taskin S, Gemici A, Kahraman K, Ozmen B, Berker B, et al. Can ovarian damage be reduced using hemostatic matrix during laparoscopic endometrioma surgery? A prospective, randomized study. *Arch Gynecol Obstet.* 2013;287(6):1251-7.
- Ata B, Turkgeldi E, Seyhan A, Urman B. Effect of hemostatic method on ovarian reserve following laparoscopic endometrioma excision: comparison of suture, hemostatic sealant, and bipolar desiccation. A systematic review and meta-analysis. *J Minim Invasive Gynecol.* 2015;22(3):363-72.
- Steinestel K, Geiger A, Naraghi R, Kunz U, Danz B, Kraft K, et al. Fatal thromboembolism to the left pulmonary artery by locally applied hemostatic matrix after surgical removal of spinal schwannoma: a case report. *Hum Pathol.* 2013;44(2):294-8.

26. Ferschl MB, Rollins MD. Thromboemboli, acute right heart failure and disseminated intravascular coagulation after intraoperative application of a topical hemostatic matrix. *Anesth Analg*. 2009;108(2):434-6.
27. Clapp B, Santillan A. Small bowel obstruction after FloSeal use. *JSLs*. 2011;15(3):361-4.
28. Saeki A, Matsumoto T, Ikuma K, Tanase Y, Inaba F, Oku H, et al. The vasopressin injection technique for laparoscopic excision of ovarian endometrioma: a technique to reduce the use of coagulation. *J Minim Invasive Gynecol*. 2010;17(2):176-9.
29. Ghafarnejad M, Akrami M, Davari-Tanha F, Adabi K, Nekuie S. Vasopressin effect on operation time and frequency of electrocauterization during laparoscopic stripping of ovarian endometriomas: a randomized controlled clinical trial. *J Reprod Infertil*. 2014;15(4):199-204.
30. Qiong-Zhen R, Ge Y, Deong Y, Qian ZH, Zhu WP. Effect of vasopressin injection technique in laparoscopic excision of bilateral ovarian endometriomas on ovarian reserve: prospective randomized study. *J Minim Invasive Gynecol*. 2014;21(2):266-71.