



## Surgical Guidance in Foot Surgery by Means of 3D Impression and Minimally Invasive Surgery

Javier Ferrer-Torregrosa<sup>1\*</sup>, Nadia Fernández-Ehrling<sup>2</sup>, Sergio García Vicente<sup>3</sup> and Carlos Barrios<sup>4</sup>

<sup>1</sup>Department of Podiatry, Physiotherapy and Podiatry School, Valencia Catholic University, Valencia, Spain

<sup>2</sup>Doctorate School, Valencia Catholic University, Valencia, Spain

<sup>3</sup>Private Clinic, Valencia, Spain

<sup>4</sup>Institute for Research on Musculoskeletal Disorders, Valencia Catholic University, Valencia, Spain

### Abstract

**Background:** Surgical accuracy in minimal incision foot surgery is an unexplored field. Optimal gateways and more precise surgical processes to the patients' biomechanical problems must be determined.

The purpose of this study is to compare the deviation between the position of the osteotomies virtually planned and the position of the osteotomies made by means of the 3d printed surgical guides for a human cadaver foot.

**Methods:** A left cadaver foot was scanned by means of a CAT scan and, by means of software; a virtual surgery was carried out by positioning the cutting guides.

The virtual preoperative tomography was compared to the postoperative tomography and measurements were made during the CAT scans. The data were analyzed with a t test ( $\alpha=0,01$ ).

**Results:** The average differences of measurement between the osteotomies planned by computer and the osteotomies of the surgery were 0.0613 (99% CI: -0,42 -0,42).

**Conclusion:** The results showed that statistically there is no significant difference between virtual and post-surgical osteotomies.

**Keywords:** Surgical guide; Minimal-incision surgery; Percutaneous foot surgery

### Clinical Relevance (if basic Science Study)

The 3D-printed surgical glove could facilitate a fast, simple, and minimally invasive surgical technique. The use of this customized surgical glove should be considered to allow surgeons to preserve patient safety when performing bone osteotomies with precise correction of forefoot deformities.

### Introduction

The minimally invasive surgery of the foot is a method that allows carrying out surgery interventions through small incisions with a minimum anatomical damage [1]. Continuous radiation controls by means of intraoperative fluoroscopy are necessary since, as they are small incision, we do not visualize the surgical field, which creates further complications. The lack of sight or the lack of experience in the techniques themselves could injure important anatomical structures [2]. The new technologies as well as the progresses in medical image, result in the improvement of the traditional foot surgery techniques, introducing new forms of guidance to carry out such interventions. Nowadays, it is relatively simple to obtain a 3D reconstruction by means of DICOM images obtained through CAT scans/NMR and to rebuild them with specific software, obtaining a perfect image that we will be able to manipulate on the computer. Similar technology already exists in other areas like the dentists, where they place implants that have been planned and guided by computer [3], which avoids damaging significant structures surrounding the surgery. So far, pre-surgical planning was made by means of 2D X-rays and the convenient goniometry to quantify where and how much must the osteotomy be carried out. With three-dimensional planning, software like Mayan, 3D Max Studio or Mimics, 3D medical segmentation software [4], a virtual

### OPEN ACCESS

#### \*Correspondence:

Javier Ferrer-Torregrosa, Department of Podiatry, Physiotherapy and Podiatry School, Valencia Catholic University, Valencia, C/Ramiro de Maeztu 14, Torrente-Valencia 963637412, Spain, E-mail: javier.ferrer@ucv.es

Received Date: 01 Jun 2017

Accepted Date: 31 Jul 2017

Published Date: 07 Aug 2017

#### Citation:

Ferrer-Torregrosa J, Fernández-Ehrling N, Vicente SG, Barrios C. Surgical Guidance in Foot Surgery by Means of 3D Impression and Minimally Invasive Surgery. Clin Surg. 2017; 2: 1582.

**Copyright** © 2017 Ferrer-Torregrosa J. This is an open access article distributed under the Creative Commons Attribution License, which permits unrestricted use, distribution, and reproduction in any medium, provided the original work is properly cited.

**Table 1:** Measurements made and differences between them.

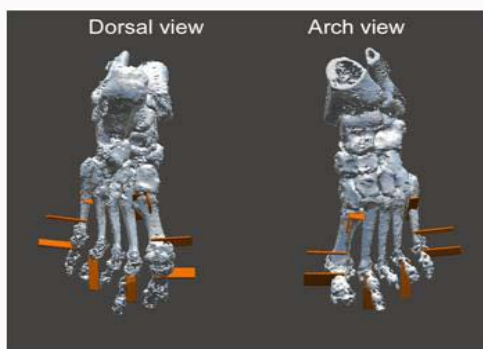
PRE-SURGICAL	2,14	2,29	2,39	1,93	2,01	3,27	2,19	0,98	4,01	1,92
POST-SURGICAL	2,12	2,34	2,34	1,61	2,43	3,18	2,13	1	3,59	1,9
DIFFERENCE	0,02	-0,05	0,05	0,32	-0,42	0,09	0,06	-0,02	0,42	0,02

**Table 2:** Statistics of related samples.


	Median	N	Standard deviation	Mean standard error
Pair 1 pre-	25,288	8	,72833	,25750
post-	24,675	8	,62923	,22247

**Table 3:** Correlation of related samples.

	N	Correlation	Sig.
Pair 1 pre and post	8	,942	,000



**Figure 1:** Osteotomy design.

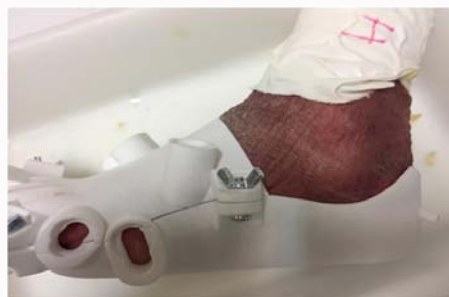

**Figure 2:** The surgical glove creation.

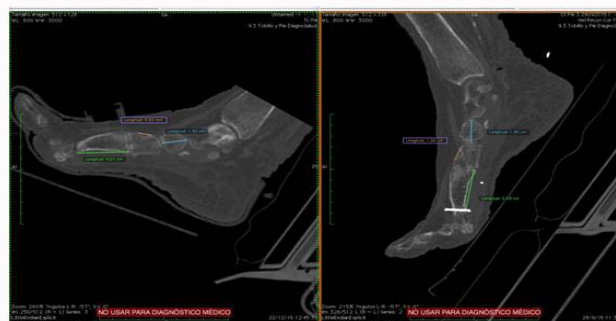planning can be carried out to subsequently send the surgical insole or the glove in this case to the manufacturing plant by means of rapid prototyping [5].

### Material and Methods

The first thing to do is to get a Computerized Axial Tomography scan (CAT) of the foot that needs to be operated; in this case it was a left foot. A reconstruction is carried out in a software of their own created by the company's Socinser (Asturias, Spain) and TEQUIR (Valencia, Spain), it is a software allowing the surgeon to work with medical image in 2D (from X-rays) and 3D (from CAT scans), to visualize in detail the osseous structure and to carry out virtual measurements, planning, simulations, of a surgery. Working on Web collaborative environment, making possible communication online in real time with one or more of the program users, is a process that allows a comprehensive treatment of complex cases, making possible the design and accomplishment of osteotomies along with the corresponding surgical guides, resulting from all the process followed and guaranteed by the surgeon, as a solution fully adapted



**Figure 3:** Glove printed in Polyamide 12.



**Figure 4:** Example of measurements.

to the specific case.

The surgery was planned with the software in the following osteotomies:

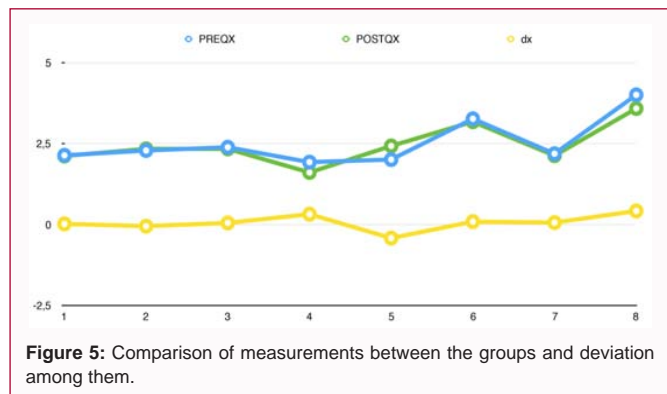
1. AKIN perpendicular to the axis of the phalanx of the 1<sup>st</sup> incomplete.
2. *Reverdin-isham*, is an osteotomy that preserves the lateral cortical.
3. Underlying osteotomy of the 1<sup>st</sup>.
4. Isham bunionette of the 5<sup>th</sup>.
5. Underlying osteotomy of the phalanx of the 2<sup>nd</sup>, 4<sup>th</sup> and 5<sup>th</sup>, all of them are incomplete.
6. Once the intervention was planned and the osteotomies were designed, the printing of the glove of the foot started with the osteotomies incorporated in the cover itself, using for this purpose the technology known as stereolithography of the AIMME Technological Institute which provides an excellent dimensional and superficial quality. Material such as PA 12 (polyamide 12) was used. This material supports perfectly autoclave, its melt point EN ISO 11357-1 is around 172°C – 180°C.
7. Once the glove was printed, the surgery of all the osteotomies established in the planning was carried out.

### Results and Discussion

To assess the results both CAT scans were synchronised, through Osirix Software, the pre-surgical one with the guides and the post-

**Table 4:** Test of related samples.

Pair 1	pre - post	Related differences				t	gl	Sig. (bilateral)	
		Median	Standard deviation	Mean standard error	99% Interval of confidence for the difference				
					Lowest				Highest
		,06125	,25136	,08887	-,24975	,37225	,689	7	,513



surgical one with the osteotomies carried out [6]. The 8 measurements below were made:

- From the most proximal part to the dorsal of the Akin osteotomy to the most proximal part of the Reverdin osteotomy.
- From the 1<sup>st</sup> metatarsal-cuneiform joint to the Reverdin osteotomy at the arch level.
- From the most proximal joint to the beginning of the guide at the pre-surgical and the osteotomy at the post-surgical.
- From the fat edge of the arch of the 5<sup>th</sup> finger to the beginning of the osteotomy at the dorsal level.
- From the styloid apophysis to the osteotomy of the 5<sup>th</sup> at the dorsal level.
- From the dorsal part of the proximal osteotomy of the 5<sup>th</sup> finger to the edge of the distal osteotomy of the 5<sup>th</sup> finger at the dorsal level and another one at the arch level.
- From the arch part of the distal osteotomy of 5<sup>th</sup> to the osteotomy of the 5<sup>th</sup> finger at the arch level.
- Two osseous measurements were also made to verify the existing deviation in the synchronisation of pre- and post-surgical, the deviation among them was less than 0.02.
- Dorsal cleft of the first cuneiform bone to make sure we are on the same plane.
- Measurement of navicular to make sure we are on the same plane.

All the measurements were made by another investigator different from the surgical one.

We can appreciate that on chart 1 there is almost no variation between the two measurements, statistically there is no difference between the sizes. If we analyze all the measurements we shall observe how the maximum deviation is less than < 0,42 mm, something fully reasonable in this kind of surgeries [7,8]. We made a T-student for

twin samples observing that there is a correlation very close to 1 and that statistically there are no significant differences with p-value = -0.513. On the chart, we can see how only three measurements, the 4, 5, 8 do deviate, while the rest is almost equal between both CAT scans.

### Conclusion

The results of this study clearly show that the surgical glove provides accuracy in the accomplishment of the osteotomies. The cutting guides are accurate and helpful tools for the podiatrist during minimally invasive surgery of the foot, as it was already demonstrated by Hetherington in 2008 with other guides for exposed surgery. It has also been proved in surgeries such as knee arthroplasty where more accurate cuttings were carried out. Nevertheless, there is not much information in literature about the use of osteotomy guides in podiatric surgery. The guides are very important for the osteotomies, especially for first metatarsal surgery. They must be considered for the treatment of deformities such as Hallux valgus and/or Taylor's bunion, to obtain the correct alignment of cutting and the angle, to recover the functional normality of the foot and to avoid possible side effects of the misalignment of the parts of the osteotomy. Further research is necessary on this subject and more types of surgical guides should be incorporated to establish a connection with the pre-surgical pressures emerged in consultation by means of simulation and trigonometry.

### References

1. Nieto-García E, Ferrer-Torregrosa J, Nieto-González E. Principios de la cirugía mínimamente invasiva. In: Cirugía Mínimamente Invasiva Del Pie. Valencia: Ediciones Glosa. 2017;297.
2. De Prado M. Complications in minimally invasive foot surgery. Fuß Sprunggelenk. 2013;11(2):83-94.
3. Pettersson A, Kero T, Gillot L, Cannas B, Fäldt J, Söderberg R, et al. Accuracy of CAD/CAM-guided surgical template implant surgery on human cadavers: Part I. J Prosthet Dent. 2010;103(6):334-42.
4. Zeng Y, Zhang G, Lei T, Wu X, Tan Y. [Clinical application of mimics software in three dimensional CT images for treatment of zygomatic complex fracture]. Hua Xi Kou Qiang Yi Xue Za Zhi. 2012;30(2):123-7.
5. Deshmukh TR, Kuthe AM, Vaibhav B. Preplanning and simulation of surgery using rapid modelling. J Med Eng Technol. 2010;34(4):291-4.
6. Hetherington VJ, Kawalec-Carroll JS, Melillo-Kroleski J, Jones T, Melillo M, McFarland N, et al. Evaluation of surgical experience and the use of an osteotomy guide on the apical angle of an Austin osteotomy. Foot (Edinb). 2008;18(3):159-64.
7. Teter KE, Bregman D, Colwell CW. Accuracy of intramedullary versus extramedullary tibial alignment cutting systems in total knee arthroplasty. Clin Orthop Relat Res. 1995;(321):106-10.
8. Teter KE, Bregman D, Colwell CW. The efficacy of intramedullary femoral alignment in total knee replacement. Clin Orthop Relat Res. 1995;(321):117-21.