



Surgical Debridement for Diabetic Foot Wounds

Nather A*, Wei Mae CC, Anwar A and Masturah S

Department of Orthopaedic Surgery, National University Hospital, Singapore

Abstract

Surgical debridement is the commonest operation performed for diabetic foot. It is often left behind to the most junior doctor. However, it needs experience to gauge the extent and depth of debridement needed. It is therefore important that an experienced surgeon should perform it. Good debridement is very often the key to success in the management of diabetic foot wounds.

Meticulous assessment must be done pre-operatively. The patient is first assessed for fitness to undergo anaesthesia. Thorough local evaluation of the foot is then performed to assess all 3 components of the Diabetic Foot Triad – vasculopathy, neuropathy, immunopathy.

Consent for operation must be carefully obtained. The chance of wound healing is discussed. The need for a repeat debridement or a further operation such as split skin graft must also be explained.

The operative procedure is described in detail. Debridement is best performed layer-by-layer to remove all devitalized tissue until healthy bleeding tissue is left behind. The wound is then flushed with normal saline and haemostasis secured.

It is best not to leave tendons, bones, fascia and joint capsule exposed.

Issues regarding debridement including the use of tourniquet versus no tourniquet, surgical blade versus cutting diathermy, and the use of conventional dressings versus negative pressure wound therapy are discussed.

Keywords: Surgical debridement; Diabetic foot wound

Introduction

Surgery for diabetic foot includes debridement, split skin grafting, minor amputation (including ray, transmetatarsal and Pirogoff amputation), major amputation (including below-knee, through-knee and above-knee amputation), and vascular bypass surgery [1]. Surgical debridement for a diabetic foot wound is the most common procedure performed for diabetic foot [2]. Often, this is left to the resident on duty to perform. However, this practice is not ideal. Proper debridement requires an experienced surgeon who will be able to excise devitalized tissue adequately. The inexperienced resident is often unable to quantify the extent of debridement needed. A repeat debridement is often necessary. The outcome for the patient will be better when it is performed by an experienced surgeon. Good debridement is indeed the key to success in managing diabetic foot ulcers.

While much has been written for surgery of the diabetic foot, very little has been described on surgical debridement. The objective of this article is to describe surgical debridement in detail – its indications and contraindications and the operative procedure involved. Issues pertaining to debridement, including the use of tourniquet versus no tourniquet, the use of surgical blade versus cutting diathermy and the use of conventional dressing versus negative pressure wound therapy are also discussed.

What is debridement?

Debridement is the excision of necrotic, devitalized or infected tissue from a wound, leaving healthy and vascular tissue behind [3]. Surgical debridement (using the scalpel) is the usual method used. It is necessary for optimal healing of the diabetic foot ulcer.

Types of debridement

There are many types of debridement (Table 1) [2]. This article is focused on surgical debridement using the scalpel. Mechanical debridement (including hydrosurgery and ultrasonic debridement) and biological debridement using maggots will not be discussed.

Surgical debridement can be done as a bedside procedure or in the operating room under

OPEN ACCESS

*Correspondence:

Aziz Nather, Department of Orthopaedic Surgery, National University Hospital, 1E Kent Ridge Road, NUHS Tower Block, Level 11, 119228, Singapore, Tel: +65 81266025;

E-mail: dosnathe@nus.edu.sg

Received Date: 12 May 2016

Accepted Date: 22 Jun 2016

Published Date: 24 Jun 2016

Citation:

Nather A, Wei Mae CC, Anwar A, Masturah S. Surgical Debridement for Diabetic Foot Wounds. *Clin Surg*. 2016; 1: 1040.

Copyright © 2016 Nather A. This is an open access article distributed under the Creative Commons Attribution License, which permits unrestricted use, distribution, and reproduction in any medium, provided the original work is properly cited.

Table 1: Types of debridement.

Type of Debridement	Description
Autolytic debridement	Using body's own enzymes and moisture with hydrocolloids, hydrogels and transparent films
Enzymatic debridement	Using chemical enzymes: collagenase, papain-urea
Mechanical debridement	Hydrosurgery, ultrasonic debridement
Surgical debridement	Using sharp surgical debridement/Hydrosurgery <ul style="list-style-type: none"> In the operating room Bedside debridement
Biological debridement	Maggot debridement therapy

general, regional or local anaesthesia (Table 1). The decision whether to perform at the bedside or in the operating room must be made by the clinician after assessment of the wound.

Why debride?

Devitalised (necrotic) tissue in the wound floor prevents clinicians from adequately assessing the depth and nature of the wound. Dead tissue acts as a medium for bacterial growth and increases the risk of infection [4]. Necrotic or devitalized tissue may obscure the wound bed and make assessment difficult. Dead tissue may act as a physical barrier to healing [5]. Bacterial colonies which are often present in necrotic tissue can produce proteases which break down important constituents of the extracellular matrix and have a negative effect on the formation of granulation tissue and re-epithelisation [6]. Bacteria form a biofilm for their own protection [7]. This is extracellular matrix and binds to the wound floor and may cause a resistance to antibiotics instituted. This biofilm must be debrided to allow the wound to heal [8]. In chronic wounds, the orderly sequence of events in acute wounds becomes disrupted or "stuck" at one or more of the different stages of wound healing. Debridement facilitates wound healing by converting this chronic wound into an acute wound [9].

It is therefore important to debride adequately to remove all necrotic and devitalized tissue. Recommendation 22 in the surgical section of ASEAN Plus Guidelines [10] reinforces this point. It states: "It is important to perform adequate debridement to remove all devitalized or infected tissue".

However, care must be taken to ensure that the patient has been assessed for anaesthetic risks and that the wound will be able to heal following debridement.

Assessment for debridement

Assessment is needed to decide whether debridement should be performed or not in the operating theatre. The assessment will also include the extent of debridement required and also whether a repeat debridement or other surgery is necessary later on.

The patient must first be assessed regarding the suitability for general or regional anaesthesia taking into account the comorbidities present in the patient with diabetic foot problems.

Local examination must be thoroughly performed. This must include evaluation of the foot and the wound for all three components of the Diabetic Foot Triad [11] (Figure 1). This includes: -

- Assessment for vasculopathy (pulses, capillary refill, ankle brachial index/ toe brachial index)
- Assessment for neuropathy (10-point Semmes Weinstein monofilament test)
- Assessment for immunopathy (ray-by-ray deep palpation for underlying osteomyelitis or septic arthritis)

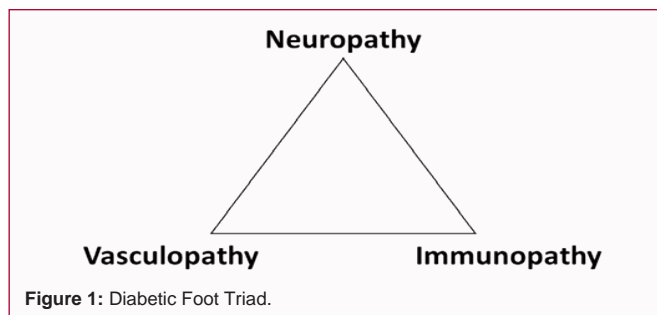


Figure 1: Diabetic Foot Triad.

Table 2: Markers of infection.

Markers	Normal values		
White Blood Count (WBC)	4,500 – 11,000 wbc/mcL		
C-Reactive Protein (CRP)	< 1.0 mg/L		
Erythrocyte Sedimentation Rate (ESR)	Gender	Female	Male
	< age 50	<20 mm/hr	<15 mm/hr
	> age 50	<30 mm/hr	<20 mm/hr

Table 3: Markers of healing.

Markers	Normal values	
HbA1C	<5.7%	
Haemoglobin (Hb)	Female:	Male:
	12.1 – 15.1 g/dL	13.8 – 17.2 g/dL
Total albumin	3.4 – 5.4 g/dL	
Creatinine (Cr)	Female:	Male:
	0.6 – 1.1 mg/dL	0.7 – 1.3 mg/dL

If tenderness is found over the metatarsal or the underlying joints painful on movement, the clinical suspicion of deep infection must be confirmed by performing plain radiographs of the foot [12].

If underlying osteomyelitis or septic arthritis is confirmed, debridement alone is inadequate. Ray amputation may be needed.

The wound must then be classified. The authors prefer the use of Wagner-Meggitt for wound classification [13,14].

Contraindications to debridement

Vascularity of the foot must be assessed before attempting a debridement. Debridement is contra-indicated if both foot pulses are not palpable, or if ankle brachial index is less than 0.6 [10]. The clinician should instead refer the case to a vascular surgeon before proceeding with debridement.

Markers of Infection

Markers of infection should be performed. These include white cell count, C-reactive protein and erythrocyte sedimentation rate (Table 2). Tissue from the bone should be sent for culture and sensitivity and blood culture performed as well. Tissue culture is far more accurate than swab from the wound.

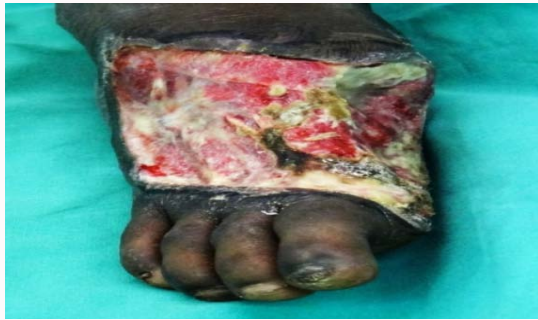

Figure 2: Dorsum of foot before debridement showing necrotic tissue and slough.

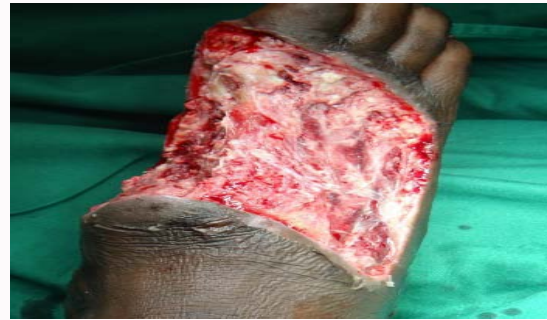

Figure 3: Wound of same patient after debridement. Healthy bleeding seen from tissue left behind.

Markers of healing

In addition to markers of infection, one should also perform markers of healing. These include HbA1C, haemoglobin, total albumin and Creatinine (Table 3). It is important to ensure that good endocrine control is obtained. Otherwise, despite debridement, the wound may not heal. The wound must also carry enough oxygen to provide energy for healing. For this, the haemoglobin should be more than 12.1g/dL. Enough proteins must also be provided. The total albumin in the patient should be more than 3.4g/dL. Renal impairment will also impair wound healing. The presence or absence of renal impairment should also be evaluated.

Consent for debridement

It is important to obtain proper and informed consent for the procedure. The chance of wound healing after debridement is discussed. The need for a repeat debridement or a further operation such as split skin graft must also be explained. One must also discuss with the patient the risk of losing the limb even if this is 5-10%.

Operative Procedure

Debridement is often performed using the surgical blade layer-by-layer starting with the skin, subcutaneous tissue, deep fascia, and muscle. The tissue in each layer is cut until healthy bleeding tissue is reached (Figure 2 and 3). Fascia should be excised and healthy bleeding muscle left behind. The vitality of the tissues left behind must always be ascertained. Next, haemostasis is secured using diathermy. The wound is then flushed with hydrogen peroxide. This provides a thermocoagulative effect. Flushing is then performed with normal saline using jet lavage. A four-corner biopsy of the wound is then performed. Tissues obtained from the biopsy are sent for culture and sensitivity. If the debridement is inadequate, the results of the four-corner biopsy can guide us as to the area of the wound that needs to be excised when the repeat debridement is performed.

The wound is then dressed using Tulle gras (TG) dressing. The paraffin has a sealing effect and reduces post-operative bleeding. A hemostatic dressing such as calcium alginate based dressing can also be used. Jones bandage is then applied to reduce post-operative bleeding.

“Sterile” Debridement Technique

The senior author performs the surgical debridement as a 2-step technique. In the first step, excision of all infected and devitalized tissues until pink and healthy bleeding tissue is seen. The wound is then flushed with 1-2litres of normal saline using jet lavage. The blade and forceps used are then discarded.

The surgeon and his assistant change their gloves. New blades and forceps are then used to perform the next step – a second debridement to remove more devitalized tissue to make sure that no infected tissue or bacteria is left behind. This is similar to the excision of the tissue bed left behind after the soft tissue tumour has been excised to ensure that no tumour cells are left behind in the bed. The author refers to this 2-step technique as “sterile” debridement technique to ensure complete excision of all infected tissue. The wound is then flushed with hydrogen peroxide followed by normal saline. A four-corner biopsy of the wound is also performed.

Pitfalls for Debridement

No exposed tendon should be left behind. Tendons left exposed without paratenon would not remain viable. Such a tendon will undergo necrosis unless it is covered by a flap or VAC therapy.

Likewise, fascia should also not be left behind. It will also become necrotic or sloughy. Exposed fascia should be excised until healthy bleeding muscle is left behind.

Bare bone must not be left exposed. They will become osteomyelitic. Debridement must not expose the capsule of joint (metatarsophalangeal joint). It will lead to septic arthritis of the joint. Bone and joint left exposed must be covered by a flap or VAC therapy.

Tourniquet versus No Tourniquet

The use of tourniquet in debridement remains controversial. Some surgeons including orthopaedic surgeons prefer not to use tourniquet in performing debridement. The tourniquet is applied but is not pumped. This is useful as a safety net to prevent extensive blood loss [15]. The advantage of not using tourniquet is that without tourniquet, the bleeding occurring in the healthy tissue left behind can be seen. It is easier to assess adequacy of debridement performed. The disadvantage of not using tourniquet is that the amount of bleeding occurring is sometimes too much. When this happens, the tourniquet applied and not pumped must then be pumped.

Other surgeons including hand and plastic surgeons prefer to apply and pump the tourniquet before debridement. This provides better visualization of tissue without too much bleeding clouding the vision of the tissues debrided.

With or without the tourniquet pumped, at the end of debridement, the tourniquet must be released. The vitality of the tissue left behind must be evaluated by the bleeding of healthy tissue. Haemostasis must then be secured using diathermy.

Surgical Blade versus Cutting Diathermy

Some surgeons including orthopaedic surgeons prefer to use the surgical blade for debridement with the scalpel. More bleeding will occur. One must be careful to secure haemostasis after debridement to avoid too much blood loss.

Other surgeons including hand and plastic surgeons prefer the use of cutting diathermy. This reduces the amount of bleeding from debridement. This is especially useful when debriding large wounds (e.g. wounds in necrotising fasciitis).

Conventional Dressings versus NPWT

After debridement, conventional dressings can be applied. This includes Tulle gras or a haemostatic dressing such as a calcium alginate dressing. Jones bandage is then added. Such dressings minimize post-operative bleeding.

Some surgeons prefer to apply negative pressure wound therapy (NPWT) immediately following the debridement in the operating room. NPWT can only be used if haemostasis is well secured. A lower pressure of 80mmHg is preferred instead of the usual 120mmHg. In addition, the drainage in canister must be monitored carefully. Safe post-operative instructions and precautions must be left behind. If drainage is more than 100ml, the negative pressure must be clamped and the surgeon informed. This is to stop the excessive bleeding that often occurs when VAC dressing is applied immediately following debridement.

The authors recommend using conventional dressings in the operating room instead of NPWT. This is to prevent excessive post-operative bleeding. NPWT can be applied on the second or third post-operative day after ensuring that no more bleeding has occurred from the operative wound.

Role of Split Thickness Skin Graft (SSG)

Unlike smaller wounds, which heal via secondary closure, large wounds require split skin grafting [16]. Donor skin for SSG is usually taken from thigh of the patient on the same limb. Once the wound bed preparation is complete with two consecutive negative cultures, the wound is ready for SSG.

References

- Nather A, editor. Surgery for diabetic foot: a practical operative manual. New Jersey: World Scientific. 2016.
- Nather A, Anwar A, Masturah S. Surgical debridement. In: Nather A, editor. Surgery for diabetic foot: a practical operative manual. New Jersey: World Scientific. 2016; 93-106.
- Dorland's illustrated medical dictionary. 31st ed. Philadelphia: Saunders; 2007. Surgical debridement.
- Leaper D. Sharp technique for wound debridement. World Wide Wounds. 2002.
- O'Brien M. Exploring methods of wound debridement. Br J Community Nurs. 2002.
- Weir D, Scarborough P, Niezgodka JA. Wound debridement. In: Krasner D, Rodeheaver GT, Sibbald RG, editors. Chronic Wound Care: A Clinical Source Book for Healthcare Professionals. 4th ed. Pennsylvania: HMP Communications; 2008.
- Lebeaux D, Ghigo JM, Beloin C. Biofilm-related infections: Bridging the gap between clinical management and fundamental aspects of recalcitrance toward antibiotics. Microbiol Mol Biol Rev. 2014; 78: 510-543.
- Roy S, Elgharably H, Sinha M, Ganesh K, Chaney S, Mann E, et al. Mixed-species biofilm compromises wound healing by disrupting epidermal barrier function. J Pathol. 2014; 233: 331-343.
- Schultz GS, Sibbald RG, Falanga V, Ayello EA, Dowsett C, Harding K, et al. Wound bed preparation: a systematic approach to wound management. Wound Repair Regen. 2003; 11: S1-28.
- Nather A, Soegondo S, Adam JMF, Nair HKR, Zulkifly AH, Villa MAA, et al. Best practice guidelines for ASEANplus: Management of diabetic foot wounds. Sri Lanka Journal of Diabetes Endocrinology and Metabolism. 2015; 5: 1-37.
- Nather A, Lim A. Pathogenesis. In: Nather A, editor. The diabetic foot. New Jersey: World Scientific; 2012; 83-88.
- Nather A, Teo RYL. Investigations. In: Nather A, editor. Surgery for diabetic foot: a practical operative manual. New Jersey: World Scientific; 2016. p. 51-66.
- Meggitt B. Surgical management of the diabetic foot. Brit J of Hosp Med. 1976; 16: 227-232.
- Wagner FW Jr. The dysvascular foot: a system for diagnosis and treatment. Foot Ankle. 1981; 2: 64-122.
- Sharma JP, Salhotra R. Tourniquets in orthopedic surgery. Indian J Orthop. 2012; 46: 377-383.
- Nather A, Tan TF. Split skin grafting. In: Nather A, editor. Surgery for diabetic foot: a practical operative manual. New Jersey: World Scientific; 2016. p. 107-128.