



Successful Thoracoscopic Correction of Post-bypass Coronary Steal Syndrome as a Cause of Postoperative Angina: Case Report

Luis G García-Herreros, Luis Alberto Chinchilla, Diego F Salcedo*, Andrea Suarez Gómez and Julio César Granada

Department of Thoracic Surgery, Fundacion Santa Fe de Bogota University Hospital, Universidad El Bosque, Colombia

Abstract

Post-bypass coronary steal syndrome a significant etiology of postoperative angina. We present the of a 65-year-old patient with a history of medicated coronary stent followed by internal mammary artery bypass towards the anterior descending artery using a native vessel competing for blood flow with a lateral costal artery with postoperative angina. We treated our patient successfully with VATS approach and using thoracoscopic ligation with successful resolution of postoperative angina.

Keywords: Angina; Coronary artery bypass; Left internal mammary artery graft; Coronary steal syndrome; Mammary arteries; Subclavian steal syndrome; Lateral costal artery

Introduction

Coronary revascularization using the left internal mammary artery is the preferred management option in many coronary disease patients with significant obstruction of the anterior descending artery [1-3]. Patients have been reported to develop angina during the postoperative period of internal mammary coronary bypass surgery, and one of the causes for these symptoms is coronary steal syndrome [4,5]. The main causes of coronary steal syndrome are subclavian artery stenosis [6] and the presence of internal mammary artery branches such as the costal lateral artery, redirecting blood flow from the internal mammary artery and the coronary anastomosis towards these accessory branches, causing repercussions on myocardial perfusion and postoperative angina [7]. We present the case of a patient with internal mammary artery coronary bypass towards the anterior descending artery using a native vessel competing for blood flow with a lateral costal artery, which is anastomosed with large intercostal vessels causing postoperative angina on the patient. Cases of coronary steal syndrome redirecting flow from the internal mammary artery to the lateral costal artery with postoperative angina have been reported. However, we are reporting a case of thoracoscopic correction successfully and safely.

Case Presentation

We present the case of a 65-year-old patient with a history of myocardial revascularization via bypass using the mammary artery 2 years before consultation, in addition to several angina episodes since the initial surgical intervention. Stents with medication were required at the circumflex on the trunk of the second marginal branch. The patient was admitted at the emergency room service with typical thoracic pain. No alterations were observed regarding vital signs, there was no dyspnea, cardiac and lung auscultation were normal. EKG showed right branch block and cardiac enzymes were negative. Coronary arteriography was performed as a complementary study to establish the cause for this symptom. It showed severe obstruction of the anterior descending artery at the medial segment and distal flow competition. In addition to a circumflex artery with stenting at the trunk of the second marginal branch without evidence of re-stenosis. The obtuse marginal artery emerging at the stent site showed obstruction at the site of origin and the internal mammary bypass towards the anterior descending artery with a native vessel competing with a lateral costal artery and is anastomosed to large intercostal vessels. The right coronary artery did not show pathological alterations.

An Angio-CT scan was selected for the study of the features of the lateral costal artery (Figure 1), showing a lateral costal artery at 11 millimeters from the origin of the internal mammary

OPEN ACCESS

*Correspondence:

Diego Fernando Salcedo, Department of Thoracic Surgery, Fundacion Santa Fe de Bogota University Hospital, Universidad El Bosque, Carrera 7 No, 117-15 Bogotá, 110111, Colombia, Tel: +57-6575714; +57-3008102795; E-mail: dsalcedo_ub@hotmail.com

Received Date: 05 May 2021

Accepted Date: 07 Jun 2021

Published Date: 10 Jun 2021

Citation:

García-Herreros LG, Chinchilla LA, Salcedo DF, Gómez AS, Granada JC. Successful Thoracoscopic Correction of Post-bypass Coronary Steal Syndrome as a Cause of Postoperative Angina: Case Report. Clin Surg. 2021; 6: 3203.

Copyright © 2021 Diego F Salcedo.

This is an open access article distributed under the Creative Commons Attribution License, which permits unrestricted use, distribution, and reproduction in any medium, provided the original work is properly cited.

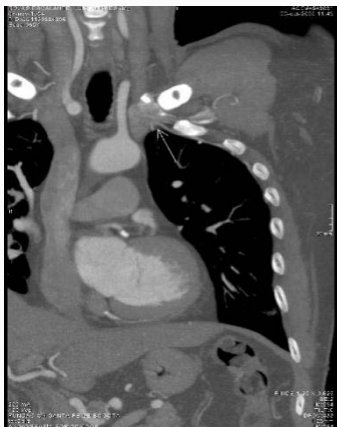

Figure 1: Origin of the lateral costal artery (Angiotomography).

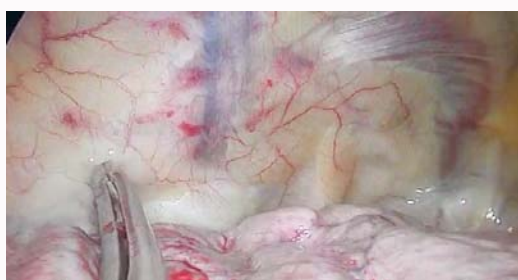

Figure 2: Intra thoracic anatomy of the origin of the lateral costal artery before thoracoscopic ligation.

artery, below the innominate vein, towards the thorax, between the clavicle and the first intercostal space. Given the features of this artery (Figure 2) and due to the high risk of occlusion of the internal mammary artery, it was decided that percutaneous management was not indicated in this patient, and so VATS ensued. A video assisted proximal ligation was performed close to the origin of the lateral costal artery using the Maryland technique, the vessel was occluded (Figure 3), a thoracic drain was placed for 24 h after the procedure and was later removed. Symptoms of angina improved considerably.

Discussion

The lateral costal artery is a branch of the internal mammary artery that descends upon the internal side of the upper ribs [8]. It is considered to be a supernumerary artery which causes coronary steal syndrome [9]. It is a small caliber artery, which originates branches off close to the first rib. This artery is present in 25% to 30% of the patient population with mammary bypass surgery, emerging as a branch of the internal mammary artery in 92% of these patients [8]. It may appear as a branch of the subclavian or the great intercostal artery [10]. A bilateral origin is reported in 5.5% to 10% of the patients [11]. The origin of the lateral costal artery is located approximately 2.3 cm of the internal mammary artery on the right side and 2.9 cm from the left side, though these may vary [11]. The artery follows its course through the internal side of the rib cage from its origin beneath the endothoracic fascia, descends across the anterior axillary line towards the fourth and sixth ribs, parallel to the lateral thoracic vessels, anterior and posterior intercostal branches emerging in each intercostal space [10].

Myocardial revascularization using left internal mammary artery has factors that may cause angina and coronary steal syndrome

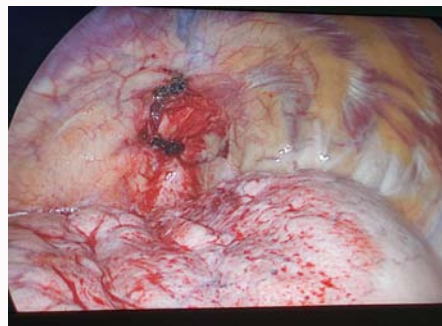


Figure 3: Thoracoscopic ligation of the lateral costal artery.

in patients during the postoperative period. Non-ligated lateral branches are a predisposing factor for postoperative angina [4]. It has been associated to ischemia; vessel length and thickness have shown a direct association with coronary steal syndrome [12]. Ligation of this inconsistent vessel is the management option of choice for these patients, and in most cases are taken to endovascular management [5]. A patient who required a new angioplasty with incidental occlusion of the lateral thoracic artery with successful management of symptoms was reported in the literature review [8].

There is no standard for the diameter and length of internal mammary artery branches at which coronary steal syndrome occurs. However, a length greater than 11 cm and a 1.3 mm diameter was associated with a sensitivity rate of 95.8% and a specificity rate of 100% for myocardial wall ischemia during a stress test [12].

A significant improvement of symptoms was achieved in patients in whom a complete closure of the lateral costal artery *via* endovascular approach in a case report series by Barouni et al. [13] showing an improvement in 5 patients taken to endovascular occlusion. However, the two patients in whom vascular control was not achieved continued to show symptoms.

Regarding surgical management, this lesion is uncommon. Three cases reported in the literature were taken to open surgery with extrapleural ligation at the second intercostal space [14-16]. A case of coronary steal syndrome by a lateral thoracic artery managed with occlusion endovascular coils was reported, and presented a symptomatic recurrence with documented persistent, permeable lateral thoracic artery. Reintervention was carried out using video assisted thoracoscopy and 4 months follow up reported no symptoms [17].

Coronary steal syndrome is an uncommon condition. However, several patients have been reported in the literature with coronary steal secondary to non-ligation of the lateral thoracic artery. Endovascular management has been successful in many patients with this condition and thoracoscopic ligation has also been used as a rescue procedure, even though it is not standardized [4].

Management with thoracoscopic approach is a safe intervention. In our case, symptomatic control was achieved and the hospital stay was brief and free of complications. We consider that thoracoscopic management may be indicated in patients with high risk of obstruction of the internal mammary artery due to the anatomical features of the lateral costal artery. However, this syndrome neither is nor frequent and recommendations with an adequate level of evidence cannot be issued. These patients must be undergo integral assessment in order to effectively achieve proper control of symptoms we treated our

patient successfully with VATS approach and using thoracoscopic ligation with successful resolution of postoperative angina.

References

1. Chang AM, Fischman DL, Hollander JE. Evaluation of chest pain and acute coronary syndromes. *Cardiol Clin.* 2018;36(1):1-12.
2. Xu J, Murphy SL, Kochanek KD, Arias E. Mortality in the United States. *Bost Med Surg J.* 1840;22(3):46-7.
3. Caliskan E, de Souza DR, Böning A, Liakopoulos OJ, Choi YH, Pepper J, et al. Saphenous vein grafts in contemporary coronary artery bypass graft surgery. *Nat Rev Cardiol.* 2020;17(3):155-69.
4. Kahraman S, Agac MT, Demirci G, Gurbak I, Panc C, Yildiz M, et al. Successful percutaneous treatment of coronary steal syndrome with the amplatzer vascular plug 4 and coil embolization. *Intractable Rare Dis Res.* 2018;7(4):287-90.
5. Mangels D, Penny W, Reeves R. Left internal mammary artery side branch intervention in the management of coronary steal syndrome following coronary artery bypass grafting. *Catheter Cardiovasc Interv.* 2021;97(1):97-104.
6. Berenguer Jofresa A, Marín Ortuño F, de España F, Ruiz Nodar JM, Navarrete CO, Mainar Tello V. Angioplastia transluminal percutánea en pacientes con estenosis de la arteria subclavia e injertos de arteria mamaria. *Rev Esp Cardiol.* 2002;55(5):537-40.
7. Singh RN, Sosa JA. Internal mammary artery-coronary artery anastomosis. Influence of the side branches on surgical result. *J Thorac Cardiovasc Surg.* 1981;82(6):909-14.
8. Vural Ü, Aglar AA, Sahin S, Kizilay M. Lateral costal artery: Clinical importance of an accessory thoracic artery. *Brazilian J Cardiovasc Surg.* 2018;33(6):626-30.
9. Barberini F, Cavallini A, Carpino G, Correr S, Brunone F. Lateral costal artery: Accessory thoracic vessel of clinical interest. *Clin Anat.* 2004;17(3):218-26.
10. Hartman AR, Mawulawde KI, Dervan JP, Anagnostopoulos CE. Myocardial revascularization with the lateral costal artery. *Ann Thorac Surg.* 1990;49(5):816-8.
11. Odo Y, Iwanaga J, Tabira Y, Watanabe K, Saga T, Shane Tubbs R, et al. Bilateral lateral costal branches of the internal thoracic arteries: A case report. *Kurume Med J.* 2018;65(3):105-8.
12. Beton O, Kaya H, Kandemir O, Alibazoglu B, Alibazoglu H, Karabey E, et al. The value of exercise SPET for the detection of coronary artery steal syndrome secondary to unlighted major side branch of left internal mammary artery. *Hell J Nucl Med.* 2016;19(3):200-7.
13. Sbarouni E, Corr L, Fenech A. Microcoil embolization of large intercostal branches of internal mammary artery grafts. *Cathet Cardiovasc Diagn.* 1994;31(4):334-6.
14. Mastroroberto P, Chello M, Zofrea S, Ceravolo R, Perticone F. Side-branch of internal mammary artery bypass graft causing coronary steal. *SAGE.* 1998;6(3):219-20.
15. Hijazi A, Mazhar R, Odeh S, Qunnaby I. Coronary steal through anomalous internal mammary artery graft. Treated by ligation without sternotomy. *Tex Heart Inst J.* 1996;23(3):226-8.
16. Tsakiridis K, Mikroulis D, Didilis V, Bougioukas G. Internal thoracic artery side branch ligation for post coronary surgery ischemia. *Asian Cardiovasc Thorac Ann.* 2007;15(4):339-41.
17. Pagni S, Bousamra M, Shirley MW, Spence PA. Successful VATS ligation of a large anomalous branch producing IMA steal syndrome after MIDCAB. *Ann Thorac Surg.* 2001;71(5):1681-2.