



Successful Repair with Aorto-Patch Plasty for Supra-Valvular Aortic Stenosis

Eyupserhat Calik, Umit Arslan and Bilgehan Erkut*

Department of Cardiovascular Surgery, Atatürk University, Turkey

Keywords

Supravalvular aortic stenosis; Aortic disease; Surgical therapy

Clinical Image

Supra-valvular aortic stenosis is a rare congenital disease that characterized by narrowing above the sinotubular junction, and causes left ventricle hypertrophy. A 12-year-old boy was admitted to our clinic with exercise intolerance, angina, and syncope complaints and with the diagnosis of supravalvular aortic stenosis. Left ventricle was enlarged in telecardiogram; there had been electrocardiographic findings of left ventricle hypertrophy. Mean pressure gradient was 70 mmHg and maximum gradient 112 mmHg in cardiac catheterization. We successfully treated a traditional diamond shaped patch aortoplasty was used to relieve supra-valvular aortic stenosis. Pressure gradients were almost disappeared postoperatively with good surgical result. He was discharged after 9 days.

Many different surgical techniques have been developed to correct supravalvular aortic stenosis as diamond-shaped and pantaloony-shaped patch techniques, single-patch augmentation of the non-coronary sinus, extended aortoplasty of the non-coronary and right coronary sinuses using a pantaloony patch, a three-patch repair of all three aortic sinuses [1,2]. These techniques provides symmetric reconstruction of the aorta with good postoperative results and no gradient across aortic valve and aortic valve insufficiency remains, providing excellent long-term relief of localized supravalvular gradients and preservation of aortic valve competence [3].

OPEN ACCESS

*Correspondence:

Bilgehan Erkut, Department of Cardiovascular Surgery, Atatürk University, Erzurum, Turkey, Tel: 00905337451006;

E-mail: bilgehanerkut@yahoo.com

Received Date: 15 May 2018

Accepted Date: 25 May 2018

Published Date: 06 Jun 2018

Citation:

Calik E, Arslan U, Erkut B. Successful Repair with Aorto-Patch Plasty for Supra-Valvular Aortic Stenosis. Clin Surg. 2018; 3: 1983.

Copyright © 2018 Bilgehan Erkut. This is an open access article distributed under the Creative Commons Attribution License, which permits unrestricted use, distribution, and reproduction in any medium, provided the original work is properly cited.

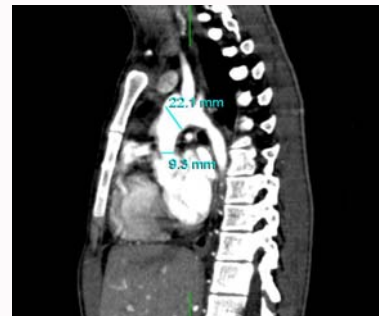

Figure 1: Multiplanar reconstruction image shows the diffusely stenosed ascending aorta in computed tomographic angiograms.

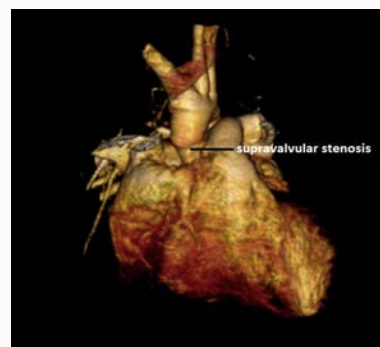


Figure 2: CT angiogram with 3D reconstruction showing the supravalvular aortic stenosis.

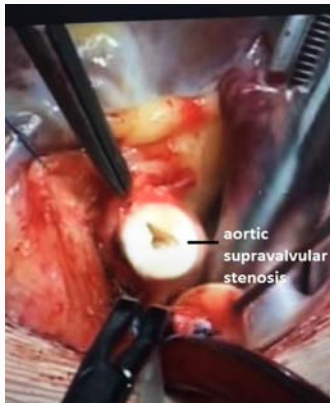

Figure 3: Supravalvular aortic stenosis during resection in operation.

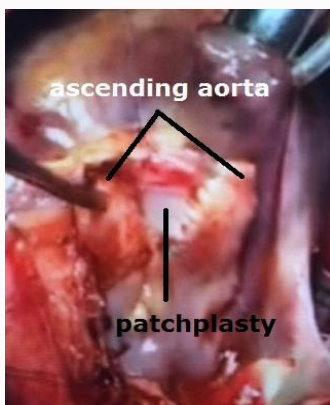

Figure 4: Image during operation of diamond shaped patch aorto-plasty with pericardial patch.

References

1. Thistlethwaite PA, Madani MM, Kriett JM, Milhoan K, Jamieson SW. Surgical management of congenital obstruction of the left main coronary artery with supravalvular aortic stenosis. *J Thorac Cardiovasc Surg.* 2000;120(6):1040-6.
2. McElhinney DB, Petrossian E, Tworetzky W, Silverman NH, Hanley FL. Issues and outcomes in the management of supravalvar aortic stenosis. *Ann Thorac Surg.* 2000;69(2):562-7.
3. Mongé MC, Eltayeb OM, Costello JM, Johnson JT, Popescu AR, Rigsby CK, et al. Brom Aortoplasty for Supravalvular Aortic Stenosis. *World J Pediatric Congenital Heart Surg.* 2018;9(2):139-46.