



# Subungual Ganglion Cyst Mimicking Glomus Tumor: A Case Report

Su Rak Eo\*, Gyeong Hyeon Doh, Hea Kyeong Shin, Kyung Chan Ahn, Ki Yong Hong and Yea Sik Han

Department of Plastic and Reconstructive Surgery, DongGuk University School of Medicine, South Korea

## Abstract

Subungual masses accompanying nail deformity are of common occurrence and uniquely confirmed by histopathologic examination postoperatively. Although glomus tumor is most frequently diagnosed with its specific clinical trial, other rarer diagnoses have also been reported. Though ganglion cysts are predominantly found around the distal phalangeal joint as a mucous cyst and myxoid cyst, they might also appear as a subungual mass accompanied by nail deformity thereby mimicking the glomus tumor. A 54-year-old woman visited our outpatient clinic with nail deformity and pain on the tip of the right thumb. She had a history of nail root injury on her right thumb which occurred 3 months back at a nail shop. Physical examination revealed a convex point with tenderness on the right thumbnail. Doppler ultrasonography revealed the presence of 0.43 mm × 0.26 mm × 0.53 mm sized non-specific cystic lesion with hypoechogenicity and no abnormal vascularity. Complete excision of the cyst was performed and biopsy and histopathology revealed a ganglion cyst. Subungual ganglion cyst is of rare occurrence and known to be usually asymptomatic. Herein, we report a case of ganglion cyst of subungual area which was mistakenly diagnosed as a glomus tumor preoperatively.

**Keywords:** Ganglion cyst; Glomus tumor; Subungual tumor

## Introduction

Space occupying lesion at the subungual area is commonly diagnosed as a glomus tumor which accounts for 1% ~ 5% of soft tissue tumors of the hand and 75% of glomus tumors are subungual [1,2]. The clinical trial of point tenderness, intermittent severe pain, and cold hypersensitivity accounts for preoperative easy diagnosis. However, ganglion cyst at the distal phalangeal joint which is known as mucous cyst occasionally grows up infrequently into the subungual area and mimics the clinical course of the glomus tumor [3,4]. Although cold intolerance is unique in glomus tumor, nail deformities and sharp tenderness are frequently accompanied in both the cases. The authors encountered a subungual ganglion cyst, which was erroneously diagnosed preoperatively for glomus tumor and compared both the lesions systemically with the literature review.

## Case Presentation

A 54-year-old woman visited our outpatient clinic with nail deformity and pain at the tip of the right thumb. She underwent mild injury on her nail root of right thumb at a nail shop 3 months back. Subsequently, nail deformity aggravated gradually. Physical examination revealed a convex point with tenderness on the right thumbnail. The nail revealed proximal ridging and elevation of the nail plate accompanying the V-shaped notch without nail destruction (Figure 1). Cold hypersensitivity was denied and ice cube test was negative. However, a soft tissue tumor was suspected at the subungual area, which occurs most commonly in glomus tumors and other possible space-occupying lesions. Osteophyte of distal interphalangeal joint was found on X-ray examination (Figure 2). On Doppler ultrasonography, a 0.43 mm × 0.26 mm × 0.53 mm sized non-specific cystic lesion with hypoechogenicity and no abnormal vascularity was observed (Figure 3). Examination revealed 5 mm × 5 mm, whitish, and round shaped cyst after complete excision of the lesion (Figure 4 and 5), which was unlike the glomus tumor. The cyst had thin wall and contained clear mucinous fluid of jelly-like consistency. The incised portion of the nail bed was loosely re-approximated with 7-0 vicryl and the nail plate was replaced and sutured in place. For removal of osteophyte, burring was performed at middle and distal phalanx at PIP joint level. Pathologically, tissue biopsy revealed a ganglion cyst (Figure 6). Seventeen days later, total stitch out was done without any complications on her right thumb. Following surgical treatment, there was no recurrence and normal nail

## OPEN ACCESS

### \*Correspondence:

Su Rak Eo, Department of Plastic and Reconstructive Surgery, DongGuk University Medical Center, Dongguk-ro 27, IISandong-gu, Goyang-si, Gyeonggi-do, 10326, South Korea, Tel: 82-31-961-7342; Fax: 82-31-961-7347; E-mail: surakeo@yahoo.com

**Received Date:** 28 Nov 2019

**Accepted Date:** 13 Dec 2019

**Published Date:** 17 Dec 2019

### Citation:

Eo SR, Doh GH, Shin HK, Ahn KC, Hong KY, Han YS. Subungual Ganglion Cyst Mimicking Glomus Tumor: A Case Report. *Clin Surg*. 2019; 4: 2684.

**Copyright** © 2019 Su Rak Eo. This is an open access article distributed under the Creative Commons Attribution License, which permits unrestricted use, distribution, and reproduction in any medium, provided the original work is properly cited.

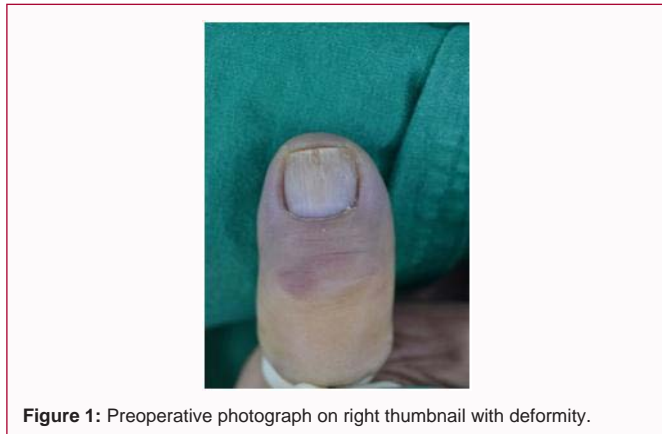

Figure 1: Preoperative photograph on right thumbnail with deformity.

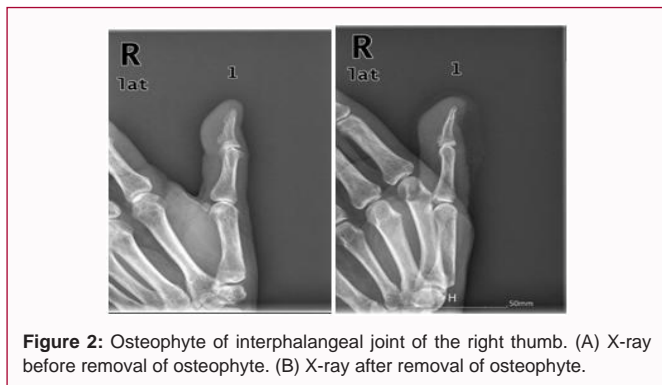


Figure 2: Osteophyte of interphalangeal joint of the right thumb. (A) X-ray before removal of osteophyte. (B) X-ray after removal of osteophyte.

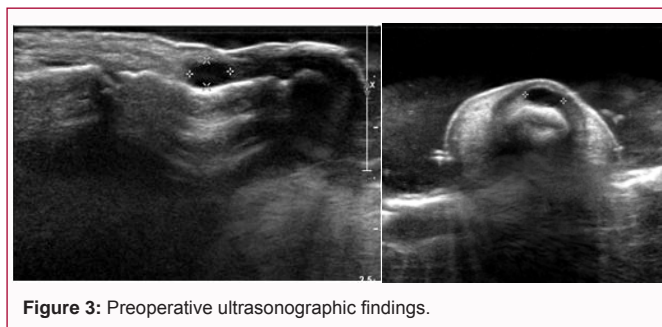


Figure 3: Preoperative ultrasonographic findings.

appearance was noted during the follow-up of 2 years.

### Discussion

A variety of subungual masses have been diagnosed as a myxoid cyst [3], hemangioma [5], fibroma, neurofibroma, neuroma [6], schwannoma, keratoacanthoma [8], onychomatricoma, squamous cell carcinoma, and malignant melanoma. Among them, malignant tumors are seldom truly subungual and easily differentiated from benign tumors based on external appearances. Ulceration through the nail, bluish color change, and destruction of the adjacent tissues raised the possibility of the malignancy. However, clinical manifestation of the subungual mass is often nonspecific, and accurate diagnosis is always dependent on postoperative histopathologic examination. Subungual Ganglion Cysts (SGC) affecting only the nail shape are distinctly unusual and difficult to diagnose, as they are unlikely to display mucoid discharge [3,4]. Although de Becker et al. [3] reported large series of SGCs exhibiting red lunula, altered transverse nail curvature, and variable nail destruction, many of them seemed to accompany the external distortion around the Distal Interphalangeal (DIP) joint. Consequently, subungual mass is usually considered to

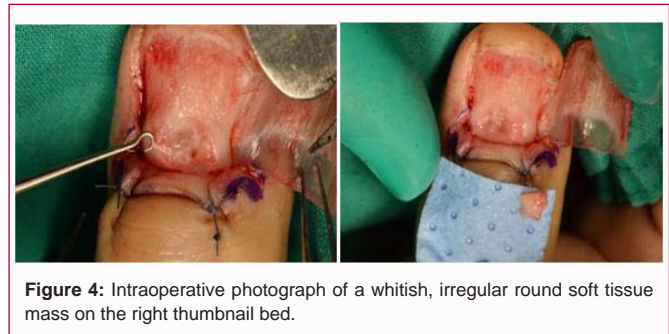


Figure 4: Intraoperative photograph of a whitish, irregular round soft tissue mass on the right thumbnail bed.

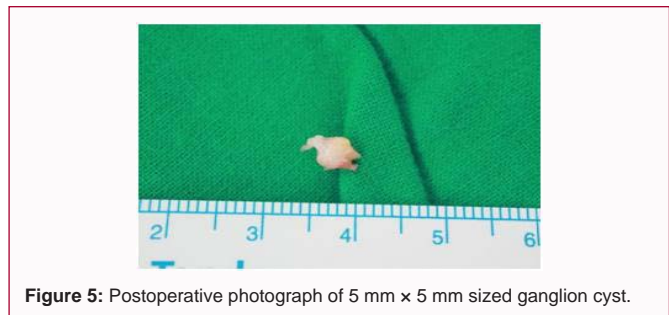


Figure 5: Postoperative photograph of 5 mm x 5 mm sized ganglion cyst.

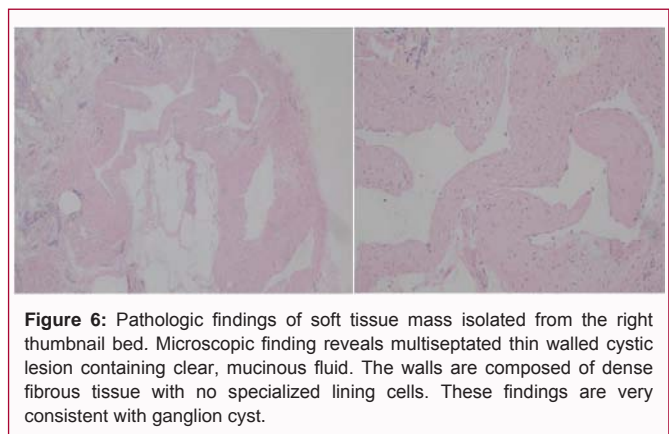


Figure 6: Pathologic findings of soft tissue mass isolated from the right thumbnail bed. Microscopic finding reveals multiseptated thin walled cystic lesion containing clear, mucinous fluid. The walls are composed of dense fibrous tissue with no specialized lining cells. These findings are very consistent with ganglion cyst.

be the glomus tumor with its predominant occurrence at its specific location under the nail. Furthermore, the authors esteemed the present case as a glomus tumor based on physical examination accompanied by pain and blunt tenderness while cold intolerance was not eminent. SGC has somewhat different clinical features from that of the mucoid cyst arising from the DIP joint which usually accompanies definitive erythematous swelling and ulceration at the dorsum of the DIP joint [9]. Contrary to the glomus tumor, in the present case, X-ray revealed osteophyte at the DIP joint preoperatively (Figure 2) and focal hypoechoic masses on the ultrasonogram, thereby suggesting subungual mucinous lesions (Figure 3).

Ultrasonographic characteristics of cystic, echogenicity and vascularity are helpful for the differentiation of subungual tumors [5]. Hemangioma shows well-defined and hypoechoic mass and pyogenic granuloma reveals more echogenicity with small hypoechoic foci. In case of subungual epidermal cyst [9], hypoechoic or anechoic subungual masses with variable echogenic foci are noted. However, differentiating them is always not possible solely based on US characteristics due to non-specific findings. Magnetic Resonance Imaging (MRI) is an excellent imaging modality for detecting small subungual mass as small as 2 mm [10]. SGC reveals a hyperintense mass on T2-weighted imaging with well-defined margins and typically

a nonenhancing center with higher specificity. SGC is variously named as a subungual myxoid cyst, digital mucous cyst, mucinous cyst, myxomatous degeneration cyst, and epidermal cyst. It represents ganglia of the adjacent DIP joint, which originates due to leakage of the fluid from the joint into the surrounding tissues. Osteophytes and degenerated, rough articular surfaces may lead to inciting damage to the joint capsule. A fluid-filled stalk may or may not be seen connecting ganglion cyst to the adjacent joint [11]. However, Tomoda et al. [12] reported the case of ulcerating subungual myxoid cyst, caused by overproduction of mucopolysaccharides and differentiated it from the SGC based on lack of connections with joint sacs. Considering that the subungual space is a very thin area with 1 mm to 2 mm thickness and rich in glomus bodies and blood vessels with compact innervation, bony erosions are also very common with its pressure effect. Within the limited submatrix space, proximal upward pressure from the subungual mass and the tethering downward force of the lateral proximal attachments of the matrix can cause various nail deformities [13]. Space occupying lesion under the nail matrix could affect its microvasculature resulting in various nail deformities based on the degree of distortion of the nail matrix. Color of the lunula, nail curvature, and nail integrity might change and reveal ridge, distal split, and superficial longitudinal split. Brown et al. [9] traced long-term nail change and growth patterns subsequent to various treatments. They surgically approached with T- or H-incisions to expose the DIP joint. However, in the present case, nail was removed with the standard subungual approach. Surgical excision is the typical existing treatment and removal of the osteophyte from the region of the distal interphalangeal joint as well as the cyst is imperative [3]. We propose that hand surgeons should perform differential diagnosis of subungual masses including SGC with reference to symptoms and appropriate diagnostic imaging studies preoperatively, though usual consideration of subungual mass as a glomus tumor. We believe that present findings will aid in precise excision with an aim to reduce the chances of recurrence of SGC.

## References

1. Morey VM, Garg B, Kotwal PP. Glomus tumours of the hand: Review of literature. *J Clin Orthop Trauma*. 2016;7(4):286-91.
2. Chiang YP, Hus CY, Lien WC, Chang YJ. Ultrasonographic appearance of subungual glomus tumors. *J Clin Ultrasound*. 2014;42:336-40.
3. de Berker D, Goettman S, Baran R. Subungual myxoid cysts: clinical manifestations and response to therapy. *J Am Acad Dermatol*. 2002;46:394-8.
4. Dooley TP, Kindt KE, Baratz ME. Subungual tumors. *Hand (N Y)*. 2012;7(3):252-8.
5. Willard KJ, Cappel MA, Kozin SH, Abzug JM. Benign subungual tumors. *J Hand Surg Am*. 2012;37(6):1276-86.
6. Whitehouse HJ, Urwin R, Stables G. Traumatic subungual neuroma. *Clin Exp Dermatol*. 2018;43(1):65-66.
7. Lee CH, Baek JH, Kim KJ, Lee HH, Whan C, Lee JH. Subungual schwannoma mimicking glomus tumor on ultrasonography: a case report. *Arch Hand Microsurg*. 2017;22:268-72.
8. Whitehouse HJ, Urwin R, Stables G. Traumatic subungual neuroma. *Clin Exp Dermatol*. 2018;43(1):65-6.
9. Brown RE, Zook EG, Russell RC, Kucan JO, Smoot EC. Fingernail deformities secondary to ganglions of the distal interphalangeal joint (mucous cysts). *Plast Reconstr Surg*. 1991;87:718-25.
10. Ham KW, Yun IS, Tark KC. Glomus tumours: symptom variations and magnetic resonance imaging for diagnosis. *Arch Plast surg*. 2013;40:392-6.
11. Giard MC, Pineda C. Ganglion cyst versus synovial cyst? Ultrasound characteristics through a review of the literature. *Rheumatol Int*. 2015;35:597-605.
12. Tomoda T, Ono T, Ohyama K, Kojo Y. Subungual myxoid cyst producing an ulcer in the nail plate. *J Dermatol*. 1982;9(6):451-4.
13. Guéro S, Guichard S, Fraitag SR. Ligamentary structure of the base of the nail. *Surg Radiol Anat*. 1994;16(1):47-52.