



Subpedicle Subtraction Osteotomy for Treatment of Posttraumatic Thoracolumbar Kyphosis

Xiaofei Feng¹, Yongchao Li¹, Lijun Li² and Jun Tan^{1,2*}

¹School of Medicine, Tongji University, China

²Department of Spinal Surgery, Shanghai East Hospital, China

Abstract

Objective: To evaluate the surgical safety and clinical efficacy of Subpedicle Subtraction Osteotomy (SPSO) for treatment of posttraumatic thoracolumbar kyphosis.

Methods: A total of 43 patients diagnosed with posttraumatic thoracolumbar kyphosis were treated by SPSO. The mean follow-up period was 31.72 ± 6.43 months. Visual Analog Scale (VAS), Oswestry Disability Index (ODI) and general complications were recorded. The sagittal Cobb angle, Pelvic Incidence (PI), Pelvic Tilt (PT), Sacral Slope (SS) and Sagittal Vertical Axis (SVA) of the thoracolumbar kyphosis were measured to evaluate the sagittal balance preoperatively, 3 months postoperatively and the final follow-up.

Results: The average surgical time was 176 ± 19.56 min (range from 148 to 219 min). The mean intraoperative blood loss of 624.52 ± 139.16 ml (range from 380 ml to 840 ml). The VAS score of back pain was 6.86 ± 1.57 before operation, which improved to 1.36 ± 0.55 at final follow-up, with a significantly improved ($P < 0.01$). The mean ODI was $64.82 \pm 4.73\%$ preoperatively to $27.83 \pm 1.49\%$ at the final follow-up ($P < 0.01$). Compared with preoperative, the Cobb angle, PT and SS at three months postoperative and last follow-up were corrected significantly ($P < 0.01$).

The SVA were improved from 10.86 ± 3.24 cm at preoperative to 3.86 ± 1.37 cm at final follow-up ($P < 0.01$).

Conclusion: It could be safely and efficacy of the treatment of posttraumatic thoracolumbar kyphosis with SPSO.

Keywords: Thoracolumbar vertebrae; Osteotomy; Spinal fractures; Kyphosis; Sagittal vertical axis

OPEN ACCESS

*Correspondence:

Jun Tan, Department of Spinal Surgery,
Shanghai East Hospital, 150 Jimo
Road, Pudong New Area, Shanghai,
200120, China,
E-mail: dr_tan_jun@tongji.edu.cn

Received Date: 05 Jan 2022

Accepted Date: 15 Feb 2022

Published Date: 09 Mar 2022

Citation:

Feng X, Li Y, Li L, Tan J. Subpedicle
Subtraction Osteotomy for Treatment of
Posttraumatic Thoracolumbar Kyphosis.
Clin Surg. 2022; 7: 3436.

Copyright © 2022 Jun Tan. This is an
open access article distributed under
the Creative Commons Attribution
License, which permits unrestricted
use, distribution, and reproduction in
any medium, provided the original work
is properly cited.

Abbreviations

SPSO: Subpedicle Subtraction Osteotomy; PSO: Pedicle Subtraction Osteotomy; VAS: Visual Analog Scale; ODI: Oswestry Disability Index; PI: Pelvic Incidence; PT: Pelvic Tilt; SS: Sacral Slope; SVS: Sagittal Vertical Axis; SSEP: Spinal Evoked Potential; SD: Square Deviation; PVCR: Posterior Vertebral Column Resection

Introduction

Spinal fractures usually occur at the site of thoracolumbar junction, and there are often no obvious neurological symptoms at the time of injury, so it is easy to miss the best time for treatment [1-3]. If the thoracolumbar fracture can receive the correct non-surgical treatment or surgical treatment in the early stage, patient can obtain the good clinical effect, otherwise prone to kyphosis deformity [4,5]. Posttraumatic thoracolumbar fracture combined with kyphosis is often accompanied by severe back pain, spinal stenosis, nerve compression and spinal cord injury, which seriously affects the quality of life of patients [6-8]. Therefore, the old thoracolumbar fracture with kyphosis deformity often requires orthopedic surgery to restore the sagittal force line of the spine, relieve local compression and rebuild the stability of the spine, so as to achieve the purpose of relieving lumbar and back pain and improving the neurological function [9-11]. Previous studies have reported that kyphosis deformity of posttraumatic thoracolumbar fracture with a Cobb angle greater than 20° , combined with intractable pain and progressive nerve injury requires orthopedic surgery [6,2].

In recent decades, there are a variety of treatment methods for kyphosis after failure of

thoracolumbar fracture, mainly divided into three kinds of anterior, posterior and combined anterior-posterior approach, and various improved surgical methods have been reported constantly [12,13]. But the effectiveness of the various surgical procedures remains controversial [14]. At present, Pedicle Subtraction Osteotomy (PSO) is commonly used in clinical treatment of posttraumatic thoracolumbar fracture kyphosis. However, the disadvantage of this surgical method is that the spinous process, vertebral plate, facet joints and pedicle of the responsible segment are simultaneously removed, which makes the posterior column of the spine completely lose stability. In addition, the fusion interface of bone graft in this operation is only limited to the intervertebral body, which has a certain impact on spinal fusion [15,16].

In this study, we designed a modified procedure for PSO, namely subpedicle subtraction osteotomy. This procedure retains the pedicle at the osteotomy segment and combines percutaneous pedicle screw placement. Our philosophy is to combine minimally invasive surgery with open surgery to ensure the effectiveness of the operation with minimal trauma. This study retrospectively analyzed the treatment effect of 43 patients with old thoracolumbar fracture associated with kyphosis admitted to our hospital from January 2014 to December 2019, in order to evaluate the safety and clinical efficacy of this modified surgical technique.

Materials and Methods

Patient population

This study has been approved by the Medical Ethics Committee of Shanghai east hospital, and all patients have signed the informed consent. Case inclusion criteria: (1) Posttraumatic thoracolumbar fracture combined with kyphosis, (2) The Cobb angle of kyphosis deformity is greater than 20°, (3) Traumatic fracture lasted for more than 3 months, and there was obvious bone bridge connection in front of the vertebral body. Exclusion criteria: (1) Fresh thoracolumbar fracture, (2) Patients with degenerative scoliosis, (3) Patients with congenital spinal deformity, (4) Elderly patients with more serious symptoms of osteoporosis. All the patients in this group were old thoracolumbar fracture with kyphosis caused by trauma. There were 43 cases in total, including 19 males and 24 females, with an average age of 45.6 years (range from 27 to 80 years). Fracture site: 5 cases of T11, 17 cases of T12, 13 cases of L1, 8 cases of L2. Frankel classification: Grade C in 8 cases, Grade D in 19 cases, Grade E in 16 cases. After admission, all patients were routinely taken anteroposterior and lateral radiographs of thoracolumbar segment, three dimensional CT reconstructions of thoracolumbar segment and MRI scanning of thoracolumbar segment.

Surgical techniques

All patients were treated with general anesthesia, prone position, silica gel soft pad under chest and bilateral iliac spine, routine disinfection towel at the surgical site, and Spinal Evoked Potential (SSEP) detection.

Percutaneous nailing: C-arm X-ray was used to fluoroscopy and position the pedicle of the injured vertebra and two segments of the upper and lower vertebra, and marked the body surface. Then, under the guidance of C-arm X-ray, a trocar was used to puncture the pedicle of two segments of the upper and lower vertebral bodies. After the trocar puncture, the tube core was pulled out and the guide wire was inserted. A surgical incision of 1.0 cm to 1.5 cm in length was made at the puncture point, and the dilator tube was inserted step by step

from thin to thick to dilate the paravertebral muscle, and the working channel was well placed. Cannulated pedicle screws (UPASS, Weigao Orthopedic, Shandong, China) were inserted under the guidance of C-arm machine and guide wire. The titanium rod was inserted into the upper and lower pedicle screw tail in a predetermined arc through the skin. Longitudinal distraction was performed with a distraction tool. After satisfactory fluoroscopic reduction, the pedicle screw tail fixing screw was tightened to lock the pedicle screw rod connection.

Treatment of injured vertebrae: Preoperative positioning, with the vertex of kyphosis of vertebral body as the center, a median posterior incision, the incision length should be one segment on the upper and lower vertebrae. Subperiosteal dissection was performed to expose the lamina, facet joint and transverse process of the injured vertebra. The space between injured vertebra and lower vertebra was selected as the osteotomy plane.

Osteotomy and decompression: The facet joint of the fusion area was released. The cartilage surface was scraped. And carefully bite the upper vertebral plate of the lower vertebra, the lower vertebral plate of the injured vertebra and the lower facet of the injured vertebra with the gun forceps. It was noted that two-thirds of the isthmus of the injured vertebra was preserved. Contra-lateral short rods were temporarily fixed to prevent instability during osteotomy that could cause traction injury to the spinal cord. The transverse process of the injured vertebral body was removed by gun forceps. The rib head of the T12 vertebral body was also removed. Blunt dissection with subperiosteal to expose the lateral side of the injured vertebra, and pay attention to protect the nerve roots of the corresponding segment. The hemostatic gauze gradually fills the space between the periosteum and the vertebral body, and strips the blood vessels of the vertebral body together with the periosteum from the vertebral bone surface to the anterior edge of the vertebral body. Do the same for the opposite side. The important vessels at the anterior edge of the vertebral body and the anterior longitudinal ligament of the vertebral body were dissected with a blunt arc stripping device to clearly expose the lower intervertebral disc and the injured vertebral body. Osteotomy and circular spinal decompression were carried out by alternate bone knife and curette.

The scope of osteotomy: The lower osteotomy plane was parallel to the upper endplate of the lower vertebral body, and the lower disc of the injured vertebral body was removed. The upper osteotomy surface started from the subpedicle to the anterior edge of the vertebra. The inferior articular process of the injured vertebra and the injured vertebra body was cut off by bone knife. Under direct vision, the remaining lower intervertebral discs were removed alternately with curettes until the bone surface of the upper endplate of the lower vertebral body was bleeding to ensure that the lower vertebral body and the injured vertebral body were bone to bone after correction. The vertebral distractor properly dilated the osteotomy area, to the extent that the dura did not produce creases (Figure 1).

Bone graft fusion: Two large cortical bones and a large number of cancellous bones were taken from the posterior upper iliac spine. A portion of cancellous bone was filled into the first third of the intervertebral space. The trimmed iliac bone was implanted into the osteotomy area according to the osteotomy height, and the posterior edge of the bone block and the dural sac were explored with about 10 mm space. The connecting rod was pre-bent according to the normal sequence of the spine and connected to the pedicle screw. The screws were rotated alternately on both sides one by one. The

Table 1: Summary of clinical outcomes and radiologic assessments.

N=43	Preoperative	Postoperative three months	At final follow-up	P Value
VAS	6.86 ± 1.57	1.95 ± 0.84	1.36 ± 0.55	<0.01
ODI (%)	64.82 ± 4.73	31.29 ± 2.63	27.83 ± 1.49	<0.01
Cobb(°)	42.43 ± 4.38	8.46 ± 2.67	7.57 ± 2.31	<0.01
PI(°)	45.21 ± 6.48	46.18 ± 5.94	46.27 ± 5.86	0.736
PT(°)	25.65 ± 4.73	14.24 ± 3.83	13.97 ± 3.48	<0.01
SS(°)	21.08 ± 3.62	30.15 ± 5.61	30.85 ± 5.34	<0.01
SVA (cm)	10.86 ± 3.24	4.17 ± 2.42	3.86 ± 2.37	<0.01

VAS: Visual Analog Scale; ODI: Oswestry Disability Index; PI: Pelvic Incidence; PT: Pelvic Tilt; SS: Sacral Slope; SVA: Sagittal Vertical Axis

bone graft was taken as the hinge center, and the upper and lower vertebral plate were gradually closed up in a controlled manner, while the lamina closure and dural shrinkage were observed. The anterior edge of the intervertebral disc space opened, the posterior edge of the intervertebral disc space closed and the correction of kyphosis were verified by C-arm X-ray. After kyphosis correction, cancellous bone was filled again through the anterior column of the vertebral body in the lateral direction of the gap. And the bone graft surface in the surgical area was polished. The remaining bone fragments were clipped and implanted between the facet-joints.

Postoperative management

All patients received routine prophylactic antibiotics for 48 h after surgery in supine position with conventional wound drainage. When the volume of drainage fluid was less than 50 ml, the drainage tube was removed. One week after surgery, the braces were worn and moved out of bed until the braces were removed after bone graft fusion. Anteroposterior and lateral radiographs of thoracolumbar segment were taken three months after operation.

Clinical and radiological evaluation

Back pain was measured by Visual Analog Scale (VAS, in the range of 0 = no pain to 10 = worst pain), and clinical outcomes were assessed using Oswestry Disability Index (ODI). Surgical time, intraoperative blood loss, and general complications were recorded. Patients with preoperatively, three months postoperatively and at the time of the last follow-up thoracic lumbar segment were taken X-ray films. Compared the preoperatively and postoperatively thoracic lumbar protrusion deformity, Pelvic Incidence (PI), Pelvic Tilt (PT), Sacral Slope (SS) and Sagittal Vertical Axis (SVA, after S1 on edge and the center for C7 vertebral bodies do vertical distance, vertical in front edge positive after S1, located at the rear negative) were measured to evaluate the global sagittal balance.

Statistical analysis

Statistical analysis were performed by SPSS 21.0 (IBM Corporation, USA). The measurement data conforming to normal distribution were expressed as Mean ± Square Deviation (SD). The baseline characteristics of the two groups were analyzed by the independent sample t-test. One-way Analysis of Variance (ANOVA) was used for comparisons between the two groups. The within groups were compared by paired t-test. Normality was assumed and $P < 0.05$ was deemed as significant difference.

Results

All patients were successfully operated on. There were no serious complications, such as neurological injury, lower limb deep venous thrombosis, wound infection and death. Intraoperative dural tear occurred in two cases, who successfully repaired with 6-0 prolene

suture and experienced spinal fluid leak for nearly two weeks. All patients completed follow-up of 31.72 ± 6.43 months on average from 23 to 41 months. The mean operative times were 176.42 ± 19.56 min (range from 148 to 219 min). And the mean intraoperative blood loss of 624.52 ± 139.16 ml (range from 380 ml to 840 ml). At the final follow-up, bone fusion was found in all 43 patients, without obvious internal fixation failure and without sagittal displacement of the injured vertebrae. The VAS score of back pain was 6.86 ± 1.57 preoperatively, which improved to 1.36 ± 0.51 at final follow-up, with a significantly improved ($P < 0.01$). The mean ODI was $64.82 \pm 4.73\%$ preoperatively to $27.83 \pm 1.49\%$ at the final follow-up ($P < 0.01$) (Table 1). Neurological function improved from Frankel classification scale D to E in 14 patients, from Frankel classification C to D in 5 patients. The Cobb angle at three months postoperatively and the final follow-up were corrected approximately 35° significantly ($P < 0.01$). The PT and SS angles also were significantly improved ($P < 0.01$). The SVA were improved from 10.86 ± 3.24 cm preoperatively to 3.86 ± 1.37 cm at the final follow-up ($P < 0.01$) (Table 1). Respectively, the typical cases of subpedicle subtraction osteotomy are shown in Figure 2, 3.

Discussion

Thoracolumbar fracture is often flexion or burst fracture, usually accompanied by kyphosis [5,17]. Kyphosis deformity following thoracolumbar vertebral fracture is often caused by too early weight bearing, inappropriate conservative treatment, incorrect surgical procedure and fixation, inadequate immobilization and improper choice of internal fixation devices [4,2,18]. The biomechanical factors of its formation are the height loss of the injured vertebra, the destruction of the intervertebral disc and the instability of the facet joint. In addition, thoracolumbar burst fractures often occur in

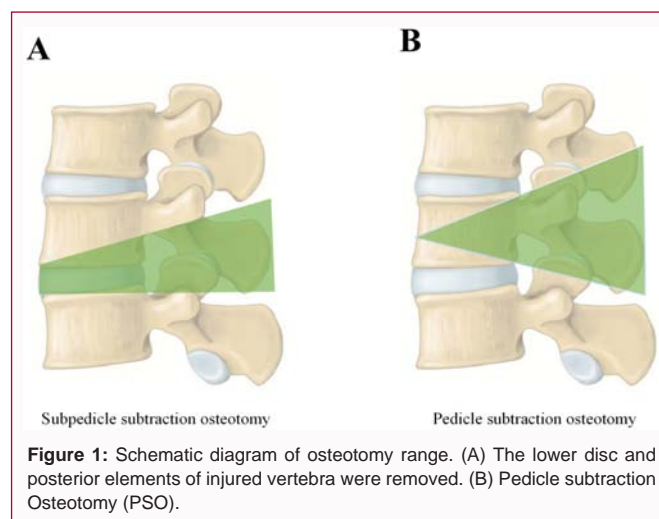

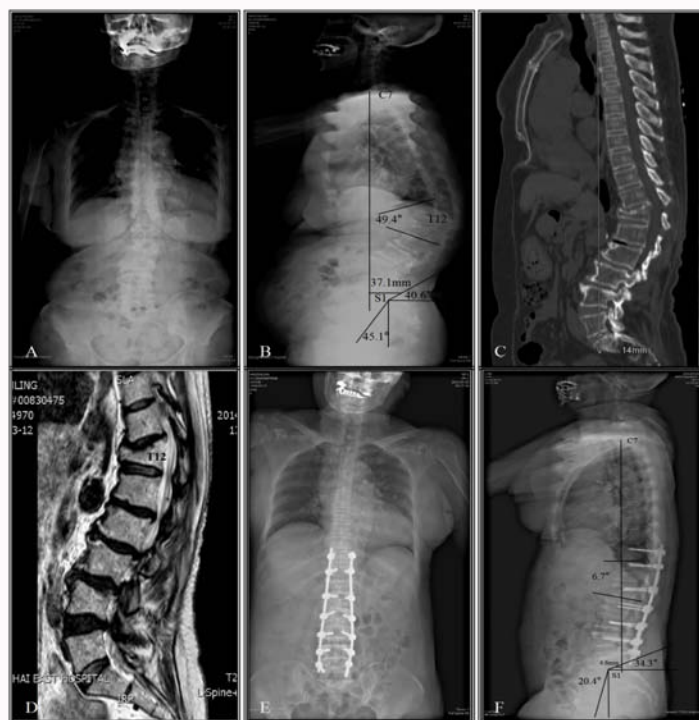


Figure 2: A 76 year old woman who was suffering from severe back pain and numbness in the left leg for more than 4 years due failure of conservative treatment, treated with the SPSO because of an old T12 fracture. (A) Preoperative anteroposterior radiograph. (B) Preoperative lateral radiographs. The apex of kyphosis is located at T12 with PT 45.1°, SS 40.6°, SVA 37.1 mm, and the Cobb angle is 49.4°. (C) CT. (D) MRI. (E) Three months postoperatively anteroposterior radiograph. (F) Postoperatively lateral radiographs. It was significantly improved that PI 20.4°, SS 34.3°, SVA 4.6 mm, and the Cobb angle is 6.7°.

endplate fractures, and the trabecular bone in the vertebral body is severely damaged [19,20]. Therefore, the vertebral body is not capable of loading, and there is a potential risk of kyphosis. As a result of long-term pull injury of paraspinal muscles, instability of small joints, imbalance of stress distribution, progressive aggravation of kyphosis and compression of posterior spinal cord and nerve roots, resulting in varying degrees of back pain and neurological symptoms [8,11,14].

Surgical strategy is based on the severity of old thoracolumbar fractures with kyphosis. There is no exact standard for surgical indication at home and abroad. The objective of the surgery is to restore the normal sagittal sequence of the spine, to restore spinal balance and stability, to achieve surgical site fusion, to relieve direct spinal compression, to relieve pain, and to correct deformity. The surgical approaches include anterior approach, posterior approach and anterior and posterior combined approach [12,21]. Although anterior decompression may be achieved by anterior approach, there is degeneration of the posterior column and spontaneous fusion, and the less correction effect of kyphosis [21,22]. The kyphosis can be corrected by anterior support and posterior fixation. But the double incision trauma is large and there are many complications [23]. Therefore, with the development of internal fixation and osteotomy, posterior surgery has been adopted by most spinal surgeons.

Common posterior osteotomy methods include single-segment "V" shape osteotomy through the articular process (Smith-Peterson Osteotomy, SPO) and closed wedge osteotomy through the pedicle to vertebral body (pedicle subtraction osteotomy, PSO) and Posterior Vertebral Column Resection (PVCR) [24-26]. SPO is a wedge shaped osteotomy in which the posterior column of the spine is closed by V-shaped resection of the articular process and vertebral plate to spread the middle and anterior columns of the spine. Its advantage

is that it can be used for single or multiple segmental osteotomy, simple operation, little interference to the nerve tissue, but only suitable for small-angle kyphosis [27]. PVCR is characterized by large surgical trauma, complications and high surgical risk. And it is mainly used for the deformity caused by coronal deformity or pathological fracture [28]. PSO is suitable for kyphosis angle ranging from 30° to 50°, which can be decompressed under direct vision and has a high fusion rate after osteotomy. It is commonly used in clinical correction of kyphosis. Transpedicle to vertebral osteotomy is performed by removing the posterior structure of the spine with the anterior longitudinal ligament as the hinge to achieve the purpose of correction. A single segment osteotomy can achieve a correction of 30°. However, there is a high incidence of postoperative pseudoarthrosis due to structural damage of the posterior column of the spine [29,30].

In recent years, modified PSO surgery has been introduced into the treatment of thoracolumbar vertebral fractures with kyphosis, with fewer complications, high deformity correction rate and high bone fusion rate, and good clinical efficacy [14,16,31]. Kyphosis correction is achieved by vertebral osteotomy with pedicle preservation *via* posterior approach, which excises the upper disc, part of the injured vertebrae and accessories, closes the posterior column of the spine, and opens the anterior column of the spine. In this study, the hinge center of subpedicle subtraction osteotomy is usually located in the middle of the vertebral body, namely the implanted iliac bone block, which is different from the previous method of using the anterior longitudinal ligament in front of the injured vertebral body as the hinge and fulcrum for wedge closure. Cancellous bone particles and iliac bone pieces were implanted in the front of the spine to restore the height of the anterior column. Restoring the height of the anterior

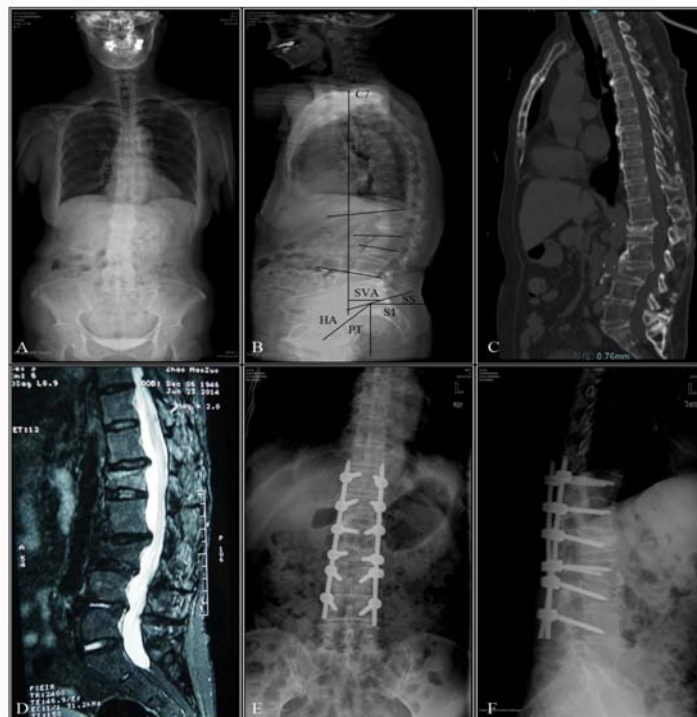


Figure 3: A 68 year old woman who was suffering from progressive aggravation of back pain for more than 1 year due failure of conservative treatment, treated with the SPSO because of an old L1 and L3 fracture. (A) Preoperative anteroposterior radiograph. (B) Preoperative lateral radiographs. (C) CT. (D) MRI. (E) Postoperatively anteroposterior radiograph. (F) Postoperatively lateral radiographs.

column can effectively avoid the risk of spinal cord shrinkage caused by spinal shortening, improve the correction degree of osteotomy and fusion rate, reduce the displacement of bone graft, and avoid pseudarthrosis formation and internal fixation failure. Subpedicle subtraction osteotomy, the modified PSO surgery technique, increased the resection of adjacent intervertebral discs, and bone grafts were added at the osteotomy surface and anterolateral, which increase the fusion rate of bone grafts and reduce the loss of corrected Cobb angle caused by intervertebral disc degeneration. Combining the advantages of SPO and PSO, subpedicle subtraction osteotomy not only overcomes the disadvantage of no bony contact between vertebrae after the correction of the anterior column wedge distraction by SPO, increasing the stability of the anterior middle column, but also overcomes the disadvantage of excessive shortening of the anterior middle column of PSO, reducing the risk of spinal cord flexion and injury.

Furthermore, Subpedicle Subtraction Osteotomy (SPSO) completely retained the isthmic part of the injured vertebra and the superior articular process, as well as the continuity between the injured vertebra and the upper vertebra, which improved the stability of the osteotomy area and prevented the sagittal displacement of the vertebra in the osteotomy area during orthopedic surgery, so as to avoid spinal cord injury. Another advantage of this method was that the lower wall of the upper nerve root channel is retained, which not damage the upper nerve will root during decompression and reduction, thus reducing the possibility of nerve root injury. In addition, this procedure makes full use of the hinge center of the bone graft for a controlled slow reduction, thus avoiding the use of violence during the reduction and preventing spinal cord injury. Bleeding control is one of the important factors to ensure the successful completion of kyphotic osteotomy [32]. Shortening operation time

and avoiding segmental vascular injury are the fundamental methods to reduce bleeding under the condition of ensuring safety [33,34]. In this study, there was no need to remove all the vertebral plate of the injured vertebra. And only the injured vertebra and the lateral side of its lower intervertebral disc was exposed during the operation, rather than the adjacent vertebra of the injured vertebra. During the operation, the visual field is clear. The bone chisel can chisel most of the injured vertebra and lower intervertebral disc, and the scraping spoon can remove the residual tissue, which significantly improves the decompression speed. Moreover, when the external wall of the injured vertebra is exposed, the blood vessels of the vertebral segment and periosteum were removed together with the vertebral bone surface after the hemostatic gauze is filled, so as to prevent bleeding caused by segmental vascular injury.

In conclusion, SPSO can safely and effectively correct thoracolumbar kyphosis, intact on the injured vertebral spondylolysis and superior articular process, keep the continuity of injured vertebral and upper vertebral body, reduce sagittal displacement of the spine at the osteotomy area, and preserve the upper wall of the nerve root channel to reducing nerve root damage.

Funding

This work was supported by the National Key Research and Development Program (No. 2017YFA0105404). The funders had no role in study design, data collection and analysis, decision to publish, or preparation of the manuscript.

References

1. Knop C, Fabian HF, Bastian L, Blauth M. Late results of thoracolumbar fractures after posterior instrumentation and transpedicular bone grafting. *Spine (Phila Pa 1976)*. 2001;26(1):88-99.

2. Cho KJ, Kim KT, Kim WJ, Lee SH, Jung JH, Kim YT, et al. Pedicle subtraction osteotomy in elderly patients with degenerative sagittal imbalance. *Spine (Phila Pa 1976)*. 2013;38(24):E1561-6.
3. Vaccaro AR, Silber JS. Post-traumatic spinal deformity. *Spine (Phila Pa 1976)*. 2001;26(24 Suppl):S111-8.
4. Hu W, Wang B, Run H, Zhang X, Wang Y. Pedicle subtraction osteotomy and disc resection with cage placement in post-traumatic thoracolumbar kyphosis, a retrospective study. *J Orthop Surg Res*. 2016;11(1):112.
5. Lazennec JY, Neves N, Rousseau MA, Boyer P, Pascal-Mouselard H, Saillant G. Wedge osteotomy for treating post-traumatic kyphosis at thoracolumbar and lumbar levels. *J Spinal Disord Tech*. 2006;19(7):487-94.
6. Enercan M, Ozturk C, Kahraman S, Sarier M, Hamzaoglu A, Alanay A. Osteotomies/spinal column resections in adult deformity. *Eur Spine J*. 2013;22(Suppl 2):S254-64.
7. Kashlan ON, Valdivia JM. Pedicle-sparing transforaminal thoracic spine wedge osteotomy for kyphosis correction. *Surg Neurol Int*. 2014;5(Suppl 15):S561-3.
8. Yang BP, Ondra SL, Chen LA, Jung HS, Koski TR, Salehi SA. Clinical and radiographic outcomes of thoracic and lumbar pedicle subtraction osteotomy for fixed sagittal imbalance. *J Neurosurg Spine*. 2006;5(1):9-17.
9. Choi HY, Hyun SJ, Kim KJ, Jahng TA, Kim HJ. Radiographic and clinical outcomes following pedicle subtraction osteotomy: Minimum 2-year follow-up data. *J Korean Neurosurg Soc*. 2020;63(1):99-107.
10. Wu SS, Hwa SY, Lin LC, Pai WM, Chen PQ, Au MK. Management of rigid post-traumatic kyphosis. *Spine (Phila Pa 1976)*. 1996;21(19):2260-6.
11. Smith JS, Klineberg E, Lafage V, Shaffrey CI, Schwab F, Lafage R. Prospective multicenter assessment of perioperative and minimum 2-year postoperative complication rates associated with adult spinal deformity surgery. *J Neurosurg Spine*. 2016;25(1):1-14.
12. Munting E. Surgical treatment of post-traumatic kyphosis in the thoracolumbar spine: Indications and technical aspects. *Eur Spine J*. 2010;19(Suppl 1):S69-73.
13. Uribe JS, Schwab F, Mundis GM, Xu DS, Januszewski J, Kanter AS, et al. The comprehensive anatomical spinal osteotomy and anterior column realignment classification. *J Neurosurg Spine*. 2018;29(5):565-75.
14. Gao R, Wu J, Yuan W, Yang C, Pan F, Zhou X. Modified partial pedicle subtraction osteotomy for the correction of post-traumatic thoracolumbar kyphosis. *Spine J*. 2015;15(9):2009-15.
15. Rose PS, Bridwell KH, Lenke LG, Cronen GA, Mulconrey DS, Buchowski JM, et al. Role of pelvic incidence, thoracic kyphosis, and patient factors on sagittal plane correction following pedicle subtraction osteotomy. *Spine (Phila Pa 1976)*. 2009;34(8):785-91.
16. Wang MY. Miniopen pedicle subtraction osteotomy: Surgical technique and initial results. *Neurosurg Clin N Am*. 2014;25(2):347-51.
17. Prajapati HP, Kumar R. Thoracolumbar fracture classification: evolution, merits, demerits, updates, and concept of stability. *Br J Neurosurg*. 2021;35(1):92-7.
18. Filgueira EG, Imoto AM, da Silva HEC, Meves R. Thoracolumbar burst fracture: McCormack load-sharing classification: Systematic review and single-arm meta-analysis. *Spine (Phila Pa 1976)*. 2021;46(9):E542-50.
19. Wang J, Zhou Y, Zhang ZF, Li CQ, Zheng WJ, Liu J. Radiological study on disc degeneration of thoracolumbar burst fractures treated by percutaneous pedicle screw fixation. *Eur Spine J*. 2013;22(3):489-94.
20. Brantigan JW, Steffee AD, Geiger JM. A carbon fiber implant to aid interbody lumbar fusion. Mechanical testing. *Spine (Phila Pa 1976)*. 1991;16(6 Suppl):S277-82.
21. Wood KB, Bohn D, Mehdob A. Anterior versus posterior treatment of stable thoracolumbar burst fractures without neurologic deficit: A prospective, randomized study. *J Spinal Disord Tech*. 2005;18:S15-23.
22. Anand N, Cohen JE, Cohen RB, Khandehroo B, Kahwaty S, Baron E. Comparison of a newer versus older protocol for Circumferential Minimally Invasive Surgical (CMIS) Correction of Adult Spinal Deformity (ASD)-evolution over a 10-year experience. *Spine Deform*. 2017;5(3):213-23.
23. Auerbach JD, Lenke LG, Bridwell KH, Sehn JK, Milby AH, Bumpass D, et al. Major complications and comparison between 3-column osteotomy techniques in 105 consecutive spinal deformity procedures. *Spine (Phila Pa 1976)*. 2012;37(14):1198-210.
24. Zeng Y, Chen Z, Sun C, Li W, Qi Q, Guo Z, et al. Posterior surgical correction of posttraumatic kyphosis of the thoracolumbar segment. *J Spinal Disord Tech*. 2013;26(1):37-41.
25. Chang KW, Chen YY, Lin CC, Hsu HL, Pai KC. Apical lordosating osteotomy and minimal segment fixation for the treatment of thoracic or thoracolumbar osteoporotic kyphosis. *Spine (Phila Pa 1976)*. 2005;30(14):1674-81.
26. El-Sharkawi MM, Koptan WM, El-Miligi YH, Said GZ. Comparison between pedicle subtraction osteotomy and anterior corpectomy and plating for correcting post-traumatic kyphosis: A multicenter study. *Eur Spine J*. 2011;20(9):1434-40.
27. Geck MJ, Macagno A, Ponte A, Shufflebarger HL. The Ponte procedure: Posterior only treatment of Scheuermann's kyphosis using segmental posterior shortening and pedicle screw instrumentation. *J Spinal Disord Tech*. 2007;20(8):586-93.
28. Suk SI, Kim JH, Lee SM, Chung ER, Lee JH. Anterior-posterior surgery versus posterior closing wedge osteotomy in posttraumatic kyphosis with neurologic compromised osteoporotic fracture. *Spine (Phila Pa 1976)*. 2003;28(18):2170-5.
29. Chang KW, Cheng CW, Chen HC, Chang KI, Chen TC. Closing-opening wedge osteotomy for the treatment of sagittal imbalance. *Spine (Phila Pa 1976)*. 2008;33(13):1470-7.
30. Bridwell KH, Lewis SJ, Rinella A, Lenke LG, Baldus C, Blanke K. Pedicle subtraction osteotomy for the treatment of fixed sagittal imbalance. Surgical technique. *J Bone Joint Surg Am*. 2004;86-A Suppl 1:44-50.
31. Chen F, Kang Y, Li H, Lv G, Lu C, Li J, et al. Modified pedicle subtraction osteotomy as a salvage method for failed short-segment pedicle instrumentation in the treatment of thoracolumbar fracture. *Clin Spine Surg*. 2016;29(3):E120-6.
32. Hu X, Thapa AJ, Cai Z, Wang P, Huang L, Tang Y, et al. Comparison of smith-petersen osteotomy, pedicular subtraction osteotomy, and poly-segmental wedge osteotomy in treating rigid thoracolumbar kyphotic deformity in ankylosing spondylitis: a systematic review and meta-analysis. *BMC Surg*. 2016;16:4.
33. Liu H, Yang C, Zheng Z, Ding W, Wang J, Wang H, et al. Comparison of Smith-Petersen osteotomy and pedicle subtraction osteotomy for the correction of thoracolumbar kyphotic deformity in ankylosing spondylitis: A systematic review and meta-analysis. *Spine (Phila Pa 1976)*. 2015;40(8):570-9.
34. Abulizi Y, Liang WD, Maimaiti M, Sheng WB. Smith-Petersen osteotomy combined with anterior debridement and allografting for active thoracic and lumbar spinal tuberculosis with kyphotic deformity in young children: A prospective study and literature review. *Medicine (Baltimore)*. 2017;96(32):e7614.