



## Staged Ablation and Complex Reconstruction of Extensive Perineal Hidradenitis Suppurativa

Michael R DeLong<sup>1</sup> and Salah Rubayi<sup>2\*</sup>

<sup>1</sup>Department of Surgery, University of California at Los Angeles, California, USA

<sup>2</sup>Department of Surgery, Rancho Los Amigos National Rehabilitation Center, California, USA

### Abstract

Hidradenitis Suppurative (HS) is a potentially debilitating chronic inflammatory condition affecting apocrine gland-bearing tissue found in the axilla and perineum. We describe the staged ablation and complex reconstruction of extensive HS involving the perineum, gluteus, scrotum, and perianal region in a paraplegic patient. Complete eradication of the disease required diverting colostomy, anal closure, and extensive subcutaneous tissue excision. At a second stage, reconstruction was performed with bilateral gluteal advancement flaps to cover the rectal stump, a rotation medial thigh fasciocutaneous flap to provide durable coverage for the perineum, and split thickness skin grafting to reconstruct the scrotum and denuded gluteal muscle. With this technique, the patient was successfully cured of his HS and was provided an excellent reconstruction.

### Introduction

Hidradenitis suppurativa (HS) is a chronic inflammatory condition affecting the apocrine sweat gland-bearing tissues present primarily in the axilla and perineum [1]. The etiology of HS is incompletely understood but is believed to possibly involve a combination of follicular occlusion, glandular dysfunction, hormonal imbalance, autoimmune response, and possible bacterial superinfection [2]. No definite causative factors have been identified, but obesity, humidity, and certain medications have been associated with an increased risk [3]. HS can range in severity from isolated pustules to extensive sinus tracts with copious malodorous purulence, which is socially debilitating for affected patients. Malignant degeneration has also been described in rare cases [4].

First line medical management for less severe HS usually employs lifestyle changes, weight loss, and antimicrobials and anti-inflammatory medications, such as Doxycycline [3]. Second line treatment with more potent immunomodulators such as Infliximab has been described with relative success [5]. However, for severe HS or medically refractory patients, surgery is reserved as a final treatment modality. Surgical management of HS requires the complete excision of all involved glands and tissues which generally results in a large denuded area. Subsequent reconstruction is often staged until complete eradication of the disease is confirmed to prevent coverage of an infected wound. We describe the staged ablation and complex reconstruction of extensive and severe HS in a paraplegic patient.

### Case Presentation

The patient is a thirty-five year old African American male with a history of thoracic level 4 (T4) complete paraplegic spinal cord injury secondary to a gunshot wound suffered in 2003. During his initial trauma he underwent thoracotomy, partial right lobe resection, and exploratory laparotomy. After recovering from the acute injury, he suffered from chronic neurogenic bowel and bladder, muscle spasms, and developed severe chronic hidradenitis suppurativa affecting his scrotum, perineum, perianal area, and gluteal soft tissues for at least four years. In 2013 he underwent staged bilateral inguinal HS excision bridged with wound vacuum to split thickness skin grafting at an outside hospital. He then underwent further debridement of his scrotum and perineum in 2014 at a different hospital. The other hospital's colorectal surgery service evaluated him at that time and recommended no management of his peri-anal HS.

He presented to the clinic at Rancho Los Amigos Medical Center in March 2018 with extensive disease and significant purulent drainage from his peri-anal region, gluteal soft tissue, perineum, and posterior scrotum. He was temporized with Levaquin and Flagyl to attenuate the purulent discharge and was electively admitted the following month for surgical management. Diverting end sigmoid

### OPEN ACCESS

#### \*Correspondence:

Salah Rubayi, Department of Surgery,  
Rancho Los Amigos National  
Rehabilitation Center, 7601 Imperial  
Hwy, Downey, California 90242, USA,  
E-mail: srubayi@dhs.lacounty.gov

Received Date: 21 Jun 2018

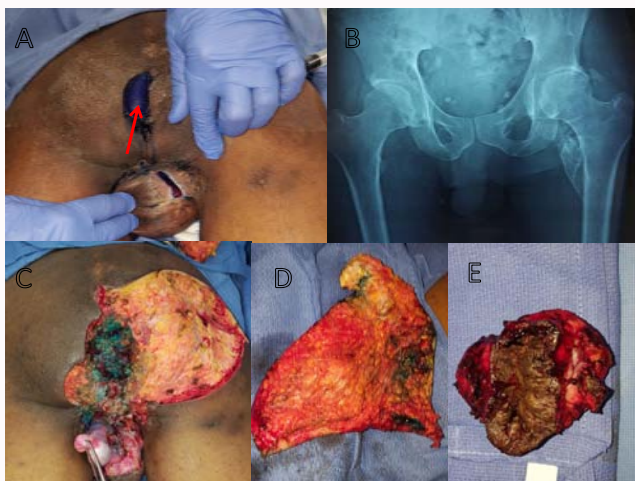
Accepted Date: 13 Jul 2018

Published Date: 18 Jul 2018

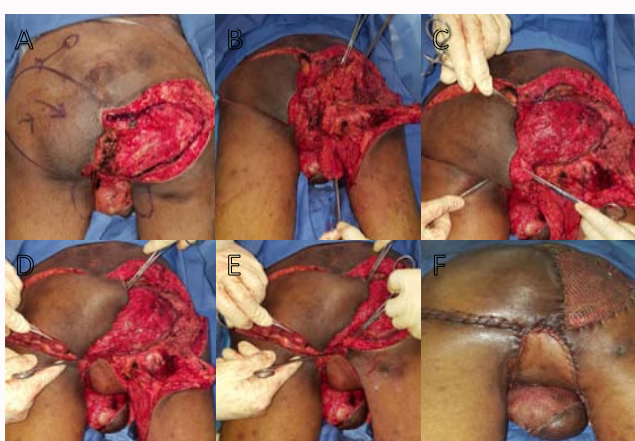#### Citation:

DeLong MR, Rubayi S. Staged  
Ablation and Complex Reconstruction  
of Extensive Perineal Hidradenitis  
Suppurativa. Clin Surg. 2018; 3: 2040

Copyright © 2018 Salah Rubayi. This  
is an open access article distributed  
under the Creative Commons Attribution  
License, which permits unrestricted  
use, distribution, and reproduction in  
any medium, provided the original work  
is properly cited.

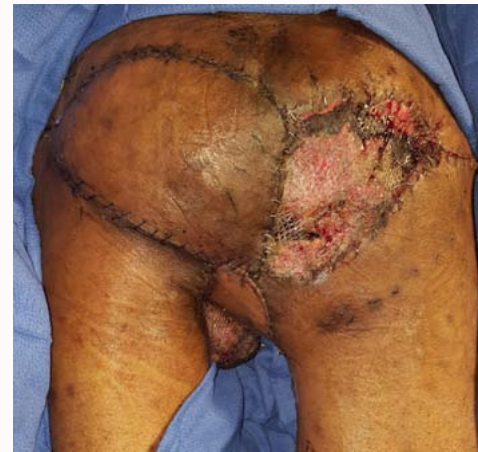

**Figure 1: Hidradenitis debridement.** (A) Extensive disease involving scrotum and anus. Methylene blue dye escaping from sinus tracts surrounding anus when injected through sinus tract opening in right gluteus (red arrow). (B) Preoperative radiograph demonstrating no extensive heterotopic ossification or osteomyelitis. (C) After excision of anus and closure of rectal stump and debridement of scrotum, perineum, and right gluteal soft tissues. Residual methylene blue staining observed over rectal stump. Exposed testicle being held in forceps. (D) Excised specimen - right gluteal subcutaneous tissue and skin. (E) Excised specimen - anus.



**Figure 2: Reconstruction of defect.** (A) Preoperative defect with planned surgery depicted. Left gluteal advancement flap. Right gluteal muscle advancement. Right medial thigh fasciocutaneous flap. (B) After flap dissection all of the flaps can be seen mobilized. (C) Closure of the rectal stump with bilateral advancement of the gluteal flaps. (D) Rotation of the right medial thigh flap to cover the perineum. (E) Advancement of right posterior thigh skin. (F) On-table postoperative result with meshed flaps inset and skin graft to right gluteus and scrotum.

colostomy and mucous fistula was performed by general surgery in anticipation of his excision and reconstruction. He recovered uneventfully from his ostomy and was taken on postoperative day 8 for excision of his affected tissues (Figure 1). During this surgery, his anus was excised and rectal stump was closed with absorbable sutures. Methylene blue dye was infiltrated through all external sinuses and involved tissue was aggressively debrided including his scrotum, right gluteal subcutaneous fat and skin, and perineum. At the end of this surgery he was continued on Vancomycin and Meropenem and his wound was packed with Dakin's wet-to-dry dressings daily and his condition was followed on the wards. After one week it was confirmed that his remaining tissues were clear of disease, and he was taken on postoperative day 11 (debridement)/19 (ostomy) for final



**Figure 3: Postoperative day eleven result.** Flaps and skin graft viable and intact. Rectal stump successfully covered and perineum protected by robust medial thigh rotation flap.

reconstruction (Figure 2).

The initial objective of reconstructive surgery was durable tissue coverage of the rectal stump and perineal region given the patient's paralysis and anticipated wheelchair sitting. Bilateral gluteal advancement V-Y flaps were mobilized and stacked over the rectal stump to provide a robust layer of soft tissue coverage. The perineum was then surfaced with a rotation fasciocutaneous flap from the right medial thigh, and the donor site was closed primarily. After the susceptible regions were covered with durable tissue, the right gluteal muscle and scrotum still required skin coverage. Because the gluteus already had a thick layer of muscular coverage and the scrotum was not a site of future compression, these areas were grafted with a split thickness skin graft taken from the right lower leg.

The dressings were removed eight days after reconstructive surgery and the reconstruction was found to be intact with viable flaps. Our ablative surgery successfully removed all of the patient's HS and the ultimate reconstruction provided appropriate coverage of all of the critical structures with a maintained resistance to future breakdown with prolonged wheelchair sitting (Figure 3).

## Conclusion

The staged extirpation and complex reconstruction of extensive severe HS in a paraplegic patient is possible and safe but requires the selection of multiple synergistic flaps to provide a successful result.

## References

1. Revuz J. Hidradenitis suppurativa. *J Eur Acad Dermatol Venereol.* 2009;23(9):985-98.
2. Alikhan A, Lynch PJ, Eisen DB. Hidradenitis suppurativa: A comprehensive review. *J Am Acad Dermatol.* 2009;60(4):539-61.
3. Slade DEM, Powell BW, Mortimer PS. Hidradenitis suppurativa: Pathogenesis and management. *Br J Plast Surg.* 2003;56(5):451-61.
4. Grewal NS, Wan DC, Roostaeian J, Rubayi SR. Marjolin ulcer in hidradenitis suppurativa: Case reports. *Ann Plast Surg.* 2010;64(3):315-7.
5. Delage M, Samimi M, Atlan M, Mchet L, Lorette G, Maruani A. Efficacy of infliximab for hidradenitis suppurativa: Assessment of clinical and biological inflammatory markers. *Acta Derm Venereol.* 2011 Mar;91(2):169-71.