



## Spontaneous Splenic Rupture Five Days after Appendectomy via McBurney Incision: A Case Report

Gabriel Marin<sup>1\*</sup>, Mario Javier de Miguel Valencia<sup>1</sup>, Ana Ligia Acevedo Ramírez<sup>1</sup>, Miguel Ángel Resano Abárzuza<sup>2</sup>, Maite Millor Muruzabal<sup>3</sup>, M<sup>a</sup> Felicidad Pérez Omeñaca<sup>1</sup> and Iñaki Alberdi Ibáñez<sup>1</sup>

<sup>1</sup>Department of General Surgery, Reina Sofía Hospital, Tudela, Navarra, Spain

<sup>2</sup>Department of Pathology, Reina Sofía Hospital, Tudela, Navarra, Spain

<sup>3</sup>Department of Radiology, Reina Sofía Hospital, Tudela, Navarra, Spain

### Abstract

**Introduction:** Spontaneous splenic rupture is an unusual and life-threatening surgical emergency. The literature on this previously debated entity consists mainly of clinical cases. We present the first case of a splenic rupture occurred after an appendectomy via McBurney incision.

**Clinical Case:** A 10 year-old patient with a clinical picture of hypogastric pain and vomiting of 48 hours onset. She was diagnosed with appendicular peritonitis and appendectomy with peritoneal lavage was performed through a McBurney incision. Five days after hospital discharge, the patient was re-admitted due to left flank pain and pallor. The patient was re-intervened through the McBurney incision, revising the surgical bed of the appendectomy. Postoperatively Angio-CT was performed for suspicion of persisting bleeding. A ruptured splenic hematoma with active signs of bleeding was found. Urgent midline laparotomy and splenectomy was performed.

**Conclusion:** Delayed splenic rupture after appendectomy is an unexpected event. The presence of hemoperitoneum post appendectomy may prematurely lead to intraoperative reexploration of the surgical site. Preoperative efforts to accurately diagnose the bleeding source may avoid multiple surgeries and shorten hospital stay.

### OPEN ACCESS

#### \*Correspondence:

Gabriel Marin, Department of General Surgery, Reina Sofía Hospital, Tudela, Navarra, Spain;

E-mail: gabimarrin@yahoo.com

Received Date: 01 Aug 2019

Accepted Date: 12 Sep 2019

Published Date: 17 Sep 2019

#### Citation:

Marin G, de Miguel Valencia MJ, Acevedo Ramírez AL, Resano Abárzuza MÁ, Muruzabal MM, Felicidad Pérez Omeñaca M<sup>a</sup>, et al. Spontaneous Splenic Rupture Five Days after Appendectomy via McBurney Incision: A Case Report. *Clin Surg.* 2019; 4: 2571.

**Copyright** © 2019 Gabriel Marin. This is an open access article distributed under the Creative Commons Attribution License, which permits unrestricted use, distribution, and reproduction in any medium, provided the original work is properly cited.

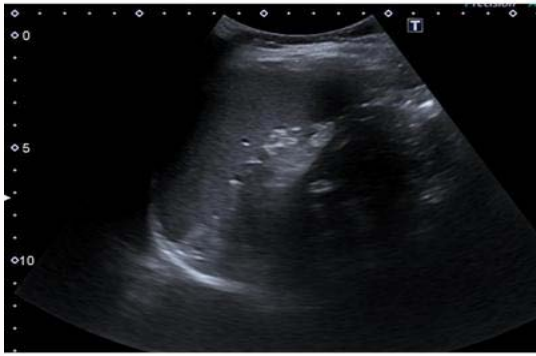**Keywords:** Appendectomy; Complications; Spontaneous rupture; Rupture; Spleen; Atraumatic

### Introduction

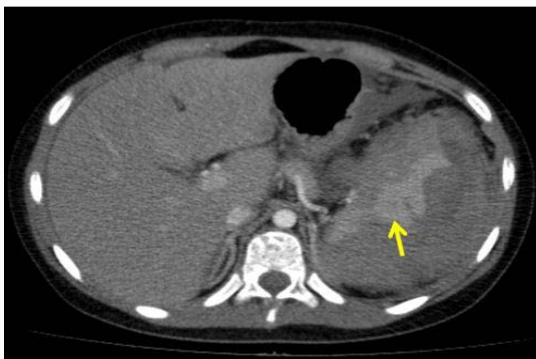
Atraumatic rupture of the spleen is a rare event, with a mortality rate of up to 12%. In 93% of cases this condition is related to underlying pathologic conditions such as neoplasms, infections, inflammation, medication, and mechanical (pathological atraumatic rupture) [1]. Upper digestive tract surgical procedures, colon surgery, colonoscopy, ERCP (endoscopic retrograde cholangiopancreatography), left nephrectomy, percutaneous nephrolithotomy, gynaecology surgery, chest drainage and cardiopulmonary resuscitation have also been associated with splenic ruptures [2]. In the absence of trauma or known systemic disease, splenic rupture has been a debated entity. However in the recent literature it is recognized that in approximately 7% of the cases of atraumatic splenic rupture there is no immediate identifiable cause [1]. We present the first case of a delayed spontaneous splenic rupture after an open appendectomy via McBurney incision.

### Clinical Case

A 10 year and 5 months- old patient presented to the emergency department with a 48 h history of vomiting and hypogastric pain. She had no previous medical or surgical history. Clinical examination findings showed right iliac fossa pain and rigidity. Laboratory tests revealed hemoglobin of 14.8 g/dL, hematocrit of 42.6% and  $9.4 \times 10^9/L$  white cells with a left shift. The abdominal ultrasound was compatible with the diagnosis of acute appendicitis. No spleen alteration was seen using this technique (Figure 1). Surgery was performed through a McBurney incision. An acute perforated appendicitis with localized peritonitis was found and appendectomy with abundant peritoneal lavage was performed. The patient was discharged on day 3 after an uneventful postoperative course. Forty-eight hours after hospital discharge the patient returned to the Emergency Department with a clinical picture of left upper quadrant pain and pallor. On her arrival she was hypotensive (Blood Pressure 93/61 mmHg) and tachycardic (Heart Rate 118). The



**Figure 1:** Ultrasonography showing normal sized spleen with normal morphology and echogenicity.



**Figure 2:** Angio-TC showing a marked increase in the size of the spleen and heterogeneity of parenchyma. Hyperdense area indicating active bleeding (yellow arrow).

laboratory results showed hemoglobin of 10.6 g/dL and a hematocrit of 30.3%. The abdominal ultrasound performed showed the presence of free fluid around the liver and spleen and a minimum amount of free fluid between the small bowel loops. It was decided to keep the patient under observation with intravenous fluid therapy, fasting and analgesia. Repeat laboratory testing after 8 hours follow-up revealed a drop of 3 points in the hemoglobin level. The patient was prepared for theatre and an extended McBurney incision was performed due to suspicion of hemoperitoneum. One liter of fresh and clotted blood was aspirated from the abdomen and the ligatures of the mesoappendix were reviewed with no bleeding point being observed. An overall examination of the rest of the abdominal cavity did not reveal any other significant findings. Postoperatively the patient was transfused 400 mL of packed red cells. In the following 8 h persistent tachycardia and a further decrease in hemoglobin were observed. Emergency angio-CT of the abdomen revealed a ruptured splenic hematoma of 12 cm × 8.2 cm × 12 cm with hemoperitoneum (Figure 2). The patient was taken to the operating theatre and a midline laparotomy was performed. Fresh bleeding from a large splenic hematoma in contact with the diaphragm was seen and a splenectomy was performed. Subsequent recovery was uneventful. The patient required Intensive Care Unit for 72 h, and was discharged from hospital on day 8 after surgery. The histological examination confirmed normal spleen dimensions and normal parenchyma ruling out any intrinsic disease of the spleen.

## Discussion

Spontaneous rupture of the spleen is a rare event, and is defined

in the absence of mechanical injury or previously known disease. In 1958 Orloff and Peskin described the four criteria to define a spontaneous splenic rupture: no history of injury, absence of peri-splenic adhesions, absence of systemic diseases that may involve the spleen and a grossly and histologically normal spleen [3]. A spontaneous rupture of the spleen after open appendectomy through a McBurney incision is an exceptional occurrence. In our literature search we only found one similar case describing a splenic rupture after an appendectomy via infra-umbilical midline laparotomy [4]. A spontaneous rupture of the spleen was diagnosed in the present case since we were not able to identify any common pathogenetic mechanism of splenic injury. Minimal trauma that usually passes unnoticed or the splenic compression due to cough, vomiting or epileptic seizures, are described causes of splenic rupture [5]. In the present case a detailed anamnesis found no evidence of trauma events in the peri-operative period. However, the episodes of post-operative vomiting or a possible inadvertent injury during the transport within the hospital could precipitate a delayed splenic rupture. Fluid therapy was used after the appendectomy, as well as normal analgesia, stress ulcer prophylaxis, antiemetic and antibiotic medication, none of them being susceptible to alter coagulation. Anti-thrombotic prophylaxis with low molecular weight heparin was not used. In addition, the patient had no medical record and the histologic result of the spleen was normal ruling out a pathological splenic rupture. The appendectomy was the only event associated with the splenic rupture. However, the operating field offered by the McBurney incision is well away from the splenic area, making any direct or indirect traction over the spleen very unlikely. The presence of intra-peritoneal or peri-splenic adhesions was also ruled out during the midline laparotomy.

## Conclusion

The need for a splenectomy is exceptional and generally not considered by the surgeon in the post-operative period of an appendectomy. Our case is the first that describes a spontaneous splenic rupture occurred after surgery through McBurney incision. Multiple interventions may be necessary to control the source of bleeding in seemingly straightforward cases as ours. Possibility of bleeding from an unsuspected site should be kept in mind before going back to the operative theatre. Efforts to precisely identify the source of bleeding preoperatively may change the operative strategy and avoid unsuccessful attempts at hemostasis in the operative theatre.

## Highlights

- Rupture of the spleen in the absence of traumatic injury or previously diagnosed disease is an unusual event.
- Postoperative hemoperitoneum after open appendectomy is infrequent and caused by surgical site bleeding
- Spontaneous splenic rupture after open appendectomy is a rare complication typically not considered as a differential diagnosis for postoperative hemoperitoneum.

## References

1. Akoury T, Whetstone DR. Splenic Rupture. Stat Pearls [Internet]. Treasure Island (FL): Stat Pearls Publishing; 2019.
2. Feola A, Niola M, Conti A, Delbon P, Graziano V, Paternoster M, et al. Iatrogenic splenic injury: review of the literature and medico-legal issues. *Open Med.* 2016;11(1):307-15.
3. John AK. Splenic rupture in a patient with pelvic abscess and sepsis.

- Singapore Med J. 2012;53(1):e6-8.
4. Parker R, Gravante G, Elshaer M, Humayun N, Ebdewi H. Spontaneous splenic rupture four days after an open appendectomy. *Ann R Coll Surg Engl.* 2015;97(2):e23-4.
  5. Aubrey-Bassler FK, Sowers N. "613 cases of splenic rupture without risk factors or previously diagnosed disease: a systematic review". *BMC Emerg Med.* 2012;12(1).