



Small Vessels, Big Solutions; Use of Graft Conduit to Facilitate Transfemoral Impella CP Implantation

Monteagudo Vela M*, Garcia Saez D, Zych B and Simon A

Department of Cardiothoracic Transplantation and Mechanical Circulatory Support, Harefield Hospital, Royal Brompton and Harefield NHS Foundation Trust, London, UK

Abstract

Mechanical circulatory support appeared to provide us with time; time for recovery, for decision or for assessment. However they are known to be associated with different rates of mortality and morbidity. Impella device is a less invasive mechanical circulatory support but provides similar hemodynamic support compared with LVAD.

Advantages include respiratory wean and early mobilization, lower anticoagulation requirements and less invasive surgical technique. Implanting options are limited and depend on the calibre of the vessel. A Transaxillary approach need a minimum diameter of 6mm. Remaining options includes transfemoral percutaneous insertion or a cut down femoral approach.

Keywords: Impella; Transfemoral approach; Cardiogenic shock

Introduction

Mechanical circulatory support has gained a main role in the heart failure pantheon. Impella is a less invasive mechanical assist device but is able to provide similar haemodynamic support as long term assist devices [1]. Advantages of Impella include early mobilisation and respiratory wean, as well as lower anticoagulation requirements and less invasive surgical techniques. Herein we present the case of a 16 year old teenager with known diagnosis of familiar dilated cardiomyopathy.

Case Presentation

He presented to our unit with decompensated heart failure and chest pain. Despite optimal medical therapy including inotropic support he was in refractory cardiogenic shock. Therefore the decision was made to escalate his therapy using the Impella CP mechanical assist device as a bridge to heart transplantation.

Initially a transaxillary approach was attempted however this was abandoned due to small caliber of the vessel (less than 6 mm which is the minimum diameter required). Remaining options included a transfemoral percutaneous insertion or a cut down femoral approach. Given the small yet adequate size of the femoral arteries we decided to perform a cut down femoral approach.

Dissection and exposure of the vessel was followed by the anastomosis of a 6 mm Dacron graft that was tunnelled through a small incision in the upper thigh. After positioning the dedicated 0,025 inc wire into the left ventricle, the Impella was then railroaded into optimal position using transoesophageal echocardiography. The 14 french peel away sheath was not used in this case due to the size of the graft. A minimum graft of 8mm is needed in order to introduce this sheath [2]

OPEN ACCESS

*Correspondence:

Maria Monteagudo Vela, Department of Cardiothoracic Transplantation and Mechanical Circulatory Support, Harefield Hospital, Royal Brompton and Harefield NHS Foundation Trust, London, UK,
E-mail: m.monteagudo-vela@rbht.nhs.uk

Received Date: 18 Jun 2018

Accepted Date: 09 Jul 2018

Published Date: 12 Jul 2018

Citation:

Monteagudo Vela M, Garcia Saez D, Zych B, Simon A. Small Vessels, Big Solutions; Use of Graft Conduit to Facilitate Transfemoral Impella CP Implantation. Clin Surg. 2018; 3: 2009.

Copyright © 2018 Monteagudo Vela M. This is an open access article distributed under the Creative Commons Attribution License, which permits unrestricted use, distribution, and reproduction in any medium, provided the original work is properly cited.

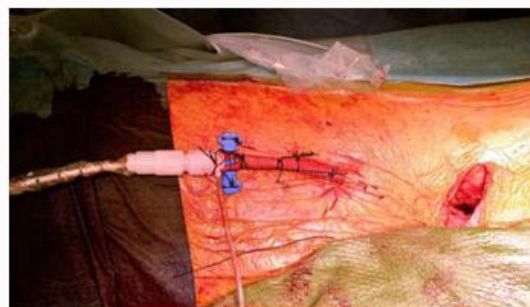


Figure 1: Minimum graft of 8mm is needed in order to introduce this sheath.




Figure 2: Wound was sutured and the Impella was started achieving.

(Figure 1).

The device was secured and fixed to the skin. The wound was sutured and the Impella was started achieving flows up to 3-3,5 l/min [3] (Figure 2).

Conclusion

This is the first time this technique for implantation of an Impella CP has been described. In our experience, when Impella CP's have been implanted using the percutaneous transfemoral approach as a bridge to long term mechanical assist devices or transplantation, we

were faced with the issue of continuous oozing from the insertion site leading to the development of groin haematomas and significant haemoglobin drops over the course of few days. This occurred despite uncomplicated ultrasound guided puncture and fluoroscopic guided insertion of the Impella in the catheter laboratory. The proposed technique can be used for patients with borderline size vessels who required Impella support as a bridge to destination therapy.

References

1. Ternus BW, Jentzer JC, El Sabbagh A, Eleid MF, Bell MR, Murphy JG, et al. Percutaneous Mechanical Circulatory Support for Cardiac Disease, Temporal Trends in Use and Complications Between 2009 and 2015. *J Invasive Cardiol.* 2017;29(9):309-13.
2. Product Manual for Impella 2.5, CP, 5.0, and LD Heart Pumps – Software v5.1.
3. Lauten A, Engström AE, Jung C, Empen K, Erne P, Cook S, et al. Percutaneous Left-Ventricular Support With the Impella-2.5-Assist Device in Acute Cardiogenic Shock. Results of the Impella-EUROSHOCK-Registry. *Circ Heart Fail.* 2013;6(1):23-30.