



Sister Mary Joseph Nodule: Analysis of a Case Series of Umbilical Metastases of Diverse Origin in a Single Centre

Clara Fernández Fernández, Alejandro Manrique Municio, Iago Justo Alonso, Virginia García-Moreno and Alberto A Marcacuzco Quinto*

General Surgery and Abdominal Organ Transplantation Unit, "12 de Octubre" Hospital, Spain

Abstract

Sister Mary Joseph nodule is an umbilical metastatic lesion. Its incidence is 1% to 3% in cases of abdominopelvic neoplasms, typically of gastrointestinal or genitourinary origin. Its presence indicates advanced malignancy. This lesion can manifest as a presenting sign as well as a revealing progression or recurrence of intra-abdominal malignancy. We analyzed retrospectively a case series of histologically diagnosed umbilical metastases in our centre between May 2010 and October 2020. The aim of the study was to analyze the clinical, analytical and histopathological characteristics of the umbilical nodules; as well as the patient survival. A total of 15 patients were diagnosed, 9 females and 6 males. The median age of diagnosis was 66 years. In 67% of cases, the finding was made at the time of diagnosis of the disease, and in 33% was a sign of recurrence or progression. Associated signs or symptoms were described in 60% of the patients. A surgical resection of the umbilical nodule was performed in 12 cases, and a core needle biopsy in 2 cases. Histological analysis revealed adenocarcinoma in 93%. The origin of the primary tumor was ovarian (53%), pancreaticobiliary (27%), bladder, mammary or prostatic. In 93% of the cases a simultaneous distant metastatic affection was histologically or cytologically confirmed. Umbilical metastasis is lesions that may go unnoticed and whose diagnostic delay could lead to a decrease in survival. Therefore, it is essential to carry out a thorough physical examination, analyze suspicious lesions and establish an individualized treatment.

OPEN ACCESS

*Correspondence:

Alberto A Marcacuzco Quinto, General Surgery and Abdominal Organ Transplantation Unit, "12 de Octubre" University Hospital and Department of Surgery, Complutense University, 4^a Planta Ctra, Andalucía Km 5, 4, 28041, Madrid, Spain, Tel: +34-91-3908294; Fax: +34-91-519271;

E-mail: alejandro_mq@yahoo.es

Received Date: 21 Jan 2021

Accepted Date: 19 Feb 2021

Published Date: 02 Mar 2021

Citation:

Fernández CF, Municio AM, Alonso IJ, García-Moreno V, Marcacuzco Quinto AA. Sister Mary Joseph Nodule: Analysis of a Case Series of Umbilical Metastases of Diverse Origin in a Single Centre. *Clin Surg.* 2021; 6: 3086.

Copyright © 2021 Alberto A Marcacuzco Quinto. This is an open access article distributed under the Creative Commons Attribution License, which permits unrestricted use, distribution, and reproduction in any medium, provided the original work is properly cited.

Keywords: Umbilical metastases; Sister Mary Joseph nodule; Pancreaticobiliary

Introduction

Sister Mary Joseph Nodule (SMJN) is an umbilical metastatic lesion. Its incidence is 1% to 3% in cases of abdominopelvic neoplasms [1]. Gastrointestinal origin is more frequent in men (50%), while genitourinary origin predominates in women (25%) [2,3].

The presence of this lesion constitutes an ominous prognostic factor, as it indicates advanced disease [1,2,4]. It can manifest as a presenting sign or symptom of intra-abdominal malignancy, being the first and only sign of an underlying disease in up to 30% of cases [5]; as well as revealing progression or recurrence [6].

The term "Sister Mary Joseph Nodule" was coined in 1949 by the English surgeon Hamilton Bailey in honor of Julia Dempsey (superintendent nurse at St. Mary's Hospital in Rochester, Minnesota, nowadays Mayo Clinic) who observed that patients with gastric carcinoma who presented with a hardened mass in the umbilicus, had a worse prognostic or a more premature death [5].

Materials and Methods

We analyzed retrospectively a case series of histologically diagnosed umbilical metastases in our centre between May 2010 and October 2020. The aim of the study was to analyze the clinical, analytical and histopathological characteristics of the umbilical nodules; as well as the patient's survival. All data was obtained from the electronic medical record.

Results and Discussion

Over this period, 15 patients were diagnosed, 9 females and 6 males. The median age of diagnosis was 66 years (42 to 84). In 67% of cases, the finding was made at the time of diagnosis of the disease, and in 5 patients (33%) was a sign of recurrence or progression.

Findings from physical examination are described in Table 1. The median size of the umbilical

Table 1: Characteristics of the clinical cases of umbilical metastases.

Case	Sex/Age (years)	Physical examination findings	Associated symptoms or signs	Nodule size (cm)	Tumoral markers	Diagnosis	Time of presentation	Surgery	Histological findings	Primary tumor	Other distant metastases	Survival (months)	Status
1	Female/ 69	NP	NP	2	NP	Intraoperative (suspected malignancy)	Simultaneous	Cytoreduction surgery + umbilical nodule resection	Undifferentiated adenocarcinoma	Ovary	Peritoneum, ascitic fluid	72	Dead
2	Male/ 56	Umbilical nodule, blood discharge	Dysphagia, constitutional syndrome, ascites	0,9	NP	Umbilical nodule biopsy (suspected malignancy)	Simultaneous	Umbilical nodule resection	Well-differentiated ductal adenocarcinoma	Pancreas	Ascitic fluid	2	Dead
3	Female/ 77	NP	No	2,4	Ca 125 347.10 U/ml	Intraoperative (suspected malignancy)	Simultaneous	Cytoreduction surgery + umbilical nodule resection	Undifferentiated adenocarcinoma	Ovary	Peritoneum, omentum, liver, large intestine, diaphragm	1	Dead
4	Male/ 83	NP	Abdominal pain	1,5	CEA 10.96 ng/ml, Ca 19.9 78.58 U/ml, Tripsina 878 ng/ml	Incidental	Simultaneous	Extended cholecystectomy + umbilical nodule resection	Moderately differentiated adenocarcinoma	Gallbladder	Peritoneum, omentum, liver	11	Dead
5	Female/ 61	NP	NP	0,9	Normal range	Intraoperative (suspected malignancy)	Simultaneous	Cytoreduction surgery + umbilical nodule resection	Undifferentiated adenocarcinoma	Ovary	Peritoneum, omentum	24	Dead
6	Female/ 45	NP	Abdominal pain	1,5	Ca 125 713 U/ml	Intraoperative (suspected malignancy)	Simultaneous	Cytoreduction surgery + umbilical nodule resection	Undifferentiated adenocarcinoma	Ovary	Ascitic fluid, peritoneo, IG, epiplón, lymph nodes	32	Alive
7	Female/ 42	Umbilical nodule, hard and focal ulceration	No	3	CEA 6.12 ng/ml	CNB (suspected malignancy)	Recurrence	No	Well-differentiated adenocarcinoma	Ovary	No	27	Alive
8	Female/ 49	NP	Abdominal pain, ascites	2	Ca 125 1830 U/ml, CEA 15.3 300.5 ng/ml	Intraoperative (suspected malignancy)	Simultaneous	Cytoreduction surgery + umbilical nodule resection	Undifferentiated adenocarcinoma	Ovary	Peritoneo, epiplón, lymph nodes	18	Alive
9	Female/ 65	NP	NP	1	Normal range	Intraoperative (suspected malignancy)	Simultaneous	Cytoreduction surgery + umbilical nodule resection	Undifferentiated adenocarcinoma	Ovary	Lung, peritoneum, stomach, liver, small intestine, omentum	51	Alive
10	Male/ 84	Umbilical nodule, ulceration, and blood discharge	No	2,5	Ca 19.9 4289 U/ml	Intraoperative (suspected malignancy)	Simultaneous	Exploratory laparoscopy + umbilical nodule resection	Moderately differentiated adenocarcinoma	Pancreas	Liver	5	Dead
11	Female/66	Incarcerated umbilical hernia	Abdominal pain, ascites	0,3	Normal range	Incidental	Progression	Umbilical hernioplasty + umbilical nodule resection	Lobular carcinoma	Breast	Retroperitoneum, lung, stomach	5	Dead
12	Female/57	Umbilical nodule, blood discharge	Abdominal pain	6	Ca 125 1437 U/ml	CNB (suspected malignancy)	Simultaneous	No	Adenocarcinoma	Ovary	Peritoneum, lymph nodes	11	Alive
13	Male/79	Abdominal distension	Abdominal pain	1,4	Normal range	Incidental	Progression	Exploratory laparotomy + umbilical nodule resection	Undifferentiated adenocarcinoma	Bladder	Peritoneum	3	Dead
14	Male/68	Umbilical hernia	Abdominal pain	1,0	Ca 19.9 196 U/ml	Intraoperative (suspected malignancy)	Progression	Umbilical hernioplasty + umbilical nodule resection	Well-differentiated adenocarcinoma	Pancreas	Peritoneum, liver	12	Dead
15	Male/84	Umbilical hernia, hardening, erythema	Abdominal pain	0,3	PSA 267.6	Incidental	Progression	Umbilical hernioplasty + umbilical nodule resection	Adenocarcinoma	Prostate	Peritoneum	2	Alive

CEA: Carcinoembryonic Antigen; CNB: Core Needle Biopsy; NP: Not Provided

nodes was 2.4 cm (0.3 to 11). It is most common to find nodules smaller than 2 cm; however, nodules up to 10 cm in size have been reported [3,5]. These lesions have been described in medical literature as irregular nodes with an altered coloration, hardened, pruriginous, ulcerated or with variable discharge [3,5,6]. Unless there is skin ulceration, it is usually a painless lesion [5].

In our series, associated signs or symptoms were described in 60% of the patients, predominantly pain and abdominal distension secondary to ascites. Notably, in 40% of the cases a thorough

examination was not carried out or the findings were not documented in the medical record.

The signs or symptoms commonly reported in the literature are nonspecific but may suggest the presence of an underlying malignancy, such as anorexia, weight loss, nausea or vomiting, abdominal pain or ascites [5] as well as gastrointestinal bleeding or abdominal mass [3]. In the case of history of a previously treated tumoral disease, it is essential to have a high index of suspicion [2].

In some cases, the suspected diagnosis is supported by findings on

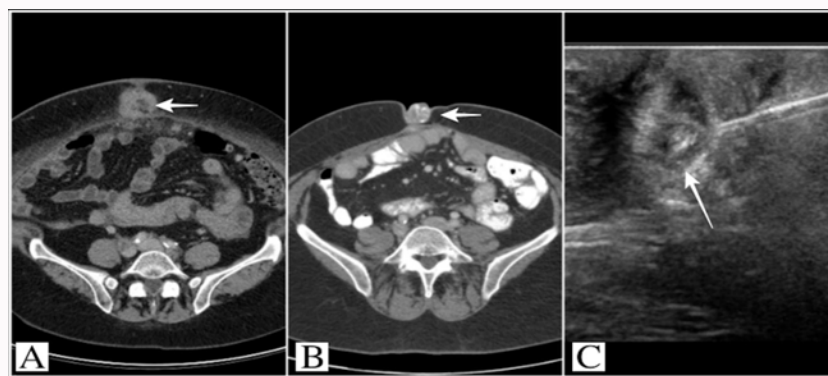


Figure 1: A and B) Images of CT axial sections showing the SMJN (arrows) and C) Ultrasound-guided core needle biopsy of an umbilical nodule.

imaging tests, such as ultrasonography, magnetic resonance imaging, or computed tomography [2,3,6]. When a SMJN is suspected, it is necessary to reach a definitive diagnosis, either by biopsy of the lesion or by needle aspiration cytology [3,7].

To perform the anatomopathological examination, a surgical resection of the umbilical node was performed in 13 cases (87%), mainly in the context of cytoreductive surgery for ovarian cancer (6 cases); and a core needle biopsy in 2 cases (Figure 1). Furthermore, in 4 cases (27%) the finding of umbilical metastases was incidental.

Studies have reported the stomach to be the most common origin of the primary tumor in men, and the ovary in women [1,3,5]. Adenocarcinoma is the most usually histopathological type found, described in approximately 75% of cases; other types described are epidermoid and undifferentiated tumors [3,5,7]. In this review, histological analysis revealed adenocarcinoma in 93%, half of them poorly differentiated. The origin of the primary tumor was ovarian (53%), pancreaticobiliary (27%), bladder, mammary or prostate.

The delay in the diagnosis of this entity and therefore in the treatment of the underlying malignancy may lead to a decrease in survival, being the analysis of those suspicious lesions fundamental [3].

Diverse dissemination mechanisms to the umbilicus have been described given its anatomical relationships. The most common way of umbilical involvement is considered to be by extension from the adjacent peritoneum [5], with cases of metastases described in patients with a previous umbilical hernia [4]. Lymphatic spread may occur via the superficial or deep node systems from the axillary, inguinal, para-aortic, intern mammary or external iliac nodes. Another way of dissemination could be through the embryonic remnants that conform ligaments that are attached to the umbilicus such as the omphalomesenteric duct, the urachus or the round ligament of the liver; or by hematogenous dissemination either arterial or venous [5,8]. Furthermore, there is a possibility of iatrogenic tumor implantation after laparoscopic surgery [3,4].

Differential diagnosis should be made with existing entities such as endometriosis, foreign body granuloma, omphalitis, umbilical hernia; as well as benign or malignant tumors from skin origin [7]. Nonetheless, in 15% to 30% of cases primary origin is unknown [3].

The prognosis of the disease is determined by the origin of the primary tumor [9], and could be influenced by the moment in which the umbilical node is diagnosed (before or after the diagnosis of the

neoplasia) [5]. Other factors, such as immunosuppression, could be risk factors for tumor dissemination [7].

Survival from the time of diagnosis of metastases is variable (2 to 11 months), being higher in the case of ovarian neoplasms; and it could be increased with chemotherapy or surgical resection of the primary tumor [3,6,9,10]. Survival greater than 2 years has been reported in less than 15% of cases [3].

In this study, in 93% of cases simultaneous distant metastatic affection was histologically or cytologically confirmed. In deceased patients, the median survival was 5 months (1 to 72), a higher survival rate was observed in patients diagnosed with ovarian cancer.

Treatment varies according to the origin [2,5]. It is often palliative given the extent of the disease at the time of diagnosis, but more aggressive measures may be taken in selected patients [2].

Conclusion

In conclusion, umbilical metastasis is lesions that could go unnoticed and whose diagnostic delay could lead to a decrease in survival. Therefore, it is essential to carry out an in-depth physical examination, analyze suspicious lesions and establish an individualized treatment.

References

1. Touraud JP, Lentz N, Dutronc Y, Mercier E, Sagot P, Lambert D. [Umbilical cutaneous metastasis (or Sister Mary Joseph's nodule) disclosing an ovarian adenocarcinoma]. *Gynecol Obstet Fertil.* 2000;28(10):719-21.
2. Tso S, Brockley J, Recica H, Ilchysyn A. Sister Mary Joseph's nodule: An unusual but important physical finding characteristic of widespread internal malignancy. *Br J Gen Pract.* 2013;63(615):551-2.
3. Chalya PL, Mabula JB, Rambau PF, Mchembe MD. Sister Mary Joseph's nodule at a University teaching hospital in northwestern Tanzania: A retrospective review of 34 cases. *World J Surg Oncol.* 2013;11:151.
4. Dubreuil A, Domp Martin A, Barjot P, Louvet S, Leroy D. Umbilical metastasis or Sister Mary Joseph's nodule. *Int J Dermatol.* 1998;37(1):7-13.
5. Abu-Hilal M, Newman JS. Sister Mary Joseph and her nodule: Historical and clinical perspective. *Am J Med Sci.* 2009;337(4):271-3.
6. Palaniappan M, Jose WM, Mehta A, Kumar K, Pavithran K. Umbilical metastasis: A case series of four Sister Joseph nodules from four different visceral malignancies. *Curr Oncol.* 2010;17(6):78-81.
7. Panaro F, Andorno E, Di Domenico S, Morelli N, Bottino G, Mondello R, et al. Sister Joseph's nodule in a liver transplant recipient: Case report and mini-review of literature. *World J Surg Oncol.* 2005;3(1):4.

8. Barrow M. Metastatic tumors of the umbilicus. *J Chronic Dis.* 1996;19(10):1113-7.
9. Gabriele R, Conte M, Egidi F, Borghese M. Umbilical metastases: Current viewpoint. *World J Surg Oncol.* 2005;3(1):13.
10. Ozaki N, Takamori H, Baba H. Sister Mary Joseph's nodule derived from pancreatic cancer. *J Hepatobiliary Pancreat Sci.* 2011;18(1):119-21.