



## Salvage Therapy for Recurrent Gastrojejunal Anastomotic Stricture Using a Lumen Apposing Metal Stent

Edward C Oldfield IV<sup>1\*</sup> and Parth J Parekh<sup>2</sup>

<sup>1</sup>Department of Internal Medicine, Division of Gastroenterology and Hepatology, University of Virginia, USA

<sup>2</sup>Department of Internal Medicine, Division of Gastroenterology, Eastern Virginia Medical School, USA

### Abstract

Gastrojejunostomy anastomotic stricture following Roux-en-Y gastric bypass is a common complication of the surgery, which can result in significant morbidity and impaired quality of life for patients. Past endoscopic interventions have been limited in their durability of response, in particular for recurrent strictures. Here, we illustrate the use of a lumen-apposing metal stent with endoscopic suturing for long-term management of a gastrojejunostomy anastomotic stricture after failed balloon dilation with excellent patient outcome at 6 months follow stent removal.

### Introduction

Gastrojejunostomy anastomotic stricture following Roux-en-Y gastric bypass is a well-known complication of the surgery with reported ranges varying from 2.9% to 23% [1-3]. Unfortunately, prior endoscopic interventions for these strictures have had limited durability of treatment response.

### Case Presentation

A 71-year-old male with previous Roux-en-Y gastric bypass presented to our hospital with 2 weeks of nausea, vomiting, weight loss, and severe hypoglycemia. Initial imaging with CT abdomen showed a fluid-filled and distended gastric pouch with likely stenosis of the Gastrojejunostomy (GJ) anastomosis. An upper GI series was performed which confirmed significant stenosis at the GJ anastomosis (Figure 1A). An EGD was performed during which the stricture was successfully dilated using a Through-The-Scope (TTS) 6-7-8 mm and then an 8-9-10 mm balloon dilator (Figure 2). Unfortunately, the patient did not clinically respond to dilation and required total parenteral nutrition due to inability to advance diet beyond liquids. Subsequently, the patient underwent a repeat EGD with placement of a 20 mm × 10 mm Lumen Apposing Metal Stent (LAMS) (Axios, Boston Scientific) under fluoroscopic guidance. The stent was successfully dilated with a Through-The-Scope (TTS) 12-13.5-15 mm balloon dilator to a maximal size of 13.5 mm with obliteration of the waist. The LAMS was then sutured into place with the endoscopic suturing device (Over Stitch, Apollo Endosurgery, Inc) using 2.0 non absorbable sutures and placing 2 interrupted sutures with cinches on both ends (Figure 3). An upper GI series was repeated 24 h after LAMS, which showed excellent functioning of the stent without leak or obstruction (Figure 1B). Over the next five days, the patient's symptoms abated, diet was gradually advanced to low residue diet, TPN was discontinued, and the patient was discharged home. In the interval 6 months, the patient experienced no recurrence of his symptoms and was tolerant of a regulation diet. A repeat EGD was performed

### OPEN ACCESS

#### \*Correspondence:

Edward C Oldfield IV, Department of Internal Medicine, Division of Gastroenterology and Hepatology, University of Virginia, PO Box: 800708, Charlottesville, VA 22908-0708, USA, E-mail: eco4mz@virginia.edu

Received Date: 24 Jun 2020

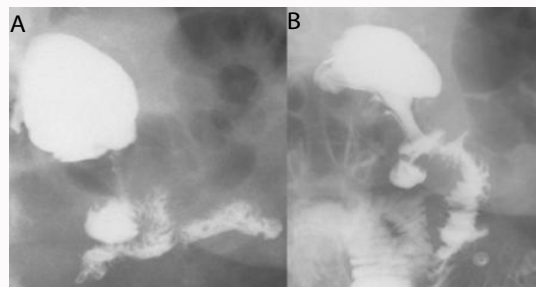
Accepted Date: 25 Jul 2020

Published Date: 31 Jul 2020

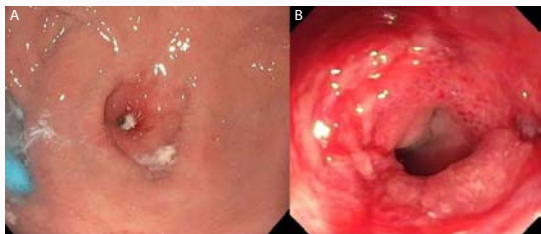#### Citation:

Edward C Oldfield IV, Parekh PJ. Salvage Therapy for Recurrent Gastrojejunal Anastomotic Stricture Using a Lumen Apposing Metal Stent. *Clin Surg.* 2020; 5: 2894.

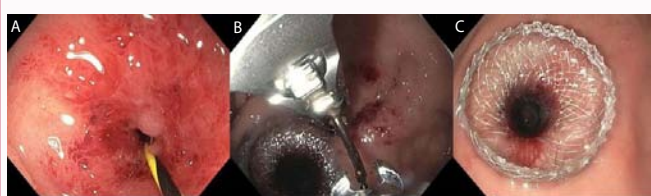
Copyright © 2020 Edward C Oldfield IV. This is an open access article distributed under the Creative Commons Attribution License, which permits unrestricted use, distribution, and reproduction in any medium, provided the original work is properly cited.



**Figure 1:** A) Preintervention Upper GI series showing significant stenosis at the GJ anastomosis with only a threadlike amount of contrast flowing through. B) Postintervention GJ anastomotic stricture post-LAMS placement with optimal stent location and excellent contrast flow through.



**Figure 2:** A) GJ anastomotic stricture pre-balloon dilation. B) GJ anastomotic stricture post-balloon dilation.



**Figure 3:** A) GJ anastomotic stricture post-balloon dilation, pre-LAMS placement. B) Endoscopic suturing device in place. C) GJ anastomotic stricture with visible jejuna lumen after LAMS placement and balloon dilation.

at 6 months for removal of the LAMS; endoscopic evaluation at that time showed healthy anastomosis with patent opening.

## Discussion

Management of these GJ anastomotic strictures has primarily been pneumatic balloon dilation or fully covered self-expanding metal or plastic stents; however, dilation is unlikely to achieve

lasting response and other stents are associated with complications of stent migration and recurrence of symptoms after removal [4]. Previous case reports have documented successful treatment of GJ anastomotic strictures using LAMS with excellent response given its novel shape and anchoring phalanges [5]. We further show the successful endoscopic suturing of the LAMS, which allowed for prolonged time for stent placement with enhanced risk-mitigation for stent migration. Importantly, this noninvasive endoscopic approach to stricture management likely prevented our patient from a surgical revision of his anastomosis or need for percutaneous gastrostomy for enteral nutrition.

## References

1. Alasfar F, Sabnis AA, Liu RC, Chand B. Stricture rate after laparoscopic Roux-en-Y gastric bypass with a 21-mm circular stapler: The Cleveland clinic experience. *Med Princ Pract.* 2009;18(5):364-7.
2. Mathew A, Veluona MA, DePalma FJ, Cooney RN. Gastrojejunal stricture after gastric bypass and efficacy of endoscopic intervention. *Dig Dis Sci.* 2009;54(9):1971-8.
3. Takata MC, Ciovia R, Cello JP, Posselt AM, Rogers SJ, Campos GM. Predictors, treatment, and outcomes of gastrojejunostomy stricture after gastric bypass for morbid obesity. *Obes Surg.* 2007;17(7):878-84.
4. Choi WJ, Park J-J, Park J. Effects of the temporary placement of a self-expandable metallic stent in benign pyloric stenosis. *Gut Liver.* 2013;7(4):417-22.
5. Mansoor MS, Tejada J, Parsa NA, Yoon E, Hida S. Off label use of lumen-apposing metal stent for persistent gastro-jejunal anastomotic stricture. *World J Gastrointest Endosc.* 2018;10(6):117-20.