



Role of Laparoscopy in Treatment of Uterine Arteriovenous Malformation After Failure of Uterine Arteries Embolization

Litta P, Stella A, Tamagnini M*, Bonora M and Vassallo L

Department of Women and Children's Health, Unit of Gynecology and Obstetrics, University of Padua, Italy

Abstract

Uterine Arteriovenous Malformation (AVM) is an uncommon, potentially life-threatening condition, and the primary therapeutic method is embolization. We describe a case of a 33-year-old woman with acquired uterine AVM accompanied by abnormal vaginal bleeding. The diagnosis was established by Doppler flow ultrasonography and angiography. Because this uterine AVM was extensive, uterine arterial embolization was not conclusive. We, therefore, employed a combined method under hysteroscopy and laparoscopy, in which the uterine cavity and AVM are first assessed, and then the uterine myometrial lesion is resected with a harmonic scalpel. Finally, the uterus was reconstructed with an intact uterine cavity. Abnormal vaginal bleeding was successfully stopped after the operation. This method is suitable for the treatment of uterine AVM in women wishing to preserve their fertility.

Introduction

Uterine Arteriovenous Malformation (AVM) is an uncommon but potentially life-threatening lesion. Among FIGO classification of Abnormal Uterine Bleeding (AUB), it is included under the AUB-N category (Not Otherwise Specified). AVM is characterized by shunts between myometrial arteries and veins without an intervening capillary system and can be classified as either congenital or acquired, with the latter more common. Acquired AVM origins after trauma, miscarriage, voluntary pregnancy termination, Dilatation and Curettage (D&C), caesarean section, vaginal delivery, uterine infection, endometriosis, and trophoblastic disease.

Hysterectomy has been the main treatment for many years; since the majority of women affected by this condition are of childbearing age, hysterectomy has been questioned. Among the fertility-sparing procedures, hysteroscopy and unilateral Transcatheter Artery Embolization (TCE) of the uterine artery provided alternative treatment options. Clinically AVM can appear as profuse menorrhagia or metrorrhagia. Bleeding is often intermittent and faucet-like. Patients may also present anemia and hypotension secondary to acute blood loss. Other common complaints are vague pelvic discomfort, urinary symptoms like polyuria and incontinence, and dyspareunia. Congestive Heart Failure (CHF) secondary to the shunting of blood to the venous system is possible but rare.

In this case report, we described a laparoscopic excision of the myometrium affected by AVM after the failure of Transcatheter Embolization (TCE) of the uterine artery.

Case Presentation

A healthy 33 years old woman came to our attention because of persistent vaginal bleeding. Her medical history was unremarkable. G1P1. On the 29th of September 2021, she underwent uterine curettage for a miscarriage at 8th gestational weeks. She had vaginal bleeding constantly until a faucet-like episode on the 20th of October, which required medical evaluation. The Transvaginal Ultrasound (TVU) showed residual chorionic material and an image resembling arteriovenous malformation. On the 12th of November, a CT angiography was performed, showing twisting and dilated uterine vessels on both sides of the uterus, penetrating through the myometrium toward the fundus. Imaging showed a "nidus" from which the venous drainage gave rise to a pelvic varicocele. AVM nourishment stemmed from the right uterine branch, whereas the left uterine branch was not involved. Six days later the patient underwent right uterine artery embolization using Onyx 18. At the end of the procedure, AVM was no longer present, nor was immediate collateral vascularization.

OPEN ACCESS

*Correspondence:

Matteo Tamagnini, Department of Women and Children's Health, Unit of Gynecology and Obstetrics, University of Padua, 35100 Padua, Italy,

Received Date: 05 Jun 2024

Accepted Date: 20 Jun 2024

Published Date: 03 Jul 2024

Citation:

Litta P, Stella A, Tamagnini M, Bonora M, Vassallo L. Role of Laparoscopy in Treatment of Uterine Arteriovenous Malformation After Failure of Uterine Arteries Embolization. *Clin Surg*. 2024; 9: 3715.

Copyright © 2024 Tamagnini M. This is an open access article distributed under the Creative Commons Attribution License, which permits unrestricted use, distribution, and reproduction in any medium, provided the original work is properly cited.

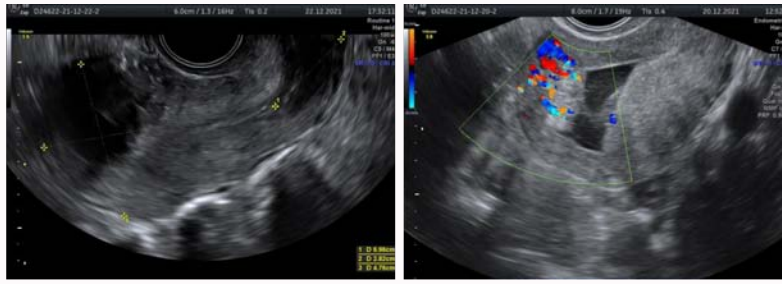

Figure 1: Endovaginal pelvic ultrasound. Axial view of the uterus with its dimensions (A, on the left). Sagittal view of the uterus with Color Doppler appearance. Image of AVM of the anterior wall (B, on the right).

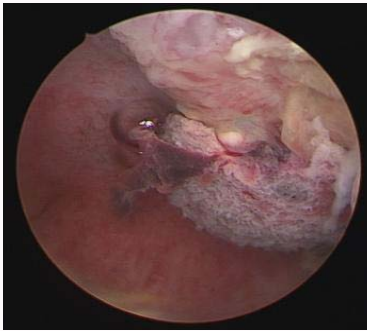

Figure 2: Hysteroscopy showing RPC adherent to the anterior uterine wall.

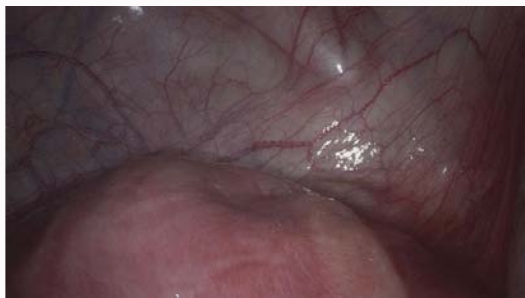

Figure 3: Depressed area on the anterior wall suggestive of AVM. Loss of consistency due to reduction of muscular component in the myometrium affected.

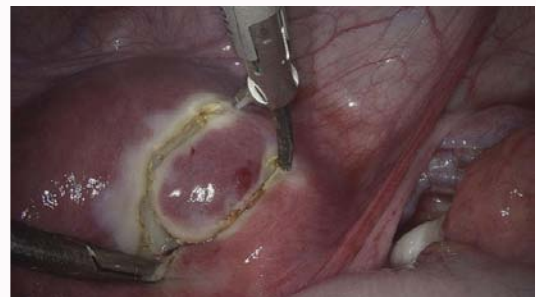

Figure 4: Identification of the area affected by AVM using harmonic scalpel.

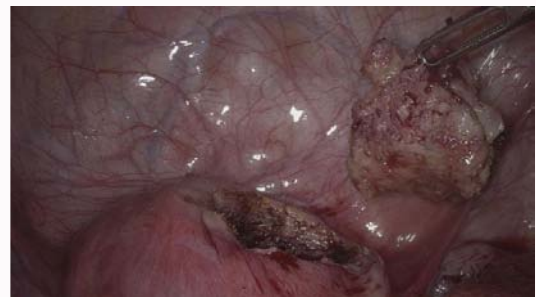

Figure 5: Full thickness myometrium excision by laparoscopy. The specimen includes the entire extension of AVM.

On the 30th of November, a TVU showed decidual remnants and the presence at the anterior uterine wall of 3 vessels running across the myometrium and reaching the endometrium lining. The main vessel's caliber was 2.3 mm. Progestin-only pill (Norethisterone acetate 10 mg per day) was prescribed. The patient took methylergometrine for 6 days before she came to our attention on the 20th of December 2021, without resolution of the bleeding. She was hemodynamically stable, blood counts were as follows: Hemoglobin 134 g/L, White Blood Cells (WBC) $7.1 \times 10^9/L$, hematocrit 42%, platelets $370 \times 10^9/L$, PT 1.0, aPTT 27 sec, glucose blood level 75 mg/dl, creatinine blood level 0.73 mg/dl, sodium 141 mmol/L, potassium 4.1 mmol/L, hCG level negative. TVU documented a uterus normal in shape and dimension; at the level of the fundus, an image suggestive of chorionic remnants and an area of chaotic high-flow vascularization to full thickness on the anterior uterine wall were found, reaching the endometrium lining (Figure 1A, 1B). Doctors decided to perform a diagnostic hysteroscopy to evaluate the formation inside the uterine cavity (Figure 2). Informed consent was taken for diagnostic hysteroscopy, laparoscopic resection of the myometrium involved by

AVM until laparoscopic subtotal hysterectomy. The remnants were removed without using bipolar energy to avoid any other damage to the endometrium lining. Hysteroscopy was followed by laparoscopic excision of the uterine portion affected by AVM, then sutured with late absorbable stitches. Eventually, a second hysteroscopy was performed to assess the integrity of the uterine cavity after the excision. The patient recovered well and after 24 h of observation discharged.

Discussion

AVM is an abnormal connection between an artery and a vein that bypasses the capillary system. In this condition, high-pressure pulsating arterial blood flows directly into the venous system, triggering a subsequent hemodynamic change in the vein that undergoes a process of arterialization. Despite the attempted vessel wall adaptation, rupture and hemorrhage are right behind the corner. Bleeding from an AVM is precipitated by the physiological alterations that characterize the endometrium every month. The hormone-controlled shedding and re-vascularization of this tissue make the AVM that abuts the endometrium particularly prone to bleeding [1].

AVM has been classified as congenital or acquired. The true incidence is unknown, with just 100 cases reported in the literature at

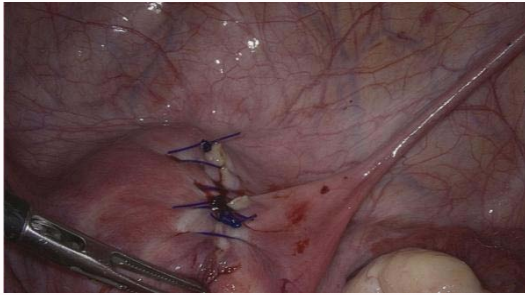


Figure 6: Uterine reconstruction with a double layer of late absorbable stitches.

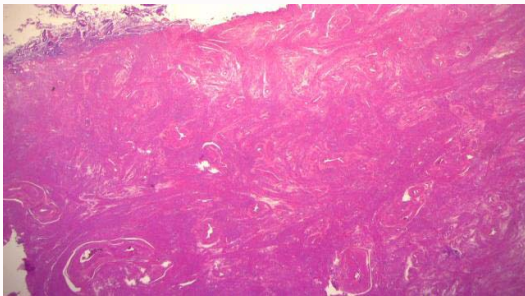


Figure 7: Piece of the myometrium, full thickness (1.25X). The endometrium is above, the thickened myometrium contains numerous medium caliber vessels with irregular distribution, dilated, tortuous and with a thickened wall.

the beginning of the 2000s.

AVM represents a niche among all uterine malformations. Congenital one results from a defect in the differentiation of the primitive capillary plexus during fetal angiogenesis [2]. Acquired AVM mostly occurs after damage to the uterine tissue and is associated with pregnancy, uterine surgery procedures like cesarean section, and curettage; less frequently, with cervical and endometrial carcinoma, infections, exposure to diethylstilbestrol [3-5].

The association of pregnancy-worsening of symptoms may be explained by the trophoblast angiogenic attitude and suggest a hormonal mechanism. Elevated human chorionic gonadotropin may play a role in the proliferation of otherwise latent AVMs. Thus, AUB after miscarriage may be due to Retained Product of Conception (RPC), non-obliteration and subinvolution of the blood vessels of the placental bed, and secondary to AVM formation [2]. Timmerman et al. [6] suggest that AVMs represent a subinvolution of the placental bed with failed obliteration of vessels in the absence of RPC after cessation of the pregnancy. If so, uterine cavity curettage must be avoided as this procedure could prompt severe uncontrolled bleeding.

Clinically AVM can cause irregular uterine bleeding and even massive uterine hemorrhages. The patient may also present anemia and hypotension secondary to acute blood loss, often outlined as faucet-like bleeding. In a systematic review bleeding was reported in 84% of patients with AVM, and in 30% blood transfusion was necessary [7]. Less commonly the patient complains of vague pelvic discomfort, urinary symptoms and dyspareunia. The patient may alternatively remain asymptomatic despite the presence of a uterine AVM, developing symptoms following uterine trauma or secondary to hormonal changes related to pregnancy or menstrual cycle.

Although in the past uterine artery angiography was the gold standard for diagnosis, presently transvaginal Grey-scale and Color

Doppler ultrasound evaluation is emerging as the simplest, best, and most cost-effective diagnostic imaging modalities [8]. A large hypochoic area within the myometrium, with bidirectional high-velocity blood flow, raises suspicion for uterine AVM and should clue the physician to obtain additional imaging [9]. The severity of the vascular malformation is expressed by the velocity of the blood flow measured as PSV and the resistance that the vessel wall poses to the blood flow expressed in the "resistance index." Depending on the PSV of the blood flow and the vessel's resistance index and on the severity of clinical symptoms, the care provider can triage patients at different levels of risk because of bleeding and select the appropriate treatment [10]. Anyway, an in-depth review of the subject published in 2014 angiography continues to be considered the gold standard to diagnose the pathologic condition.

The treatment of AVM mainly depends on the patient's age, symptoms, desire for fertility and the site of the lesion. Tranexamic acid, progestin, combined oral contraceptive, ergot alkaloids, Gonadotropin-Releasing Hormone (GnRH) agonist and Danazol are used in conservative medical treatment. Bleeding can be unresponsive to medical therapy. Because AVM mostly affects women of childbearing age, demolition procedures should be avoided. Hysterectomy has been proposed as an effective treatment in the past, regardless of the age of the patients and their desire for pregnancy. Today this approach cannot be justified as a primary treatment strategy for women who desire pregnancy.

Transcatheter Embolization (TCE) of the uterine artery has been described since the late 1980s as a less invasive treatment option for patients wishing to preserve fertility. Yoon et al. [2] made a systematic review of a total of 40 studies, comprising 54 patients (average age of 33.4 years) from 2003 to 2013. TCE had a primary success rate with symptomatic control of 61% (31 patients) and a secondary success rate of 91% after repeated embolization. Concerning unilateral/bilateral artery embolization, the decision should be determined by the angiographic appearance of the arterial supply to the AVM, that is to say, whether one or both uterine arteries are involved in the nourishment of the vascular malformation. Twenty-two (22) patients (41%) underwent unilateral embolization and the other 32 (59%) underwent bilateral embolization. They also found a higher rate of repeat embolization for the bilateral approach TCE. They speculated that it was due to larger or more deeply involved vascular lesions.

Although TCE has been proposed as a valid alternative for childbearing women wishing to preserve their fertility, postprocedural consequences and management must be carefully taken into account. Among 54 cases reviewed, there were no major complications. Pelvic pain or cramping, which were the most common side effects, were developed in 6 patients, however, self-limited or controlled by opioids or acetaminophen. One patient with a postprocedural self-limited fever. Other reported complications to include were nausea, leukocytosis and complications related to standard angiographic technique, such as puncture site hematoma, iatrogenic vessel dissection, and contrast-induced nephrotoxicity. Even if those consequences were self-limited, they prolonged hospitalization.

Actually, the pregnancy rate after treatment of AVM by Uterine Artery Embolization (UAE) varies in published reports, ranging from 17.4% in observational studies to 27% in case reports [11]. Pregnancies after UAE may be complicated by spontaneous abortion, placenta previa or accreta, postpartum hemorrhage, and a higher caesarean section rate than in the general population.

Hysteroscopy is an alternative approach among fertility-sparing treatments for uterine arteriovenous malformation.

Calzolari et al. [12] published a retrospective study of 11 women with ultrasound diagnosis of AVM treated by hysteroscopy approach, 10 of 11 were caused by uterine curettage due to abortion. Greyscale ultrasound and Power Doppler technique have been used to evaluate and characterize the lesion as a mass of multiple cystic or tubular hypoechoic areas in the context of the myometrial and endometrial junctions. Color Doppler ultrasonography was added to visualize the uterus's vascularization and can demonstrate the vascular nature of AVMs. Peak systolic velocity was used to determine the necessity of hysteroscopic treatment. He claimed total resolution of symptoms and no complications during the surgery and throughout the follow-up.

Laparoscopic management of AVM has been used to avoid demolishing treatments. Levy-Zaubermann et al. [13] described the first case report of laparoscopic ligation of both internal iliac arteries. Initially, the diagnosis was made by angiography that showed vascularization of the uterine AVM *via* both the right and left uterine arteries. They attempted 2 bilateral embolization procedures in 6 days, with non-resorbable glue. Nevertheless, the symptomatology persisted. After the failure of expectant management and the persistence of AVM 6 weeks later, occlusion of the internal iliac arteries and the round ligaments of the uterus was performed by laparoscopy with non-resorbable clips. At 1 month follow-up, an ultrasound scan showed complete regression of the AVM.

Patton et al. [14] presented a fertility-preserving approach in the management of AVM resistant to endovascular management. Doppler ultrasound demonstrated the recanalization of the AVM. Ultimately, laparoscopic resection of the AVM was performed after laparoscopic ligation of the uterine arteries.

In our case, the hysteroscopic approach could not result in a complete resolution of the malformation without jeopardizing the integrity of the uterus. In fact, hysteroscopic removal of the lesion by the *Slicing technique* determines a reduction of the integrity of the myometrium affected by the lesion, and depending on the size of the MAV, residual myometrium thickness can be very low. The integrity of the uterus is crucial for women in their childbearing age to avoid any rupture during pregnancy. In addition, any incomplete hysteroscopic removal of MAV can be linked to abnormal placental insertion. The trophoblast is characterized by a marked angiotropism, and it seems reasonable to think that the trophoblast and the subsequent placenta can insert at the level of the residual MAV, leading eventually to the spectrum of anomalous placenta insertions.

We chose a laparoscopic approach with the aim of complete removal of AVM. During the laparoscopy the area affected by the lesion can be recognized as a hollow on the surface of the uterus due to the loss of consistency; the color also changes, from pink to bluish, as the anomalous vessels emerge in the serosa of the uterus (Figure 3). AVM excision is performed by a harmonic scalpel (Figures 4, 5). At the microscope, the specimen of myometrium was involved from the inner to the outer surface, supporting the surgical strategy (Figure 6). The integrity of the uterus is still ensured by a double-layer suture comparable to a laparoscopic myomectomy. Histology confirmed the full-thickness involvement by AVM (Figure 7).

Conclusion

Arteriovenous malformations are uncommon uterine lesions

with life-treating potential. Uterine bleeding can be irresponsive to medical treatment and can require surgical intervention; furthermore, the application of improper surgical procedures can prompt uncontrolled bleeding. The criterion standard for diagnosis is transvaginal ultrasound and arteriography, usually obtained after CT angiography.

In our opinion, *the critical point* is to evaluate the entire extension of MAV within the thickness of the myometrium involved. We think that uterine MAV can involve the full thickness of the myometrium, and as a consequence, the diagnostic and operative hysteroscopic approach must be linked to the laparoscopy. The evaluation of the uterine cavity and the area involved by the AVM is made by diagnostic hysteroscopy, whereas operative hysteroscopy allows the removal of the trophoblastic remnant's adherent to the uterine wall. The role of the diagnostic laparoscopy is to evaluate the morphology of the uterus: Its consistency can be assessed through the touch of the instrument, and the presence of a "fovea" on the serosa matches the loss of compactness proper of the AVM area. Actually, the excision of the entire lesion and the subsequent proper uterine reconstruction is guaranteed by the operative laparoscopy. For those reasons, laparoscopy is mandatory.

We do not agree with our colleagues who claimed complete resolution of AVM with the hysteroscopic approach only. In fact, they could not assess the consistency of the uterus by laparoscopy as we described and they probably missed the outer part of the AVM, leaving a portion of the uterus weaker.

We have described a novel alternative surgical treatment that couple's hysteroscopy and laparoscopy with the aim of completely removing the lesion, thus preserving fertility for patients with refractory AUB and recanalization of the uterine AVM despite previous TCE procedures. As the area affected by the AVM is totally removed, we avoid any further source of AUB and any abnormal placentation for future pregnancy, without reducing uterine integrity.

References

1. Clarke JA, Viswanatha RK, Hamid R, Sankaranarayanan S. Diagnosis and management of life-threatening hypermenorrhagia caused by uterine arteriovenous malformation secondary to surgical termination of pregnancy: Video evidence! *BMJ Case Rep.* 2012;2012:bcr2012007368.
2. Yoon DJ, Jones M, Taani JA, Buhimschi C, Dowell JD. A systematic review of acquired uterine arteriovenous malformations: Pathophysiology, diagnosis, and transcatheter treatment. *AJP Rep.* 2016;6(1):e6-e14.
3. Diwan RV, Brennan JN, Selim MA, McGrew TL, Rashad FA, Rustia MU, et al. Sonographic diagnosis of arteriovenous malformation of the uterus and pelvis. *J Clin Ultrasound.* 1983;11(5):295-8.
4. Huang MW, Muradali D, Thurston WA, Burns PN, Wilson SR. Uterine arteriovenous malformations: Gray-scale and Doppler US features with MR imaging correlation. *Radiology.* 1998;206(1):115-23.
5. Ghi T, Giunchi S, Rossi C, Pilu G, Savelli L, Mollo F, et al. Three-dimensional power Doppler sonography in the diagnosis of arteriovenous malformation of the uterus. *J Ultrasound Med.* 2005;24(5):727-31.
6. Timmerman D, Van den Bosch T, Peeraer K, Debrouwere E, Van Schoubroeck D, Stockx L, et al. Vascular malformations in the uterus: Ultrasonographic diagnosis and conservative management. *Eur J Obstet Gynecol Reprod Biol.* 2000;92(1):171-8.
7. Manolitsas T, Hurley V, Gilford E. Uterine arteriovenous malformation-- A rare cause of uterine hemorrhage. *Aust N Z J Obstet Gynaecol.* 1994;34(2):197-9.

8. Timor-Tritsch IE, Haynes MC, Monteagudo A, Khatib N, Kovács S. Ultrasound diagnosis and management of acquired uterine enhanced myometrial vascularity/arteriovenous malformations. *Am J Obstet Gynecol.* 2016;214(6):731.e1-731.e10.
9. Scribner D, Fraser R. Diagnosis of acquired uterine arteriovenous malformation by Doppler ultrasound. *J Emerg Med.* 2016;51(2):168-71.
10. Timmerman D, Wauters J, Van Calenbergh S, Van Schoubroeck D, Maleux G, Van Den Bosch T, et al. Color Doppler imaging is a valuable tool for the diagnosis and management of uterine vascular malformations. *Ultrasound Obstet Gynecol.* 2003;21(6):570-7.
11. Peitsidis P, Manolagos E, Tsekoura V, Kreienberg R, Schwentner L. Uterine arteriovenous malformations induced after diagnostic curettage: A systematic review. *Arch Gynecol Obstet.* 2011;284(5):1137-51.
12. Calzolari S, Cozzolino M, Castellacci E, Dubini V, Farruggia A, Sisti G. Hysteroscopic management of uterine arteriovenous malformation. *JSLs.* 2017;21(2):e2016.00109.
13. Levy-Zaubermann Y, Capmas P, Legendre G, Fernandez H. Laparoscopic management of uterine arteriovenous malformation *via* occlusion of internal iliac arteries. *J Minim Invasive Gynecol.* 2012;19(6):785-8.
14. Patton EW, Moy I, Milad MP, Vogezaang R. Fertility-preserving management of a uterine arteriovenous malformation: a case report of Uterine Artery Embolization (UAE) followed by laparoscopic resection. *J Minim Invasive Gynecol.* 2015;22(1):137-41.