



Report of Rare Emergency Presentations and Management of Delay Diaphragmatic Hernia in Five Cases

Amir Hassankhani^{1*}, Alireza Amir Maafi¹, Yasman Safarpour¹, Manouchehr Aghajanzadeh², Mohammad Sadegh Esmaeili Delshad², Tina Mehrpey Moghaddam² and Elahe Rafie²

¹Guilan University of Medical Sciences, Rasht, Iran

²Department of Internal Medicine, Inflammatory Lung Disease Research Center, Razi Hospital, School of Medicine, Guilan University of Medical Sciences, Rasht, Iran

Abstract

Diaphragmatic Ruptures (DR) is a life-threatening condition. (DR) are quite uncommon and often result from either blunt or penetrating trauma. (DR) are usually associated with abdominal trauma however, it can occur in isolation. Acute traumatic rupture of the diaphragm may go unnoticed and there is often a delay between the injury and the diagnosis. Tension Gastro Thorax (GT), Colo Thorax (CT) and Hepato Thorax (HT) is a life-threatening condition and presents dramatically with acute and severe respiratory distress. It develops when an intrathoracic herniation of stomach, liver or colon through a diaphragmatic defect. Massively distended stomach and colon by trapped air or fluid causing mediastinal displacement. Tension GT, CT and HT is often missed as tension pneumothorax and managed as such leading to increased morbidity and mortality. Immediate clinical and radiographic evaluation should lead to accurate diagnosis followed by emergency decompression of the stomach, colon and liver. Reduction of herniated viscera must be done before laparotomy and repair of the diaphragmatic defect. We present five cases with tension (GT), (CT) and (HT). We performed transthoracic decompress of stomach and colon in three case with chest tube insertion because other methods were not successful for decompressions and emergency laparotomy. In two cases right side emergency thoracotomy was performed. Because of this unusual condition, tension (GT), (CT) and (HT) has not been well characterized in traumatic diaphragmatic hernia in the literature reviews.

OPEN ACCESS

*Correspondence:

Amir Hassankhani, Student Research Center Office, Research Deputy Building of Guilan University of Medical Sciences, Rasht, Iran, Tel: 00989015864546; E-mail: amir.hassankhani91@gmail.com

Received Date: 26 Jan 2017

Accepted Date: 15 May 2017

Published Date: 25 May 2017

Citation:

Hassankhani A, Maafi AA, Safarpour Y, Aghajanzadeh M, Delshad MSE, Moghaddam TM, et al. Report of Rare Emergency Presentations and Management of Delay Diaphragmatic Hernia in Five Cases. *Clin Surg*. 2017; 2: 1480.

Copyright © 2017 Hassankhani A. This is an open access article distributed under the Creative Commons Attribution License, which permits unrestricted use, distribution, and reproduction in any medium, provided the original work is properly cited.

Keywords: Tension gastrothorax; Colothorax; Hepatothorax; Laparotomy; thoracotomy; Diaphragmatic hernia

Introduction

Late presentation of diaphragmatic rupture is often a result of herniation of abdominal contents into the thorax [1]. Sudden increase in the intra abdominal pressure may cause a diaphragmatic tear and visceral herniation [2]. The incidence of (DR) after thoraco-abdominal traumas is 0.8%-5%, moreover up to 30% of diaphragmatic hernias present with delay [3]. Incorrect interpretation of the X-ray or only intermittent hernia symptoms are frequent reasons for incorrect diagnosis [4]. Traumatic diaphragmatic hernia is a frequently missed diagnosis and there is commonly a delay between trauma and diagnosis [3,4]. The obstruction phase signifies complication of a long standing herniation, manifesting as obstruction, strangulation and perforation [5]. The systematic review of the literature suggests, the mean duration time was, on Day 9 [6], to 50 years [7]. Respiratory distress was the most presenting feature [1,8,9]. Abdominal pain was the next presenting feature [6,10]. The other presentations was intestinal obstruction [5,8,9], tension faeco-pneumothorax [6,8,11] and hematemesis and melena [12]. Tension gastrothorax, colothorax and Hepatothorax present dramatically with acute and severe respiratory distress and cardiac arrest [1,8,9]. It develops when the stomach colon or liver herniated through a left or right sided diaphragmatic defect into the thorax and massively distended by trapped air or fluid [5,6,8,11]. This article focuses on symptoms, diagnosis and treatment of these life-threatening conditions in five cases based on a case report and review of the literature.

Case Presentation

Case 1

A 24-year-old female patient referred to pulmonary medicine outpatient department with right

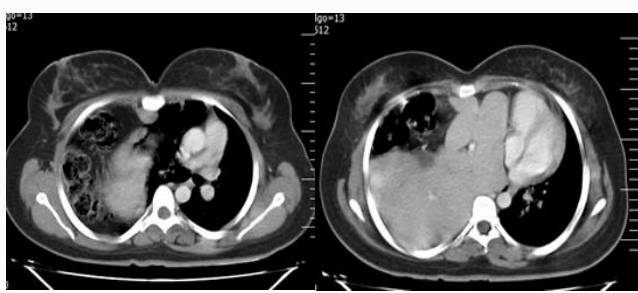


Figure 1 and 2: CT-scan of patient show herniation of liver, omentum, colon and intestine in pleural space.

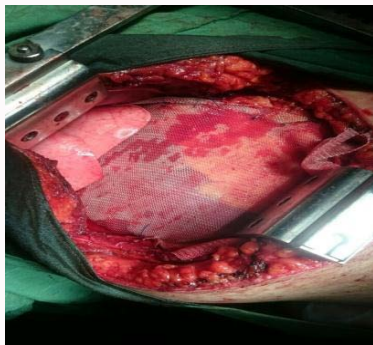

Figure 3: Totally replacement of diaphragm with prolene mesh.

sided chest pain, dyspnea and nonproductive cough for ten days. She had a past history of a minor trauma. She continued his daily activities. She was afebrile but dyspneic. Her respiratory rate was 26 breaths/min, oxygen saturation 96% with room air, pulse rate 98/min, and blood pressure 12/7 mmHg. On examination of the chest, there was dull note over right infraclavicular area. Examination of other systems was within normal limits. His chest X-ray posteroanterior (PA) view revealed a heterogeneous opacity in right lower zone she was admitted in the chest clinic. Ultrasonography of abdomen revealed empty of right upper quadrant and liver position was vertical and was in the upper portion of pleural space. Computed tomography scan of thorax showed presence of liver, omentum, small intestine and colon in the right hemi-thorax (Figure 1 and 2). She was diagnosed to have traumatic right side (DR) with herniation of liver, omentum, small intestine, colon and liver, which was rotated vertically and changed its position and shift to the left side of hemithorax and compressed heart and left lung. During the procedure symptoms of patient worsened while she was in emergency room, respiratory rate was 38 breaths/min, oxygen saturation 76% with nasal O₂, pulse rate 110/min, and blood pressure 9/6 mm Hg. Patient was intubated and referred to operation room for emergency operation. Right antero-lateral thoracotomy was performed immediately. There was a large defect of the diaphragm. About two-third of central portion of diaphragm was absence, through this defect, liver, omentum, small intestine and colon herniated to the tope point of right pleural space. The herniated organs were reduced to abdomen cavity with difficulty. The diaphragma was replaced totally with prolene mesh and fixed to rib with prolene stitch (Figure 3). An intercostal drain was placed in the left pleura. She made an uneventful recovery. In five month follow-up the conditions of patient were well.

Case 2

A 65-year-old man patient presented to pulmonary medicine

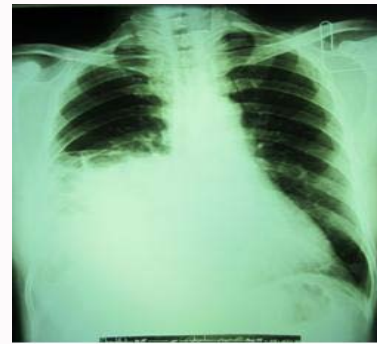

Figure 4: Right lower zone of chest with opacification.

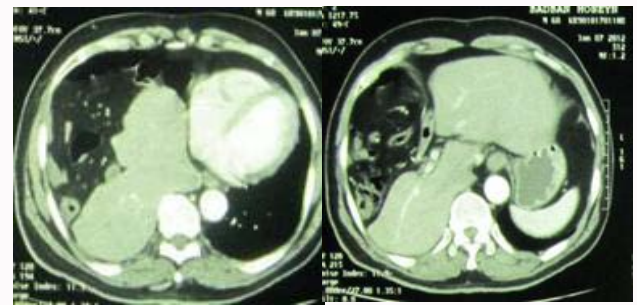


Figure 5 and 6: CT-scan show herniated and vertically position of liver with displacement of mediastinum and heart, and show omentum and colon.

outpatient department with right sided sever chest pain, right upper quadrant pain, dyspnea and productive cough for 15 days. The symptoms present after a severe physical activity. Respiratory rate was 32 breaths/min, oxygen saturation 96% with room air, pulse rate 98/min, and blood pressure 12/7 mmHg. On examination, abdomen was tender, especially in right upper quadrant and the chest; there was decreased breath sound on the right chest. Examination of other systems was within normal limits. Her chest X-ray PA view revealed a heterogeneous opacity in right lower zone (Figure 4). In past medical history he had a sever car accident six years ago without any surgery. He was admitted in the chest clinic. Ultrasonography of abdomen revealed, right upper quadrant was empty of liver, the liver position was vertical and was in the upper portion of pleural space. Computed tomography scan of thorax showed presence of liver, omentum, and colon with fecal material in the lumen of the colon in the right hemi-thorax (Figure 5 and 6). He was diagnosed to have traumatic right side diaphragmatic rupture with herniation of liver, omentum, and colon. Liver was rotated vertically and the liver position was changed and shifts to the left side of hemithorax, compressed the heart and left lung. Four hour after admission and during work-up, symptoms of patient worsened while he was taken up in emergency room, respiratory rate was 38 breaths/min, oxygen saturation 76% with nasal O₂, pulse rate 110/min, and blood pressure of 90/60 mmHg. Patient was intubated and referred to operation room for emergency surgery of tension hepatic-chylothorax. A right antero-lateral thoracotomy was performed immediately. There was a large defect of the diaphragm. About 80% portion of diaphragm was absence, through this large defect, liver, omentum and colon was herniated to right pleural space. The liver was rotated to the upper portion of pleural space. Lung was collapsed. After releases of bands, the herniated organs were reduced to abdomen cavity. Position of liver was corrected partially and reduced to the abdominal cavity

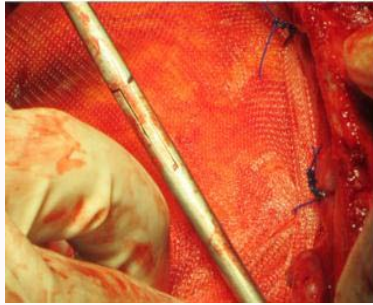


Figure 7: Totally replacement of diaphragm with mesh.

with difficulty. The diaphragm was replaced totally with prolene mesh and the edge of mesh fixed to rib with prolene stitch (Figure 7). An intercostal drain was placed in the right pleura space. Post operation, right lower lobe was atelectatic due to plugs and improved with bronchoscopy. In one year follow-up the conditions of patient were well.

Case 3

A 25-year-old man referred to our unit with 2 days history of progressive left sided chest pain, epigastric pain, and dyspnea in the mountain for army patrol. There was no other positive history other than a penetrating truma of left hemithorax 2 years ago during an army training without hemopneumothorax. On examination he had respiratory distress. Her pulse rate was 98/min and regular, blood pressure was 90/60 mmHg and respiratory rate was 32/min. Examination of the chest revealed a decreased air entry in the left side, which was dull in percussion. There was a shift of mediastinum to the right side. The epigastrium and left hypochondrium were tender. The haematological and biochemical parameters were within normal limits. The chest X-ray revealed a large air fluid level in the left hemithorax (Figure 8). An ultrasonogram of the chest and abdomen was performed which showed a large collection of fluid in the hemithorax but was inconclusive as to whether it was supra diaphragmatic or infra diaphragmatic. A CT-scan of chest was performed, there was a massive hydropneumothorax (Figure 9). A clinical and imaging suspicion of hydropneumothorax was entertained and a chest tube was placed which was no significant drainage and clinical situations of patient was not improved.

During the procedure her symptoms of obstruction worsened while she was taken up for emergency surgery. In emergency room with needle multiple aspirations was performed, a large amount of air and greenish fluid was aspirated. Evacuation of air and 600 ml of gastric content, led to immediate relief of symptoms. Antero-lateral

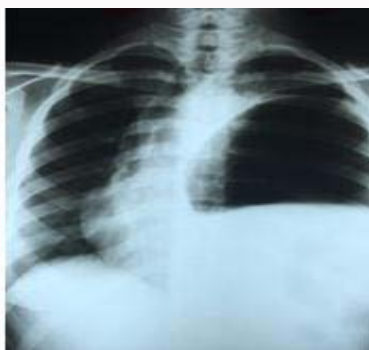

Figure 8: CXR with air fluid level and shift of mediastinum.

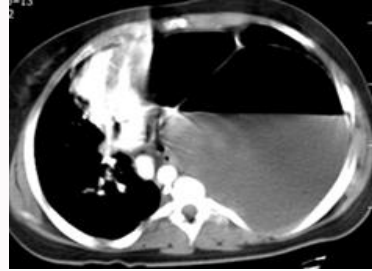

Figure 9: CT-scan of chest show large air fluid level with sever shift of mediastinum and collapse of left and right lung.

thoracotomy was performed immediately. There was a 7 cm linear tear in the left dome of the diaphragm which the stomach, greater omentum, a part of transverse colon had herniated into the left pleural space. The herniated organs were reduced to abdomen. The diaphragmatic tear was repaired with prolene mattress sutures. An intercostal drain was placed in the left pleura. He made an uneventful recovery except for left lower atelectasis, which was treated with chest physiotherapy.

Case 4

A previously healthy 19-year-old girl presented to the emergency department with a 6 hours history of severe abdominal pain, left chest pain and increasing respiratory distress. Her respiratory rate was 36/min and heart rate was 110/min, auscultation of lung fields revealed diminished breath sound over the left side. This patient had a history of left side chest knife injury and tube thoracostomy was performed for hemothorax two years ago. A chest and abdominal X-ray showed a large air-fluid level in the left hemithorax with air-fluid level and shift of the mediastinum to the right side which was interpreted as tension gastrothorax and colothorax (Figure 10 and 11). Prompt insertion of a nasogastric tube was not possible. A chest CT scan was preformed and showed a massive hydropneumothorax in the left hemithorax with septations (Figure 12 and 13). During the procedure her symptoms of obstruction worsened while she was

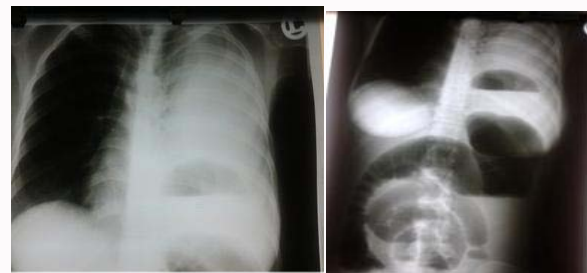

Figure 10 and 11: Left side opacification and air-fluid level, multiple air-fluid level with suspicious of intestinal obstruction.

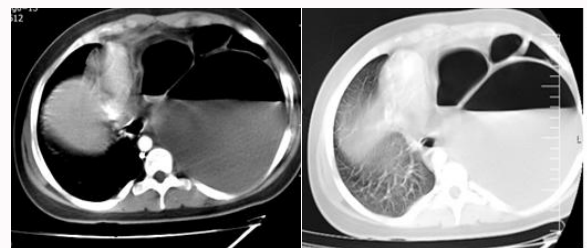


Figure 12 and 13: CT-scan with air-fluid collection, shift of mediastinum and septation.

taken up for emergency room, a chest-tube insert in left pleural space and 1800 cc mall odorous fluid with air exit after this procedure. On the same day, the patient underwent left-lateral thoracotomy. Stomach was collapsed and a 4 cm perforation was found in the body of stomach and transvers colon was gangrenous and multiple perforations were presented. Thoracotomy incision extended to the abdomen (thoracoabdominal). Transverse colon was resected and double barrel colostomy was performed. Perforation of stomach was repaired. An 8 cm × 6 cm defect was present in the central portion of left diaphragm. The diaphragmatic tear was repaired with prolene interrupted sutures. An intercostal drain was placed in the left pleura. The postoperative course was uneventful and she was discharged home 7 days after surgery. The colostomy was revised 8 weeks later.

Case 5

A 16-year-old girl presented to our unit with 4 days history of progressive left sided chest pain and dyspnea. In past history there was no positive history of trauma and no other chest diseases. On examination she was distressed and had chest pain. Her pulse rate was 110 p/mi regular, blood pressure was 100/70 mmHg and respiratory rate was 38/min. Examination of the chest revealed a decreased air entry in the left side, which was dull in percussion. The epigastrium and left hypochondrium were tender. The haematological and biochemical parameters were within normal limits. The chest X-ray revealed a large air fluid level in the left hemithorax and there was a shift of mediastinum to the right side (Figure 14). A clinical suspicion of diaphragmatic hernia or massive hydropneumothorax was entertained and a nasogastric tube was placed with no significant aspiration. An ultrasonogram of the chest and abdomen was performed which showed a large collection of fluid in the hemithorax. A chest CT scan was preformed and showed a massive hydropneumothorax in the left hemithorax and a shift of mediastinum to the right side (Figure 15 and 16). During the procedure, her symptoms of obstruction worsened while she was taken up for emergency surgery. The patient had cardiac arrest as she entered the anaesthetic room. She was intubated and a chest tube insert in left pleural space and 2000 cc greenish fluid with air exit after this procedure. O₂ saturation was 92% and the patient's vital signs improved immediately. Patient referred to ICU department. After partially stabilization of cardiovascular conditions, Laparotomy was performed immediately. There was an 8 cm linear tear in the left-lateral side of the diaphragm through which the stomach and greater omentum had herniated into the left chest. The stomach was back down to the abdomen. A 6 cm perforation was seen on the greater curvature of stomach, the perforation was repaired. The diaphragmatic rupture was repaired with prolene interrupted

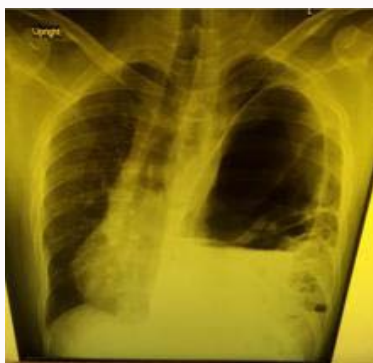

Figure 14: CXR show major air-fluid level with shift of mediastinum.

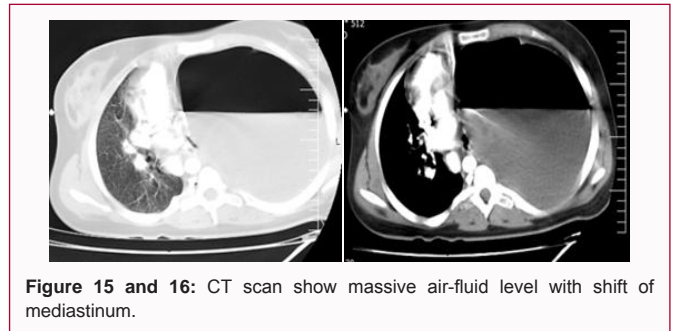


Figure 15 and 16: CT scan show massive air-fluid level with shift of mediastinum.

sutures. Anintercostal drain was placed in the left pleura space. She referred to the intensive care unit, 6 h after surgery, patient present with symptoms and a sign of re-expansion pulmonary edema, this complication was treated with one lung ventilation, hydrocortisone fluid restriction and diuretic. She discharged with good conditions 6 day postoperation.

Discussion

Diaphragmatic rupture is a rare complication of trauma, reported in 1-7% of major blunt trauma patients and 10-15% of penetrating trauma [1,2,6,13]. Tension gastrothorax is a distended intrathoracic stomach witch herniated through a congenital or acquired diaphragmatic defect to the pleural space. Gastric distension in the pleural space can compress the lung and mediastinal shifting. This condition is life threatening [4,5,7,14]. Horst, described pathophysiology events which leading to tension gastrothorax [9,5]. The cause of herniation is increased, abdominal pressure and stomach was herniates through a preexisting defect in the diaphragm. Then tension gastrothorax may occur at any time when the stomach suddenly fills with air, fluid or food through a one-way valve mechanism created by abnormal angulation of the gastroesophageal junction combined with gastric outlet obstruction caused at the level of the diaphragm [4,5,8,14]. Two of our patients had a heavy exercise and another one had army effort in the mountain with past history of blunt and penetrating truma. The clinical picture of (TGT) is acute respiratory distress, chest wall and epigastric pain, reduced or absent breath sounds in the left hemithorax and shifting the heart bit to the right side. This condition commonly been mistaken for a tension pneumothorax and managed as such leading to increased morbidity and mortality [4,5,8]. As three of our patients which first diagnosis was (TGT) or tension bulla. After patient's conditions become stable, chest x-ray is first tool for differentiating between the above mentioned diagnoses. In the (TGT) the chest x-ray findings are: 1- a large air-filled structure with or without a fluid level in the left hemithorax. 2- A superior rim formed by compressed left lung and stomach wall. 3- There is not a stomach bubble in the left upper quadrant. 4- The left hemidiaphragm shadow will be poorly defined. 5- Shifting mediastinum to the right [1,3,8,10]. As our patients had all above mentions. But in left-sided tension pneumothorax, the entire left lung is compressed and all lung surrounded by intrapleural air, hemidiaphragm depressed and ill-defined [1-6]. First step in the management of tension gastrothorax is immediate placement of a large naso or orogastric tube to decompress the dilated stomach [4,5,11,14,15]. If this maneuver fails, transthoracic needle decompression of the stomach recommended [4,5,14]. If this maneuver fails too we recommended chest-tube insertion. In two of our patients, this maneuver improved the clinical situations. Positive pressure ventilation allows immediate re-expansion of the lung and

forces intrapleural contents back into the abdomen [14]. We did this maneuver in one of our patients but were not improved clinical state of patient. Instant clinical improvement should occur after stomach decompression [6,10]. If deflation of the stomach is not occur, the mediastinal shift can impair venous return and lead to cardiac arrest [4,5,11,14].

Definitive management after initial resuscitation in these emergency conditions, with thoracotomy or laparotomy is the access of choice, but we performed thoacotomy and thoracoabdominal approach in our patients. Tension colothorax causing sever shifting of mediastinum, collapse of the underlying lung and cardiac compression, it is a surgical emergency. It is more common on the left side and the colon is most likely to herniated [16]. It can be asymptomatic or present with abdominal pain, intestinal obstruction and cardio-respiratory distress [16], one of our patients was presented with tension gastro-chylothorax.

Right side (DR) are rare and difficult to diagnose, as chest radiography often does not show any specific signs may show only elevation of the right diaphragmatic border. Right-sided ruptures are associated with high mortality and morbidity [6,8,13]. Right-sided (DR) (DR) and subsequent herniation of viscera are uncommon, and is associated with a higher morbidity and mortality than left-sided hernias. There are three phases used to describe the presentation of traumatic (DR): acute, latent, and obstructive phases [12]. The acute phase occurs during the recovery time from the initial injury. This is when most diaphragmatic injuries are missed, often due to masking from other severe, co-existing injuries [1,2,6,13]. The diagnosis may also be delayed in patients. The latent phase refers to an asymptomatic period, where herniations are found incidentally on radiologic imaging performed for other reasons. During the obstructive phase, Patients are symptomatic often from GI obstruction or perforation and cardiovascular compromise secondary to herniation of abdominal contents into the thorax due to sever physical activity [3,6,7,15]. Two of our patients presented with sever dyspnea, chest wall and abdominal pain after physical activity with herniation of colon and liver, who presented 4 to 8 years after the initial trauma. Accordingly, delayed diagnosis is common in right-sided ruptures, often resulting in severe complications, such as strangulation ileus and intrathoracic herniation of the hollow organs (stomach, colon, and small bowel) [17,18]. Cases of right (DR) with hepatothorax may result in severe atelectasis of the right lung or tension mediastinum, thereby severely impeding respiration and circulation [3,6,13]. As our cases with colon and hepatothorax in such condition an abdominal and chest CT should be performed quickly, and surgical repair via a trans-thoracic or trans-abdominal approach should be considered immediately following radiographic confirmation [3,6,13,17,18]. We used thoracotomy approach. Because the size of the defect is often too large a primary repair not possible and prosthetic mesh may prove necessary. As our two cases, which defect was very large and we used total prolen mesh for repair of total defect of diaphragm without complications.

Conclusion

With advances in diagnostic radiology, traumatic diaphragmatic hernia may be diagnosed with late. To avoid these complications, follow-up radiology after the injury may can early detection and, consequently, facilitates timely repair. Tension viscerothorax, which mimic many features of tension pneumothorax, as (tension gastrothorax, colothorax and hepato thorax). If successful, initial

decompression of the stomach through a nasogastric, orogastric tube, needle decompression or chest tube insertion in critical condition as tension pneumothorax will improve the emergency situation and definitive repair of the diaphragm defect may be possible.

References

- Walchalk LR, Stanfield SC. Delayed presentation of traumatic diaphragmatic rupture. *J Emerg Med.* 2010;39:21-24.
- Ramdass MJ, Kamal S, Paice A, Andrews B. Traumatic diaphragmatic herniation presenting as a delayed tension faecopneumothorax. *Emerg Med J.* 2006;23:e54.
- Igai H, Yokomise H, Kumagai K, Yamashita S, Kawakita K, Kuroda Y. Delayed hepatothorax due to right-sided traumatic diaphragmatic rupture. *General thoracic and cardiovascular surgery.* 2007;55:434-6.
- Rafi M, Marudanayagam R, Moorthy K, Yoong K. Delayed presentation of diaphragmatic rupture as intra-thoracic gastric volvulus. *Minerva Chir.* 2008;63:425-7.
- Goh BK, Wong AS, Tay KH, Hoe MN. Delayed presentation of a patient with a ruptured diaphragm complicated by gastric incarceration and perforation after apparently minor blunt trauma. *CJEM.* 2004;6:277-80.
- Launey Y, Geeraerts T, Martin L, Duranteau J. Delayed traumatic right diaphragmatic rupture. *Anesth Analg.* 2007;104:224-5.
- Singh S, Kalan MM, Moreyra CE, Buckman RF Jr. Diaphragmatic rupture presenting 50 years after the traumatic event. *J Trauma.* 2000;49:156-9.
- Kafih M, Boufettal R. [A late post-traumatic diaphragmatic hernia revealed by a tension fecopneumothorax (a case report)]. *Revue de pneumologie clinique.* 2009;65:23-6.
- Ruiz-Tovar J, Calero Garcia P, Morales Castineiras V, Martinez Molina E. [Post trauma diaphragmatic hernia]. *Revista de gastroenterologia del Peru :organo oficial de la Sociedad de Gastroenterologia del Peru.* 2008;28:244-7.
- Al-Mashat F, Sibiany A, Kensarah A, Eibany K. Delayed presentation of traumatic diaphragmatic rupture. *Indian J Chest Dis Allied Sci.* 2002;44:121-4.
- Kelly J, Condon E, Kirwan W, Redmond H. Post-traumatic tension faecopneumothorax in a young male:case report. *World J Emerg Surg.* WJES. 2008;3:20.
- Hariharan D, Singhal R, Kinra S, Chilton A. Post traumatic intra thoracic spleen presenting with upper GI bleed!--a case report. *BMC Gastroenterol.* 2006;6:38.
- Seket B, Henry L, Adham M, Partensky C. Right-sided posttraumatic diaphragmatic rupture and delayed hepatic hernia. *Hepatogastroenterology.* 2009;56:504-7.
- Slater RG. Tension gastrothorax complicating acute traumatic diaphragmatic rupture. *J Emerg Med.* 1992;10(1):25-30.
- Horst M, Sacher P, Molz G, Willi UV, Meuli M. Tension gastrothorax. *J Pediatr Surg.* 2005;40(9):1500-4.
- Lagoo JY, George B, Kilpadi KA, Fernandes LS. Tension colothorax causing cardiac tamponade:A life-threatening complication following transhiatal oesophagectomy. *Indian J Anaesth.* 2013;57:191-2.
- Chen HW, Wong YC, Wang LJ, Fu CJ, Fang JF, Lin BC. Computed tomography in left-sided and right-sided blunt diaphragmatic rupture:experience with 43 patients. *Clin Radiol.* 2010;65:206-12.
- Nchimi A, Szapiro D, Ghaye B, Willems V, Khamis J, Haquet L, et al. Helical CT of blunt diaphragmatic rupture. *AJR Am J Roentgenol.* 2005;184:24-30.