



Renal Artery Reconstruction after a Kidney Transplant Using PTFE Graft & Autologous Hypothermic Perfusion

Sarkar A*

Department of Cardiothoracic and Vascular Surgery, Rabindranath Tagore International Institute of Cardiac Sciences, India

Abstract

Donor kidney loss due to acute thrombosis of the renal artery is a common and devastating complication of the procedure. However, this can be surgically treated with renal artery reconstruction using vascular grafts. The donor kidney can be protected from ischemia by transfusing cold autologous oxygenated blood perioperatively. This study analyses the use of autologous hypothermic blood perfusion & PTFE graft during renal artery reconstruction after acute thrombosis of transplant renal artery.

Introduction

Early kidney transplant loss as a result of acute thrombosis of the renal artery remains a constant and devastating complication, with an incidence of 0.2% to 7.5% [1-4]. Although radioisotope and ultrasound scans can confirm vascular occlusion, immediate reoperation is the only option for salvaging the graft because it can only tolerate a few minutes of total ischemia. Arterial thrombosis may occur as a result of injury to a diseased artery, problems with anastomosis, hypercoagulability or malpositioning of the allograft [5]. However, these complications can be averted by repairing the renal vessel using vascular PTFE grafts of appropriate size. Also, the use of cold autologous blood at 12 to 15 degrees Celsius to transfuse the donor kidneys provides protection against ischemia-reperfusion injury. In this instance, we have created a novel renal pump circuit system that can perfuse blood or an intracellular oxygen carrier at variable oxygenation, pressure, and temperature [6].

Case Presentation

We have used the above-mentioned technique in 3 patients. All three patients suffered early (within 48 hours of surgery) allograft renal artery thrombosis. Emergent duplex ultrasound scans were performed and acute renal artery thrombosis was detected in all patients. Other investigations were unremarkable. All the 3 patients were being managed with temporary hemodialysis before the procedures. Intraoperatively after examining the site of thrombosis, the vascular PTFE graft is anastomosed with the transplant renal artery using 5-0 Prolene sutures. The renal pump circuit has 2 cannulas, one to drain normothermic blood from the patient to the blood cooling device and the other cannula to perfuse cold autologous blood from the device to the transplanted kidney external/internal iliac artery. The perfusion cannula was attached to the PTFE graft and the transplanted kidney was perfused with autologous blood at 12 to 15 degrees Celsius for 15 mins to prevent renal damage. Post perfusion the other end of the PTFE graft was anastomosed with the external/internal iliac artery using 5-0 Prolene sutures. Intraoperative doppler was performed to assess adequate flow. Their postoperative period was uneventful and were discharged in stable condition. At 2 months of follow up all were asymptomatic with normal renal function (Figures 1-5).

Discussion

Primary renal transplant failure is associated with significant mortality, particularly when the cause of graft loss is thrombosis. Thrombosis of the renal artery occurs as a result of a reduction in the cross-sectional area of the renal artery, usually for technical reasons, and can occur at any time [2]. There are few reported cases describing the use of PTFE grafts in reconstructing short or damaged renal vessels in kidney transplantation. The technique of initial anastomosis of the PTFE graft to the recipient vessel, followed by PTFE vascular graft cross clamping and anastomosis of the PTFE graft to the renal vessel, leading to a better functioning graft. We preferred anastomosing PTFE graft to recipient iliac vessel during the transplant operation rather than performing the

OPEN ACCESS

*Correspondence:

Abhinaba Sarkar, Department of Cardiothoracic and Vascular Surgery, Rabindranath Tagore International Institute of Cardiac Sciences, 40, East Road, Kolkata, West Bengal, 700099, India,

Received Date: 25 Mar 2024

Accepted Date: 12 Apr 2024

Published Date: 17 Apr 2024

Citation:

Sarkar A. Renal Artery Reconstruction after a Kidney Transplant Using PTFE Graft & Autologous Hypothermic Perfusion. *Clin Surg.* 2024; 9: 3697.

Copyright © 2024 Sarkar A. This is an open access article distributed under the Creative Commons Attribution License, which permits unrestricted use, distribution, and reproduction in any medium, provided the original work is properly cited.

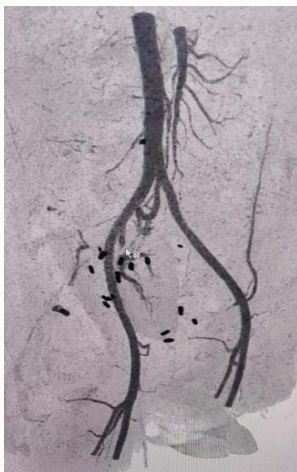

Figure 1: Preoperative CT Angio showing filling defect in graft renal artery.




Figure 2: The renal pump circuit showing the drainage and perfusion cannulas attached to the blood cooling device system.

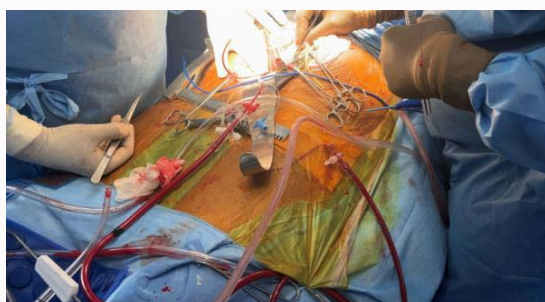


Figure 3: Intraoperative image showing the drainage cannula and perfusion cannula.

anastomosis to the kidney graft vessel at the bench with a cooled kidney, since we believe this leads to an easier intraoperative vascular anastomosis between renal and recipient vessel. This also gives the advantage of shorter lower limb ischemia time. The use of autologous blood at 12 to 15 degrees Celsius for 15 mins to prevent renal damage was an interesting addition to the whole procedure.

We did not experience any technical problem or complication in the described cases. However, there is little in the literature pertaining to the long-term outcome of PTFE vascular grafts in kidney transplantation. PTFE vascular grafts used during kidney transplantation are short in length and with high blood flow and

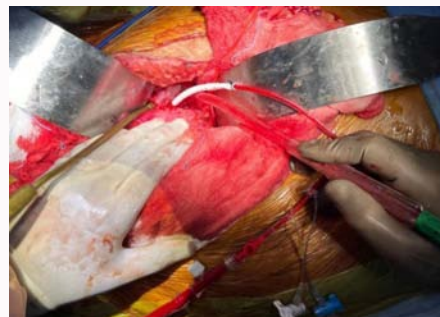


Figure 4: Intra operative pic showing graft kidney being perfused with autologous hypothermic blood.

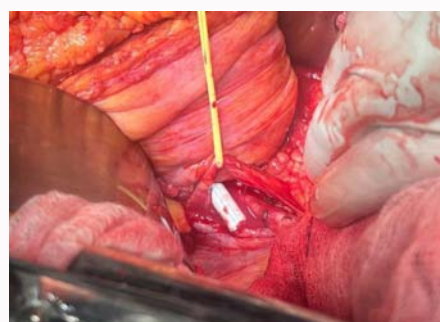


Figure 5: Image after completion of renal artery reconstruction with PTFE graft.

consequently may have better long-term results than PTFE grafts used in treating lower limb ischemia. Also, we are unaware of studies comparing long-term results of biologic vs prosthetic vascular grafts in kidney transplantation.

Conclusion

Surgical repair of renal arteries with vascular graft is an excellent option to preserve renal function post-transplant. The use of autologous hypothermic blood to perfuse the kidney intraoperatively prevents further renal ischemia. Our results with the use of PTFE vascular grafts for reconstructing short or damaged renal vessels in kidney transplantation need to be tested in bigger series and in comparison, with biologic vascular grafts.

Acknowledgement

I gratefully convey my thanks to Dr. Atanu Saha, Dr. Unmesh, Dr. Subham, Dr. Digvijay, Mr. Gopal, Mr. Somnath & Mr. Anuj for their assistance in data collection & guidance in completing this article. None of the authors had any conflict of interest.

References

1. Keller AK, Jorgensen TM, Jespersen B. Identification of risk factors for vascular thrombosis may reduce early renal graft loss: A review of recent literature. *J Transplant.* 2012;2012:1-9.
2. Knechtle SJ, Pirsch JD. Early course of the patient with a kidney transplant. In: Morris PJ, Knechtle SJ, editors. *Kidney Transplantation: Principles and Practice Philadelphia: Saunders Elsevier; 2008.* p. 210-19.
3. Fervenza FC, Lafayette RA, Alfrey EJ, Petersen J. Renal artery stenosis in kidney transplants. *Am J Kidney Dis.* 1998;31(1):142-8.
4. Humar A, Key N, Ramcharan T, Payne WD, Sutherland DE, Matas AJ. Kidney retransplants after initial graft loss to vascular thrombosis. *Clin Transplant.* 2001;15(1):6-10.

5. Markmann JF. Transplantation of abdominal organs. In: Townsend MC, editor. Sabiston Textbook of Surgery Philadelphia: Saunders Elsevier; 2007. p. 703.
6. Bhattacharjee RN, Ruthirakanthan A, Sun Q, Richard-Mohamed M, Luke S, Jiang L, et al Subnormothermic oxygenated perfusion optimally preserves donor kidneys *ex vivo*. Kidney Int Rep. 2019;4(9):1323-33.