



Remote Intracranial Hemorrhage after Spinal Surgery: Possible Etiology and Incidence

Toshimi Aizawa^{1*}, Hiroshi Ozawa², Yoshihiro Ashina¹, Ko Hashimoto¹, Haruo Kanno¹, Toshimitsu Eto¹ and Eijilto¹

¹Department of Orthopaedic Surgery, Tohoku University School of Medicine, Japan

²Department of Orthopaedic Surgery, Tohoku Medical and Pharmaceutical University, Japan

Abstract

Background: Remote Intracranial Hemorrhage (RIH) is a rare but potentially lethal complication related to Cerebro Spinal Fluid (CSF) drainage. Spinal surgery has a chance of durotomy or dural tear. However, the exact incidences of RIH resulting from spinal surgery remain uncertain.

Objective: The aim of the present study was to prospectively evaluate the incidence of RIH, and the relationship between RIH and CSF drainage volume.

Methods: A total of 691 patients underwent spinal surgery in our department between May 2007 and April 2016. Among these, 175 had durotomy or dural tear, which were evaluated with brain CT the day after surgery, regardless of brain symptoms. The clinical features of RIH and drainage volume were assessed.

Results: Three patients were affected by RIH, including two asymptomatic. The incidence among all spinal surgeries was 0.4% and among durotomy or dural tear was 1.7%. Patients with RIH had significantly more drainage totally and per 24 hours after surgery than those without (589 ± 157 ml vs. 314 ± 968 ml, $p=0.01$; 898 ± 185 ml vs. 157 ± 160 ml, $p=0.003$). RIH was detected in the cerebellum alone, in both the cerebellum and cerebrum, and in the cerebrum alone in one each, respectively. One patient with hydrocephalus was treated conservatively and completely recovered from their brain symptoms within 17 days.

Conclusion: The incidence of RIH in this study was higher than expected. RIH was closely related to CSF drainage volume, in particular, with large volume loss within a short time.

Keywords: Remote Intracranial Hemorrhage; Spinal surgery; Prospective study; cerebrospinal fluid; complication

Introduction

Remote Intracranial Hemorrhage (RIH) is a rare but potentially lethal complication related to Cerebrospinal Fluid (CSF) drainage [1,2]. RIH is most likely to develop in the cerebellum, and thus has been termed “remote cerebellar hemorrhage” in the previous reports, although it can occur in various intracranial locations [3,4]. RIH has recently become a well-recognized complication during and after thoracoabdominal aortic repair and brain surgery [3,4]. In the thoracoabdominal aortic repair, lumbar CSF fluid drainage is commonly used to reduce the risk of spinal cord injury caused by ischemia [3,5]. The reported incidence of RIH associated with thoracoabdominal aortic repair is between 0.5% and 3.5%; that after supratentorial surgery is between 0.2% and 4.9% [2-5]. When RIH occurs during thoracic aortic repair, a high associated mortality of 40% has been reported [3].

During spinal surgery, durotomy is performed to remove intradural lesions. Dural tears can also occur accidentally or deliberately; for example, ossified dura mater in the ossification of the ligamentum flavum is occasionally removed with the corresponding ossified ligamentum [6]. RIH can occur due to CSF leakage related to spinal surgery. Severe disability or death has been described in 26.6% of patients with RIH after spinal surgery, which strongly indicates that spine surgeons should be well informed about this complication [7,8]. However, almost all previous reports were case reports and the exact incidence of RIH resulting from spinal surgery and the association between the volume of CSF leakage and the occurrence of RIH are uncertain. The purpose of the present study was to prospectively clarify these two questions. The volume of CSF leakage during surgery cannot be measured precisely since it is mixed with blood. Intraoperatively, the volume

OPEN ACCESS

*Correspondence:

Toshimi Aizawa, Department of Orthopaedic Surgery, Tohoku University School of Medicine, 1-1, Seiryomachi, Aoba-ku, Sendai, Miyagi Prefecture, Japan,

E-mail: toshi-7@med.tohoku.ac.jp

Received Date: 29 Jun 2018

Accepted Date: 27 Jul 2018

Published Date: 02 Aug 2018

Citation:

Aizawa T, Ozawa H, Ashina Y, Hashimoto K, Kanno H, Eto T, et al. Remote Intracranial Hemorrhage after Spinal Surgery: Possible Etiology and Incidence. *Clin Surg*. 2018; 3: 2058

Copyright © 2018 Toshimi Aizawa.

This is an open access article distributed under the Creative Commons Attribution License, which permits unrestricted use, distribution, and reproduction in any medium, provided the original work is properly cited.

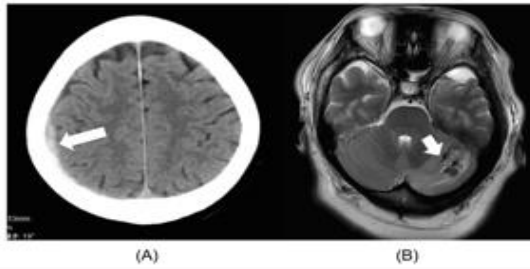


Figure 1: Remote intracranial hemorrhage in the cerebrum and cerebellum. **A)** Brain computed tomogram of a 75-year-old male with ossification of the ligamentum flavum at C7-T1. Small, subdural hemorrhage is detected in the right cerebrum (arrow). **B)** Brain magnetic resonance image of a 48-year-old female with ossification of the posterior longitudinal ligament in the thoracic spine. Intraparenchymal bleeding is detected in the left cerebellar hemisphere (arrow).

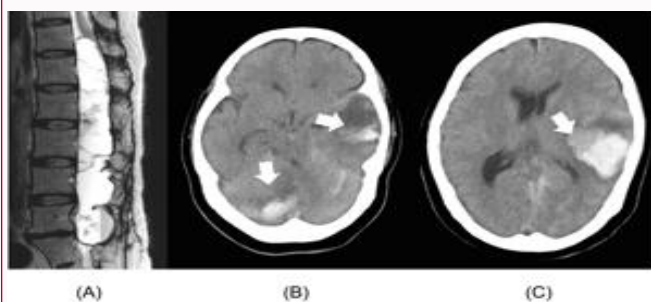


Figure 2: A 56-year-old female patient with intradural extramedullary tumor. **A)** Preoperative MRI. T2-weighted sagittal MRI shows a huge intradural extramedullary tumor extending from T12 to L5. **B,C)** Computed tomogram the day after surgery. Intracranial hemorrhage is seen in the right cerebellar hemisphere (B, arrow), tentorium cerebelli, and the left temporal lobe (B, C, arrows).

of hemorrhage during surgery should be affected by the operative time, the types of surgery, the size of exposure, and so on and that of CSF leakage should be also affected by the timing and size of dural rupture, the level of spinal surgery, and the closing procedures of dural tear. In addition, the volume of CSF leakage with bleeding during surgery should not be controlled. On the other hand, the postoperative volume of CSF and hemorrhage might be controlled using a suction drainage system. Therefore, in the present study, in order to clarify the relationship between the volume of CSF drainage and the occurrence of RIH, we measured the postoperative volume of blood and CSF drainage.

Materials and Methods

Patient population

Between May 2007 and April 2016, a total of 691 patients underwent spinal surgeries in our department. Among these, 175 patients had durotomy or dural tear, which was confirmed in directly findings during surgery. The demographic data of those patients are shown in Table 1. These patients were the subjects of this study. After durotomy or dural tear, the opened dura mater is closed by side-to-side suture or using an artificial dura with a 6-0 nylon suture as tight as possible. Then, the closed dura is augmented by fibrin glue. Since 2008, an absorbable polyglycolic acid sheet (Neoveil, Gunze, Kyoto, Japan) is also used for augmentation.

Before closing the surgical wound, a relatively low-suction drainage system, which produces negative suction pressure with a bag

Table 1: Demographic data of the 175 patients with durotomy or dural tear between 2007 and 2016.

Male: Female	86: 89
Averaged age at surgery	55 years (range, 7–87 years)
Pathology of surgery	
Spinal cord tumor	126
Degenerative spinal disorders	11
Syringomyelia	9
OPLL/OLF	9
Spinal tumor	7
Spinal trauma	5
Infection/inflammatory disease	4
Spinal cord herniation	2
Adhesive arachnoiditis	2

OPLL: Ossification of the Posterior Longitudinal Ligament; OLF: Ossification of the Ligamentum Flavum

(J-VAC[®], made by Ethicon, Inc, Cincinnati, OH, USA), was put in the epidural space for prevention of postoperative epidural hematoma [9–12]. Pressure in this system can be controlled based on the height of the drainage bag and we changed the height to maintain the drainage volume ≤ 200 –240 ml/day, postoperatively when the drainage showed obvious serous bloody condition based on the previous reports [3,5]. The tube was removed after the drainage became obvious CSF-like condition or the drainage volume was ≤ 50 –100 ml/day.

Methods

During this study period, all patients with durotomy or dural tear directly confirmed during surgery were evaluated with brain Computed Tomography (CT) on the day after surgery, regardless of brain symptoms. The drainage volume till it was removed was also recorded. Using these data, we first calculated the incidence of RIH. When there were patients with RIH, the size of suction tube, location of RIH, and prognosis of the patients with RIH were assessed. Then, the drainage volume with and without RIH was calculated and compared. Statistical analysis was performed with Mann-Whitney test. *P* values of <0.05 were considered statistically significant.

Results

In total, three patients were affected by RIH between 2007 and 2016; all of these had durotomy or dural tear and the onset or detection of RIH was within 24 hr postoperatively. Two patients were asymptomatic. The incidence of RIH among all spinal surgery patients was 0.4% (3/691); that among patients with durotomy or dural tear was 1.7% (3/175). The diameter of the suction drainage system was 5 mm in two patients and 3.3 mm in one. In four patients, CSF drainage from the lumbar spine was performed to reduce drainage volume from the surgical site for dural repair but they did not show RIH.

The total and 24-hr drainage volumes of the patients with versus without RIH after durotomy or dural tear are shown in Table 2. Both drainage volumes of the patients with RIH were significantly larger than those without RIH and the latter indicated stronger significant relationship with a *p* value of 0.003.

Detailed data from the three patients with RIH are shown in Table 3. One of these patients had spinal cord tumor and the two others had ossification of the posterior longitudinal ligament or the ligamentum flavum. One patient showed acute encephalopathy with hydrocephalus such as headache and consciousness disturbance 12

Table 2: Volume of drainage.

	With RIH (n=3, ml)	Without RIH (n=172, ml)	p value
Total	589 ± 157 (455–763)	314 ± 968 (7–9169)	0.01
Per 24 hours	898 ± 185 (736–1100)	157 ± 160 (11–790)	0.003

(Mean ± standard deviation, RIH: Remote Intracranial Hemorrhage)

hr after surgery. Other two patients were asymptomatic without hydrocephalus. RIH was detected in the cerebrum alone in one patient (Figure 1A), in both the cerebrum and cerebellum in one patient, and in the cerebellum alone in one patient (Figure 1B). Intraparenchymal bleeding was detected in two patients, whereas subdural bleeding was seen in one. One patient with hydrocephalus was treated conservatively by neurosurgeons and the other two asymptomatic patients were just followed up regularly by brain CT.

Case Presentation

A 56-year-old woman complained of severe bilateral leg pain and numbness with severe gait disturbance caused by a huge intradural extramedullary tumor extending from T12 to L5 (Figure 2A). The tumor was removed through T10-S1 laminectomy and durotomy. After tumor removal, the opened dura mater was closed using an artificial dura with fibrin glue. Because of the relatively high intra operative blood loss (763 ml), 5 mm-diameter suction drainage was placed before surgical wound closure for prevention of the postoperative epidural hematoma. The histological diagnosis was neurinoma. Twelve hours after surgery, the patient showed consciousness disturbance and we immediately removed the drainage tube. CT examination revealed intracranial hemorrhage in the right cerebellar hemisphere, tentorium cerebelli, and the left temporal lobe (Figures 2B and 2C). We consulted neurosurgeons in our hospital. The patient was treated conservatively with Glyceol (400 ml/day) and nicardipine hydrochloride to maintain the blood pressure between 100 and 120 mmHg. Her consciousness was gradually recovered 2 days after the onset of symptoms. Seventeen days after the onset, her brain symptoms such as disturbance of consciousness and dysphasia had completely recovered. She was moved to the ordinary program for rehabilitation after spinal cord tumor and 110 days post operatively, she could walk with crutches and discharged from our hospital.

Discussion

RIH is a potentially lethal complication associated with spinal surgery that has just been increasingly recognized by spine surgeons in recent years [2,13]. However, few reports have described the incidence of RIH related to spinal surgery. In the most recent systematic review [13], 57 cases of RIH after spinal procedures were reported; the male/female ratio in that review was 23/34 and the average age at surgery was 58 years (range, 23–85 years). The most common pathology was degenerative spinal disease (60%), followed by spinal cord tumor (21%). The most commonly affected spinal

level was lumbosacral (60%), followed by cervical (25%). The review reported a lower incidence of RIH after spinal surgery than that reported after supratentorial craniotomies, which is approximately 0.08% to 0.6%, however it did not indicate the exact incidence of it. Here, we calculated it at our institution during the 9 years of the study was 0.4% of all spine surgeries and 1.7% of those with durotomy or dural tear. In our institution, approximately 80% of the patients with durotomy or dural tear needed to open the dura mater to treat the intradural lesions such as spinal cord tumor and syringomyelia and therefore, the number of patients with durotomy or dural tear were larger than usual. In such situation, RIH may not be as rare as expected.

RIH can occur at various locations and can be of different types [3,13]. The recent review cited above found 43% of reported RIH occurred in the cerebellum, 38% were in the cerebrum, and 20% were in both [13]. Various types of bleeding have also been reported: subarachnoid, intraparenchymal, and subdural [3]. In this series, RIH was detected in the cerebellum only in one patient while the other two patients also had cerebrum bleeding. One patient had subdural hemorrhage in the cerebrum. Actually, it occurred at various locations with various types.

The exact mechanism of RIH after spinal surgery remains uncertain. Intracranial hypotension caused by CSF leakage may lead to enlargement of the dural venous sinuses and caudal brain displacement. This displacement may create tension on enlarged venous sinuses and predispose to venous tears. Intracranial hypotension may stretch and tear large cortical veins crossing the dural space. Reflex vasodilatation in response to pressure on the dura, veins, and dural sinuses by the caudally displaced brain may also increase the risk of subdural bleeding [3,4,14,15]. Cerebellar involvement is most frequent and is likely related to sagging of the cerebellum into the foramen magna after caudal displacement [3,4,14,15].

The volume of CSF drainage is closely related to the development of RIH [3,16]. Particularly, a sudden, large volume of CSF drainage is likely related to RIH, as suggested by Golden JB in the “Comments” to the article by Chaddock, the first report of RIH complicating cervical laminectomy [1]. In our series, both total and 24-hr drainage volumes were significantly different between the patients with versus without RIH, and the latter showed more close relationship with RIH occurrence. To reduce the risk of RIH by lumbar CSF drainage after thoracoabdominal aortic repair, a drainage volume of ≤ 10 mL in any 1-hr period was recommended by Leyvi in 2005 [17]; the Nonprofit Organization Japanese Society of Education for Physicians and Trainees in Intensive Care recommends a rate of ≤ 30 mL per 2 hr. The control of CSF drainage volume should be very important to prevent the occurrence of RIH although the volume of CSF leak during surgery cannot be controlled.

Table 3: The detailed data of the three patients with remote intracranial hemorrhage.

Age/sex	Comorbidities	Pathology	Level	Brain Symptoms	Onset after surgery (h)	Location	Hydrocephalus	Drainage	Prognosis
56F	HT, DM Hypothyroidism	SCT (B)	T-L	Consciousness	12	Rt. Cerebrum Lt. temporal lobe	+	B (5 mm)	Recovered
75M	HT, DM Obesity (BMI=27.9)	OLF	C-T	None	17*	Rt. Vertex Subdural	-	B (3.3 mm)	No change
48F	HT, SAS Obesity (BMI=38.8)	OPLL	T	None	12*	Lt. cerebrum	-	B (5 mm)	No change

HT: Hypertension; DM: Diabetes Mellitus; BMI: Body Mass Index; SAS: Sleep Apnea Syndrome; OPLL: Ossification of the Posterior Longitudinal Ligament; OLF: Ossification of the Ligamentum Flavum; SCT: Spinal Cord Tumor; C: Cervical; T: Thoracic; L: Lumbar

*: hours between the end of the surgery and brain computed tomography examination

Postoperative epidural hematoma is another severe complication in spinal surgery [18]. It is generally recommended in Japan to use wound drainage after spinal surgery in order to prevent this complication [19] although its effect has been reported to be controversial [9-12,19,20]. If a wound drainage system were not used, the discharge volume from the surgical site may decrease, whereas the risk of postoperative epidural hematoma may increase. The platelet reactivity and thrombolytic status of Japanese population are somewhat different from western population [21], which may be the reason that Japanese spine surgeons are more nervous of postoperative epidural hematoma.

In the spinal surgery with durotomy or dural rupture, the postoperative drainage volume should be further difficult to be decided compared with lumbar CSF drainage after thoracoabdominal aortic repair since each case has different conditions of bleeding during and after surgery. If it is too restricted, spinal epidural hematoma may occur while if it is too much, RIH may occur. Thus, the optimal volume of drainage per hour is uncertain. All the patients with RIH in our series had ≥ 736 ml/day drainage while those without RIH had ≤ 790 ml/day. Based on our case series and review of the literature, 500-700 ml/day, namely, 20-30 ml/hr may be reasonable targets of drainage volume after spinal surgery with durotomy or dural rupture. In the present study, we tried to maintain the drainage volume ≤ 200 -240 ml/day when the drainage showed obvious serous bloody condition. However, all the patients with RIH had ≥ 736 ml/day drainage including blood, which indicates the difficulty of controlling the drainage volume.

Now, we have performed the following strategy of treatment for patients with durotomy or dural tear. During surgery, the opened dura mater is water-tightly sutured if possible, and a suction drainage system that has lower, can control negative pressure is used. Drainage with full negative pressure is used when the drainage shows bloody condition. The drainage volume is maintained at 20-30 ml/hr by the height of drainage bag after it moves to serous bloody condition. The drainage tube is removed soon after the drain properties changes significant CSF. The patients are evaluated with brain CT the day after surgery, regardless of brain symptoms, to diagnose RIH at an early stage. However, it is occasionally very difficult to distinguish the drainage condition; with blood dominant or with CSF dominant.

The present study has several limitations. Firstly, the patient population was relatively small and the study period was restricted, which may result in the relatively high incidence of RIH after durotomy or dural rupture. RIH appears to be a rare event and therefore the sample size would need to be larger to draw meaningful conclusions. Secondly, the volume of CSF leakage during surgery cannot be measured as mentioned before since intraoperative suction includes both blood and CSF. We cannot measure CSF and blood individually. Thirdly, we also could not evaluate patients with occult dural tear. It is likely that there were patients with dural tears not confirmed during surgery. Finally, we evaluated the patients by CT only once on the day after surgery because of the problem of radiation exposure although no patients showed brain symptoms >24 hr postoperatively. Despite these limitations, we did establish the incidence of RIH and the possible relationship between RIH and volume of drainage after surgery in the present study.

Conclusion

The incidence of RIH in this study was higher than expected: 0.4%

of all spine surgeries and 1.7% of those with durotomy or dural tear in our institution. RIH was closely related to CSF drainage volume, in particular, with large volume loss within a short time. Spine surgeons should be well aware of this complication and should know how to control drainage volume after spinal surgery.

Authors Contributions

Aizawa had full access to all the data in the study and take responsibility for the integrity of the data and the accuracy of the data analysis. Study concept and design: Aizawa, Ozawa and Itoi. Acquisition or interpretation of data: Aizawa, Ozawa, Ashina, Hashimoto, Kanno, Eto. Draft of the manuscript: Aizawa, Ozawa, Itoi. Study supervision: Itoi.

Compliance with Ethical Standards

The study protocol was approved by the Ethics Committee of Tohoku University Hospital (2015-1-766). Written informed consent was obtained from all included patients.

References

1. Chaddock WM. Cerebellar hemorrhage complicating cervical laminectomy. *Neurosurgery*. 1981;9(2):185-9.
2. Nam TK, Park SW, Min BK, Hwang SN. Remote cerebellar hemorrhage after lumbar spinal surgery. *J Korean Neurosurg Soc*. 2009;46(5):501-4.
3. Estrera AL, Sheinbaum R, Miller CC, Azizzadeh A, Walkes JC, Lee TY, et al. Cerebrospinal fluid drainage during thoracic aortic repair: safety and current management. *Ann Thorac Surg*. 2009;88(1):9-15.
4. Wynn MM, Mell MW, Tefera G, Hoch JR, Acher CW. Complications of spinal fluid drainage in thoracoabdominal aortic aneurysm repair: a report of 486 patients treated from 1987 to 2008. *J Vasc Surg*. 2009;49(1):29-34.
5. Fedorow CA, Moon MC, Mutch WA, Grocott HP. Lumbar cerebrospinal fluid drainage for thoracoabdominal aortic surgery: rationale and practical considerations for management. *Anesth Analg*. 2010;111(1):46-58.
6. Aizawa T, Sato T, Sasaki H, Kusakabe T, Morozumi N, Kokubun S. Thoracic myelopathy caused by ossification of the ligamentum flavum: clinical features and surgical results in the Japanese population. *J Neurosurg Spine*. 2006;5(6):514-9.
7. Brockmann MA, Groden C. Remote cerebellar hemorrhage: a review. *Cerebellum*. 2006;5(1):64-8.
8. Pham MH, Tuchman A, Platt A, Hsieh PC. Intracranial complications associated with spinal surgery. *Eur Spine J*. 2016;25(3):888-94.
9. Bonfield CM, Shabani HK, Kanumba ES, Ellegala DB, Nicholas J. The use of IV-tubing as a closed-suction drainage system during neurosurgical cases in Tanzania. *Surg Neurol Int*. 2013;4:76.
10. Zijlmans JL, Buis DR, Verbaan D, Vandertop WP. Wound drains in non-complex lumbar surgery: a systematic review. *Bone Joint J*. 2016;98-B(7):984-9.
11. Mirzai H, Eminoglu M, Orguc S. Are drains useful for lumbar disc surgery? A prospective, randomized clinical study. *J Spinal Dis Techniq*. 2006;19(3):171-7.
12. Nanba T, Ueno M, Saito W, Imura T, Inoue G, Nakazawa T, et al. Comparison of drainage tubes for closed suction drainage following spinal surgery: a prospective, randomized, clinical study. *J Spine Res*. 2014;5:166-71.
13. Sturiale CL, Rossetto M, Ermani M, Baro V, Volpin F, Milanese L, et al. Remote cerebellar hemorrhage after spinal procedures (part 2): a systematic review. *Neurosurg Rev*. 2016;39(3):369-76.
14. De Noronha RJ, Sharrack B, Hadjivassiliou M, Romanowski CA. Subdural

- haematoma: a potentially serious consequence of spontaneous intracranial hypotension. *J Neurol Neurosurg Psychiatry*. 2003;74(6):752-5.
15. Kelsaka E, Sarihasan B, Baris S, Tur A. Subdural hematoma as a late complication of spinal anesthesia. *J Neurosurg Anesthesiol*. 2003;15(1):47-9.
 16. Dardik A, Perler BA, Roseborough GS, Williams GM. Subdural hematoma after thoracoabdominal aortic aneurysm repair: an underreported complication of spinal fluid drainage? *J Vasc Surg*. 2002;36(1):47-50.
 17. Leyvi G, Ramachandran S, Wasnick JD, Plestis K, Cheeung AT, Drenger B. Case 3--2005 risk and benefits of cerebrospinal fluid drainage during thoracoabdominal aortic aneurysm surgery. *J Cardiothorac Vasc Anesth*. 2005;19(3):392-9.
 18. Al-Mutair A, Bednar DA. Spinal epidural hematoma. *J American Academy of Orthopaedic Surgeons*. 2010;18(8):494-502.
 19. Schroeder GD, Kurd MF, Kepler CK, Arnold PM, Vaccaro AR. Postoperative epidural hematomas in the lumbar spine. *J Spinal Disord Tech*. 2015;28(9):313-8.
 20. Hosono N, Kaito T, Makino T, Mukai Y, Miwa T, Fuji T. Does closed wound drainage really prevent epidural hematoma after lumbar surgery? Investigation upon postoperative magnetic resonance images. *Rinsho Seikei Geka*. 2009;44(4):397-402.
 21. Gorog DA, Yamamoto J, Saraf S, Ishii H, Ijiri Y, Ikaguri H, et al. First direct comparison of platelet reactivity and thrombolytic status between Japanese and Western volunteers: possible relationship to the "Japanese paradox". *Int J Cardiol*. 2011;152(1):43-8.