



Rare Side-Effect of Vagal Nerve Implantation

Herbert Rooijackers, Vincent Vanthuyne and Christian Raftopoulos*

Department of Neurosurgery, St-Luc University Hospital, Belgium

Keywords

Vagal nerve; Epilepsy; Muscle spasms

Clinical Image

Objective: This case report shows a rare side-effect at implantation of Vagal Nerve Stimulation (VNS) during intra-operative system diagnostic testing.

Case Description: VNS is a procedure well known in the literature for treating medically refractory epilepsy. We implanted in September 2014 a VNS on a sixteen-year-old girl with focal cryptogenic temporal lobe epilepsy. She benefited from surgery in May 2011 with a disconnection of the left anterior temporal lobe associated with subpial transactions in the area of Wernicke. The patient suffered from 15 to 20 focal seizures per month with impaired consciousness. Her pharmacological treatment consists in Lamictal Depakine and Frisium. The VNS implantation went uneventful, but during system diagnostic testing at an Output Current of 1.0 mA (set automatically when device is switched off), heavy muscles spasms were observed (platysma, sternocleidomastoid and omohyoid muscles). We repositioned the electrode 1cm caudal on the vagal nerve, but still the contractions occurred during the device diagnostic testing. We tried a lower output current of 0.25 mA overriding the default 1.0 mA setting but still heavy contractions were observed. At a closer look on the vagal nerve we could dissect a small branch of external superior laryngeal nerve, vertical blue tractor. The electrode was attached to the vagal nerve and a piece of muscle tissue (platysma) was positioned between the vagus nerve and external superior laryngeal nerves. System diagnostics was performed at 1.0 mA and no muscle contractions occurred. We reviewed the literature and did not

OPEN ACCESS

*Correspondence:

Christian Raftopoulos, Department of Neurosurgery, University of Catholic Louvain (UCL), 1200 Brussels, Belgium, E-mail: christian.raftopoulos@uclouvain.be

Received Date: 22 Jun 2018

Accepted Date: 12 Jul 2018

Published Date: 16 Jul 2018

Citation:

Rooijackers H, Vanthuyne V, Raftopoulos C. Rare Side-Effect of Vagal Nerve Implantation. Clin Surg. 2018; 3: 2032

Copyright © 2018 Christian Raftopoulos. This is an open access article distributed under the Creative Commons Attribution License, which permits unrestricted use, distribution, and reproduction in any medium, provided the original work is properly cited.

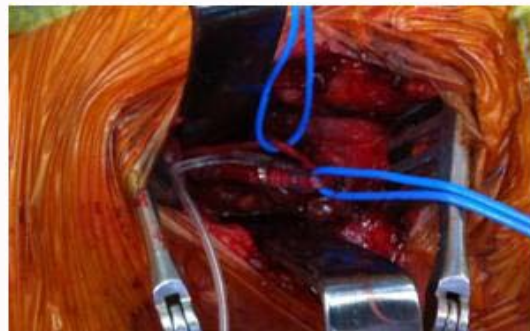

Figure 1: Repositioned the electrode 1cm caudal on the vagal nerve.

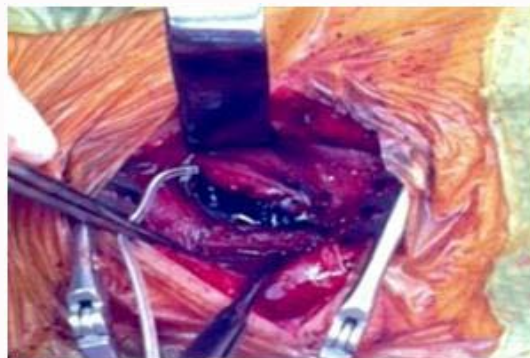


Figure 2: Positioned between the vagus nerve and external superior laryngeal nerves.

find such a case.

Conclusion: In our experience of 220 VNS implantations for medically refractory epilepsy, it is the first case (?) of multiple muscles contraction during vagus nerve stimulation. An additional dissection can suppress this problem.

Disclosure: Dr. H. Rooijackers serves on the speakers' bureau of Cyberonics.