



Rare Pedunculated Trichilemmal Carcinoma – A Case Report

Ashish Vora*, Rohan Gupta, Sourabh Gautam, Yogesh Mundra, Manoj Kela and Rajesh Sharma

Department of Surgery, Dr. Ram Manohar Lohia Hospital, India

Abstract

Trichilemmal carcinoma is a rare hair follicle tumor that arises due to malignant transformation of a benign trichilemmoma. It develops from the outer root sheath of the hair follicle and is found on areas that are exposed to the sun, particularly on the face, ears, scalp, forehead, neck, etc. It's mostly seen in women who are over 40 years of age. It rarely metastasizes to other sites. It is a tan or flesh-colored spot that may resemble a wart. Here we report a very rare case of Trichilemmal carcinoma of right thigh which has an insidious clinical course.

Keywords: Trichilemmal carcinoma; Papillomatous growth; Skin tumour; Hair follicle tumour; Trichilemmoma; Wart; Benign skin tumour

Case Presentation

A 60 year old male presented to OPD with complaints of growth over right thigh since past six years. The swelling was initially small in size but it reached over past two month to its current size of about 12 cm × 12 cm × 3 cm. The swelling was associated with pain which was mild, dull aching, intermittent. The size was of concern to the patient complained of difficulty in walking. Patient is tobacco chewer since past 10 years. On examination, over anterior aspect of mid thigh on right side there was a solitary swelling of size 12 cm × 12 cm × 3 cm, non-tender (Figure 1). The swelling was firm in consistency with irregular bosselated surface and margin, connected to thigh *via* thick peduncle of 5 cm to 6 cm. It had creases that harvested foul smelling discharge.

Investigations

- USG of swelling was suggestive of a heterogeneous predominantly solid, minimally cystic lobulated fungating mass is seen arising from antero-medial compartment of right upper thigh 13.6 cm × 11.6 cm with internal vascularity (arterial flow of low resistance) and few scattered foci of calcifications. Likely involving adductor compartment.
- MRI of right thigh was suggestive of large exophytic predominantly solid, mass lesion is seen in the subcutaneous compartment, in the medial aspect of the upper thigh. It measures about 10.9 cm × 7.2 cm × 13.4 cm in TR × AP × CC axis. No obvious infiltration in the adjacent muscular compartment. No bony involvement seen (Figure 2).
- Trucut biopsy from the swelling was suggestive of Adenocarcinoma (? Skin adnexal tumor)

Management

Wide local excision of mass done with 2 cm margin excised off with hygiene of peduncle. The excised mass then sent for histopathology. Post operative stay was uneventful & patient was discharged. On 4th POD check dress was done and sutures were removed on POD-12.

Histopathology Findings

Macroscopic: Received large skin covered globular mass measuring 12 cm × 9.5 cm × 6 cm. Externally shows lobulated appearance with ulcer measuring 1.3 cm × 1.2 cm. Cut section-well circumscribed, gray white, firm mass seen reaching up to skin measuring 10 cm × 8 cm × 5.4 cm. Circumferential surgical skin resection margins closest 0.4 cm, farthest 1.5 cm away from mass.

Microscopic: Ulcer with tumor. Tumor with skin Sections from growth show tumor composed of cuboidal cells with high N:C ratio, hyperchromatic nuclei, eosinophilic to clear cytoplasm, forming acini, lobules, cords infiltrating fibromuscular tissue. Lobules show hyaline globules and peripheral

OPEN ACCESS

*Correspondence:

Ashish Vora, Department of Surgery,
Dr. Ram Manohar Lohia Hospital, BKS
Marg, New Delhi-110001, India,
E-mail: ashishvora.ms@gmail.com

Received Date: 10 Oct 2019

Accepted Date: 01 Nov 2019

Published Date: 06 Nov 2019

Citation:

Vora A, Gupta R, Gautam S, Mundra Y,
Kela M, Sharma R. Rare Pedunculated
Trichilemmal Carcinoma – A Case
Report. *Clin Surg*. 2019; 4: 2641.

Copyright © 2019 Ashish Vora. This
is an open access article distributed
under the Creative Commons
Attribution License, which permits
unrestricted use, distribution, and
reproduction in any medium, provided
the original work is properly cited.

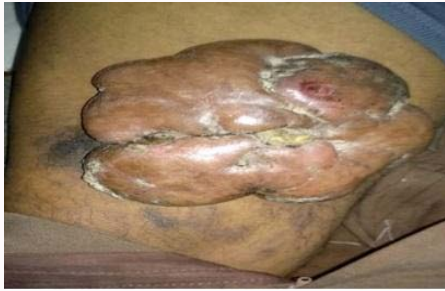

Figure 1: Swelling over the anteromedial aspect of right thigh.

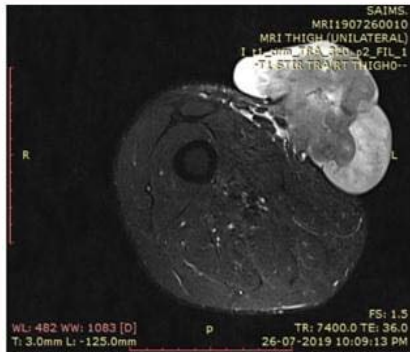


Figure 2: T1 axial contrast enhanced view showing no bony or muscle movement.

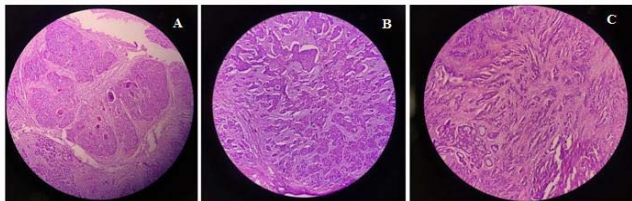


Figure 3: (A) Low power view showing tumour composed of cuboidal cells with high N:C ration forming acini lobules cords, (B) Showing peripheral nuclear palisading, (C) Showing Hyaline Globules.

nuclear palisading with areas of hyalinization and necrosis seen. Tumor reaching up to epidermis causing ulceration, focal areas of keratinization and squamous differentiation seen. Surgical resection base-free of tumor. Circumferential skin resection margins-free of tumor (Figure 3).

Impression: Trichilemmal Carcinoma (Skin adnexal carcinoma).

Discussion

Benign and malignant tumors of skin appendages are of wide spectrum. They can originate from one or more types of adnexal structures found in histological normal skin. TLC is an adnexal tumor derived from the outer layer of the hair follicle of the skin [6]. It has a low incidence and it is found primarily on elderly people's skin due to solar radiations exposure. Like the head, neck and back of hands but other areas like left supraclavicular region, thigh, anterior thoracic wall, upper lip or eyelid were reported [7]. Moreover, a case of axillary TLC with aggressive growth was reported, leading to the amputation of the upper limb, partial resection of the thoracic wall followed by reconstruction [8]. Because TLC is rare and its presentation is similar to other skin tumors, diagnosis is based on the presence of certain features on histological examination of a skin

biopsy. Microscopically, in TLC proliferating clear cells in lobular or trabecular pattern originating from pilosebaceous structures can be observed [9]. The clear cell aspect is due to the glycogen-rich cytoplasm making the tumor difficult to distinguish it from clear cell variants of BCC or SCC. The accumulation of glycogen in the cytoplasm makes it positive in PAS staining. In the large majority of the cases, the lobules are infiltrative, with peripheral palisading consisting of with high-grade atypic cells with frequent abnormal mitotic figures. Thick basement membrane as well as pagetoid spread can be observe. Foci of trichilemmal keratinization, horn cyst, intratumoral hemorrhage and necrosis or cells with subnuclear basal vacuolization can also be seen [10]. No specific stromal aspects are described in the literature. The large majority of the microscopic aspects were detected in our cases. However, immunohistochemical tests were performed in order to certify the diagnosis. Normally, TLC is positive for cytokeratins, namely CK 1, 10, 14, 17 and 19 and sometimes for EMA, attesting the hair origin, and negative for CEA, S-100 protein and other cytokeratins (CK 7, 8, 15, 16, 18 and 19) [11]. The last three stains are used to differentiate TLC from other tumors such as clear cell eccrine carcinomas or visceral clear cell adenocarcinomas as well as melanomas [12]. Our cases met all the immunohistochemical criteria. TLC should be differentiated from other skin tumors, such as squamous cell carcinoma and basal cell carcinoma, which are more common. Complete surgical excision with wide margins (2 cm to 3 cm) is the recommended treatment for trichilemmal carcinoma. Although recurrent trichilemmal carcinoma is uncommon, there have been rare reports where incomplete resections may have led to local recurrences and metastatic spread. Recurrent tumour must be surgically removed. Currently there is no established treatment for metastatic trichilemmal carcinoma but chemotherapy similar to regimens used for squamous cell carcinoma have been used and under evaluation.

References

1. Roismann M, Freitas RR, Ribeiro LC, Montenegro MF, Biasi LJ, Jung JE. Trichilemmal carcinoma: case report. *Ann Bras Dermatol*. 2011;86(5):991-4.
2. Wick RM, Barnhill RL. Tumors with hair follicle and sebaceous differentiation. In: Barnhill RL, Crowson AN, Magro C, Piepkorn M, editors. *Dermatopathology*, 3rd ed. McGraw– Hill Professional. 2010;689-724.
3. Nemetz MA, Da Cunha RM, Reeck P, CarreiraNeto W, Moreira MTS, Coelho MS. Trichilemmal carcinoma: a case study, *Rev Bras Otorrinolaringol*. 2004;70(6):832-5.
4. Chan KO, Lim IJ, Baladas HG, Tan WT. Multiple tumour presentation of trichilemmal carcinoma. *Br J Plast Surg*. 1999;52(8):665-7.
5. Boscaino A, Terracciano LM, Donofrio V, Ferrara G, De Rosa G. Trichilemmal carcinoma: a study of seven cases. *J Cutan Pathol*. 1992;19(2):94-9.
6. Brenn T, McKee PH. Tumors of the hair follicle. In: McKee PH, Calonje E, Granter SR, editor. *Pathology of the skin with clinical correlations*. 3rd ed. Elsevier–Mosby. 200;1531-3.
7. Lai TF, Huilgol SC, James CL, Selva D. Trichilemmal carcinoma of the upper eyelid. *Acta Ophthalmol Scand*. 2003;81(5):536-8.
8. Billingsley EM, Davidowski TA, Maloney ME. Trichilemmal carcinoma. *J Am Acad Dermatol*. 1997;36(1):107-9.
9. Alsaad KO, Obaidat NA, Ghazarian D. Skin adnexal neoplasms--part 1: an approach to tumours of the pilosebaceous unit. *J Clin Pathol*. 2007;60(2):129-44.

10. Kurokawa I, Senba Y, Nishimura K, Habe K, Hakamada A, Isoda K, et al. Cytokeratin expression in trichilemmal carcinoma suggests differentiation toward follicular infundibulum. *In Vivo*. 2006;20(5):583-5.
11. Demirtas Y, Findikçioğlu F, Ayhan S, Özmen S, Üner A, Simsek A, et al. Aggressive tricholemmal carcinoma of the axilla. *Gazi Med J*. 2005;16(1):51-3.
12. Masayuki T, Hideo N, Yurihisa I. Surgical treatment of recurrent trichilemmal carcinoma of the upper eyelid. *Otolaryngol Head Neck Surg (Tokyo)*. 2004;76(10):709-13.