



Quantitative Evaluation of Subzygomatic Depression Secondary to Single Longitudinal Masseter Hypertrophy with Botulinum Toxin A Injection Using Three-dimensional Scanning Technique

Zhang S^{1,2#}, Zhang X^{1,2#}, Chen X^{1,2}, Luo S^{1,2*} and Hao L^{1,2*}

¹The Plastic and Aesthetic Center, The First Affiliated Hospital of Harbin Medical University, P. R. China

²NHC Key Laboratory of Cell Transplantation, Harbin Medical University, P.R. China

#These authors contributed equally to this work

Abstract

Background: Botulinum Toxin-A (BTX-A) injection for masseter hypertrophy may induce decreases in soft tissue bulging degree in the subzygomatic area (subzygomatic depression). This study aimed to investigate the efficacy of Three-Dimensional (3D) scanning technology as a quantitative method to evaluate this complication.

Materials and Methods: Between July 2019 and December 2021, imaging data of patients (aged 18 to 45 years) who received BTX-A injection for single longitudinal masseter hypertrophy were retrospectively analyzed. Changes in the soft tissue bulging degree in the masseter muscle area and subzygomatic area, assessed using Artec EVA 3D scanner, before and 2 and 6 months after surgery were quantitatively analyzed and expressed by linear and surface distance. Statistical analysis was performed on this 3D data.

Results: Between July 2019 and December 2021, 91 patients with single longitudinal masseter hypertrophy were included in the study according to the exclusion criteria and received BTX-A injection. Compared with preoperative values, a statistically significant decrease was noted in the curve line in the subzygomatic area 2 months after the operation ($P < 0.05$), with no statistical difference between the preoperative and 6-month postoperative values ($P > 0.05$). Most patients experienced a decrease in the bulging degree of the soft tissue in the subzygomatic and masseter muscle areas at 2 months postoperatively, and some patients maintained the effect at 6 months after surgery.

Conclusion: BTX-A injection could induce subzygomatic area depression to different extents during treatment of single longitudinal masseter hypertrophy, and 3D scanning technology was an accurate and intuitive way to present reliable data.

Keywords: Three-dimensional scanning technology; Botulinum Toxin-A; Masseter hypertrophy; Subzygomatic area depression

Introduction

The shape of masseter muscles plays an important role in lower facial contours. Because of the uniqueness of oriental aesthetics, modern women prefer a smooth and rounded face shape as people with prominent zygomatic arches are considered masculine [1]. Factors such as heredity and daily habits may lead to varying degrees of unilateral or bilateral masseter hypertrophy, which may affect the aesthetics of lower facial contours [2-5]. The current methods to improve masseter hypertrophy include traditional surgery, Botulinum Toxin-A (BTX-A) injection, and radio frequency ablation [6]. Compared with traditional surgery, which may lead to trauma and scarring, BTX-A has received great attention in shaping facial contours in the past 20 years because of safety and time efficiency [7,8]. Relevant studies have confirmed that decreases in masseter volume after BTX-A injection can be observed using Computed Tomography (CT) and ultrasonography [9-11]. In addition, many studies have reported that patients may experience side effects or complications after BTX-A injection for treating masseter hypertrophy [12-14]. Interestingly, according to the

OPEN ACCESS

*Correspondence:

Sai Luo, The Plastic and Aesthetic Center, The First Affiliated Hospital of Harbin Medical University, No. 23 Youzheng Street, Nangang District, Harbin, Heilongjiang 150000, P. R. China, Tel: +86 (0451) 85555079; E-mail: luosai7766@163.com

Lijun Hao, The Plastic and Aesthetic Center, The First Affiliated Hospital of Harbin Medical University, No. 23 Youzheng Street, Nangang District, Harbin, Heilongjiang, 150000, P. R. China, Tel: +86 (0451) 85555986; E-mail: haolijundoctor@163.com

Received Date: 09 Jan 2023

Accepted Date: 25 Jan 2023

Published Date: 03 Feb 2023

Citation:

Zhang S, Zhang X, Chen X, Luo S, Hao L. Quantitative Evaluation of Subzygomatic Depression Secondary to Single Longitudinal Masseter Hypertrophy with Botulinum Toxin A Injection Using Three-dimensional Scanning Technique. *Clin Surg.* 2023; 8: 3619.

Copyright © 2023 Luo S and Hao L. This is an open access article distributed under the Creative Commons Attribution License, which permits unrestricted use, distribution, and reproduction in any medium, provided the original work is properly cited.

aesthetics in modern oriental countries, decreases in soft tissue bulging of the subzygomatic area caused by BTX-A is considered a type of complication, which may visually highlight the morphology of the zygomatic arch. Few clinical studies have assessed decreases in soft tissue bulging of the subzygomatic area (subzygomatic depression) caused by BTX-A injection [12,15]. Three-Dimensional (3D) scanning technology is an emerging technology that can more accurately evaluate changes in soft tissue bulging of any area around the face after injection compared with other traditional methods, which focuses more on masseter muscle volume change [3]. In this study, 3D scanning technology was used to measure changes in soft tissue bulging degree rather than the muscle volume change in the subzygomatic area to bridge the gaps that little data presents the directly morphological change under this kind of injection.

Thus, we hypothesized that BTX-A injection for treating masseter hypertrophy could cause the complication of soft tissue depression in subzygomatic area and 3D scanning technology as an emerging measurement could directly and accurately present the morphological change in lower face, which is recommended to use to collect data.

Materials and Methods

Patients

Between July 2019 and December 2021, patient data were retrospectively analyzed according to the principles of the Declaration of Helsinki. Patients injected with 60 U BTX-A in total (30 U in every lateral face) with single longitudinal masseter hypertrophy were enrolled. Patients (aged 18 to 45 years) were excluded if they had (1) obvious depression in the subzygomatic area; (2) history of cranio-maxillofacial trauma, operation history, or BTX-A injection in the past 2 years; (4) unqualified, indistinct, and incomplete image data; (5) less follow-up time than 6 months; and (6) changing BMI (Body Mass Index) values less than 0.5 within 6 months.

Surgical methods

A standard 2.5-mL dilution of 100 U BTX-A (Botox) was mixed with normal saline so that each 0.1 ml of liquid contained 4 U. The injection point was determined after the injection region was selected: The lower and the upper boundaries being the mandibular margin and the straight line from the angulus oris to the most inferior part of the earlobe, respectively. Therefore, the anterior and posterior margins of the masseter muscle together with the upper and lower boundaries form a safe region for injection [3]. In this study, patients with single injection point method were included, and the point was the safe area of the deep layer of the masseter muscle and the prominent one.

Image collection

We acquired 2D and 3D image data of patients before and 2 and 6 months after the surgery. Patients maintained head upright position during standard 2D imaging using a digital camera of Nikon N16184 (Nikon Imaging Korea Co., Ltd.). We acquired 3D data using the Artec Eva 3D scanner (Artec Europe Sàrl, Luxembourg), which is a convenient fast scanner that captures the shape of a subject digitally at high resolution to produce high-quality images in the shortest time. Because of the 50-micron scanning accuracy and 100-micron resolution, the device can efficiently scan small objects with complex details and sharp edges. The software of Artec Eva 3D called Artec Studio 13 Professional calculates the linear distance, curve distance, path, surface distance, and angle according to scan data [16].

The same physician acquired all images using the same machine.

Patients with their head upright and facial muscle relaxed were photographed using the Artec Eva 3D scanner with a high-resolution camera probe at a circle distance of approximately 30 cm to 50 cm. Artec Eva 3D restored the captured information to a 1:1 3D digital image model, and the scan results were not affected by the probe, patients' body surface distance-, and their position.

Marker point selection

Representative body surface marker points were selected as shown in Figure 1: Earlobe point (D), angulus oris point (F), chin apex point (G); Line DF was the surface distance from the earlobe point to the angulus oris point; Line DG was the surface distance from the earlobe point to the chin apex point, and the change in masseter volume was expressed by the change in length of the lines DF and DG postoperatively compared with preoperative values. Figure 1b: The width of the lower face (AA1) was the widest straight distance of the lower face in a positive view. Figure 1c: Postoperative 3D images were superimposed on preoperative images to produce cloud figures, with red representing the increased tissue bulging degree and blue representing the decreased tissue bulging degree. Point J was the point that the soft tissue bulging degree changed most in the masseter area, and ΔJ was the bulging degree change in the masseter area. With tragus point as point I and nasal wing as point E, a vertical line was made from point J to the IE line, crossing at the point K, connecting JK, and taking the midpoint as L that was considered the soft tissue bulging degree measurement point in the subzygomatic area. ΔL represented the soft tissue bulging degree change in the subzygomatic area.

Grading

Three plastic surgeons not involved in this study and three non-medical practitioners were invited to analyze and grade the depression in the subzygomatic area and assess the therapeutic effect based on 2D images collected at 2 months postoperatively compared with their preoperative counterparts. The depression was graded according to four levels: (1) no significant change; (2) mild change; (3) obvious change; and (4) significant change. Including the consistent grading results of these 2D data agreed by more than 3 persons, the involved data were quantitatively analyzed using 3D scanning technology to classify the surface bulging degree change range at point J and point K (Table 1).

According to the grade of measured point surface bulging degree change, every lateral case morphological change in the subzygomatic and therapeutic areas was analyzed using 3D scanning technology at 2 months preoperatively 2 months and 6 months postoperatively.

Statistical analyses

Metrological data satisfying normality tests are presented as mean \pm Standard Deviation (SD) and statistically analyzed using the SPSS 20.0 software (GraphPad Software, Inc., La Jolla, CA, United States). All statistical analyses were performed using paired t-tests, with p-values <0.05 considered statistically significant.

Results

Among the enrolled 113 patients, 91 (aged 18 to 45 years, average age, 31.7 years) (19 male and 72 female) were included and retrospectively analyzed according to the exclusive criteria (182 lateral sample sizes). All the patients included had qualified and complete image data, who are Asian patients with single longitudinal masseter hypertrophy (mainly in northeast China), and there was

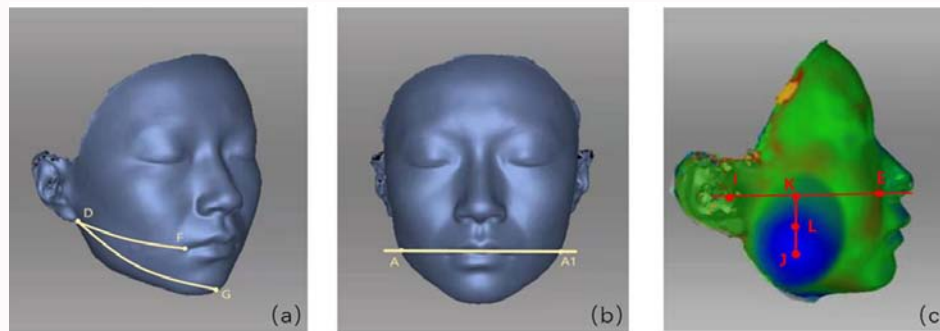


Figure 1: Schematic diagram of measuring method. (a) Marking points on the body surface of the lower face. Earlobe point (D); angulus oris point (F); chin apex point (G); the length changes of Line DF and Line DG show the therapy effect on master muscle. (b) Measuring width of the lower face. The horizontal line according the double angulus oris level intersects with the neutral face at point A and point A1. The length of AA1 shows the therapy effect of BTX-A. (c) The measured surface point changes in the treatment area and sub-zygomatic area are indicated. Point J is the surface point bulging degree changes most in masseter area. Point L is the midpoint of vertical line JK of connected line IE.

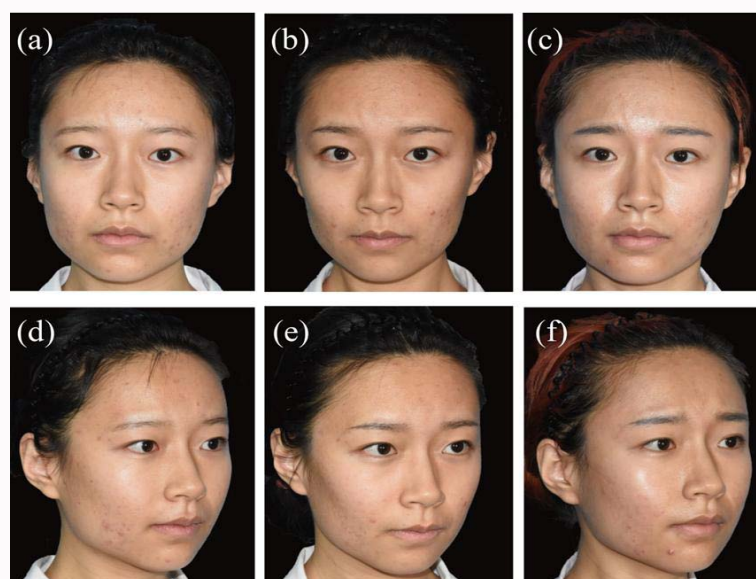


Figure 2: Comparison of the photos of the 25-year-old patient before operation, 2 months and 6 months after operation. Preoperative (a), postoperative 2 months (b) and 6 months (c) neutral position. Preoperative (d), postoperative 2 months (e) and 6 months (f) oblique position.

no significant difference in the anatomical structure of the masseter. Individual cases with obvious weight changes before and after surgery have been excluded, and the fluctuation of BMI of enrolled patients was under 0.5, and the age of male and female patients conforms to the normal distribution.

A 25-year-old female patient with single longitudinal masseter hypertrophy received a 1-point (30 U at each point) BTX-A injection within the safe region and 60 U in total. At 2 months postoperatively, the width of the lower face significantly reduced, the mandibular line was sharper, the angle of the mandibular angle was softer, and the subzygomatic area was significantly depressed than those before surgery (Figure 2).

A 26-year-old female patient with single longitudinal masseter hypertrophy received a 1-point (30 U at each point) BTX-A injection within the safe region, and the total dose was 60 U. At 2 months postoperatively, the width of the lower face was significantly reduced, the lower contour was smoother, and the soft tissue bulging degree in the subzygomatic area was significantly decreased compared with the preoperative counterparts (Figure 3).

Moreover, in the lower facial curve distance measurement project of the 26-year-old female patient, the length of the DF line in this case was 109.17 mm before surgery, 103.79 mm at 2 months after the surgery, and 107.05 mm at 6 months after the surgery. The length of the DG line in this case was 128.01 mm before the surgery, 122.57 mm at 2 months after the surgery, and 127.56 mm at 6 months after the surgery. In the soft tissue bulging degree measurement project, "-" indicated a decrease in soft tissue bulging degree, and blue areas indicated a corresponding location depression. The bulging degree of soft tissues in the treatment area decreased by 3.573 and 0.913 mm at 2 and 6 months after the surgery, respectively, compared with their preoperative counterparts. The bulging degree of soft tissues in the subzygomatic area decreased by 1.173 and 0.592 mm at 2 and 6 months after the surgery, respectively, compared with their preoperative counterparts. Furthermore, the bulging degree of the soft tissue in the subzygomatic area decreased 2 months after the surgery, and the bulging degree of the soft tissue in the masseter area significantly reduced (Figure 4).

According to the statistical analyses, the length of AA1 (n=91), DF (n=182), and DG (n=182) significantly reduced compared with



Figure 3: Comparison of the photos of the 26-year-old patient before operation, 2 months and 6 months after operation. Preoperative (a), postoperative 2 months (b) and 6 months (c) neutral position. Preoperative (d), postoperative 2 months (e) and 6 months (f) oblique position.

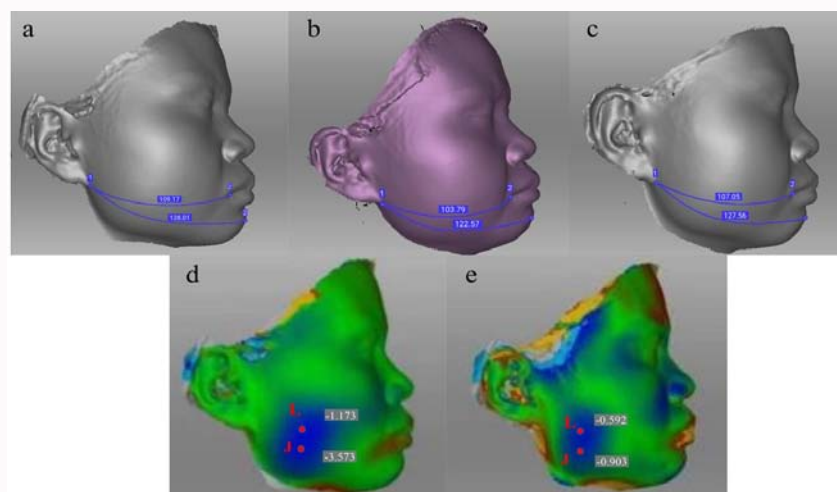


Figure 4: The results of 3D scanning measurement of the 26-year-old female patient. (a) The length of DF and DG before operation. (b) The length of DF and DG at 2 months after operation. (c) The length of DF and DG at 6 months after operation. (d) Comparison between 2 months after operation and before operation. (e) Comparison between 6 months after operation and before operation.

preoperative values and 2-month postoperative values ($P < 0.001$). However, the length of the AA1, DF, and DG were not significantly different between 6 months post-surgery and before surgery ($P > 0.05$) (Figure 5).

After three plastic surgeons and three non-medical practitioners completed the analyses, graded the depression in the subzygomatic area, and assessed the therapeutic effect of these postoperative 2-month 2D data and chose the consistent 3D quantitative analysis results, the corresponding quantification results of the measured surface points in the masseter area ΔJ and in the subzygomatic area ΔL graded into four levels were as follows (Table 1). According to the degrees, after 2 months of injection, the percentage of lateral cases with a soft tissue bulging degree reduction in the masseter area was 96.1%, of which 11 lateral cases (6.0%) had mild change, 132 lateral cases (72.5%) had obvious changes, and 32 lateral cases (17.6%) had significant changes. The percentage of lateral cases with

soft tissue bulging degree reduction in the subzygomatic area was 95.6%, of which 39 lateral cases (21.4%) had mild changes, 128 lateral cases (70.3%) had obvious changes, and 7 lateral cases (3.8%) had significant changes. After 6 months of injection, the lateral cases with soft tissue bulging degree reduction in the masseter area were only 61 (33.5%), and all of which were mild change. The lateral cases with subzygomatic soft tissue bulging degree reduction were 81 (44.5%), of which 71 lateral cases (39.0%) had mild change, 10 lateral cases (5.5%) had obvious changes, and the rest of lateral cases had no significant changes (Figure 6).

Discussion

Chinese women with prominent zygomatic arches are considered aggressive and masculine [17]. Roundly facial contours are more acceptable to eastern aesthetics, thus the shape of the subzygomatic area occupies a very important place in the Asian facial aesthetics [18]. In recent years, BTX-A injection for treating masseter hypertrophy

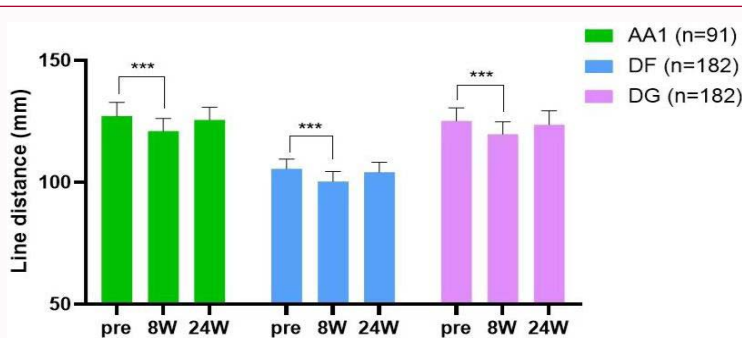


Figure 5: Measurement of the width (AA1) and the curve distance (DF, DG) of lower face over 6 months post-operation. ***p<0.001

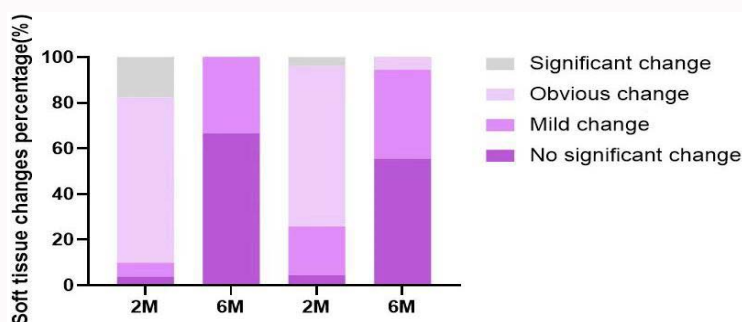


Figure 6: Percentage of measured points bulging degree changes degree (point J and point L) quantitative analyzed by 3D scanning technology after BTX-A treatment in masseter and sub-zygomatic areas at postoperative 2-month and 6-month.

Table 1: The quantitative classification of measurement points bulging degree (point J and point L) change degree in masseter muscle area and sub-zygomatic area.

	No significant change (mm)	Mild change (mm)	Obvious change (mm)	Significant change (mm)
Masseter area	$\Delta J \leq 1.00$	$1.00 < \Delta J \leq 3.00$	$3.00 < \Delta J \leq 5.00$	$\Delta J > 5.00$
Sub-zygomatic area	$\Delta L \leq 0.50$	$0.50 < \Delta L \leq 1.00$	$1.00 < \Delta L \leq 2.00$	$\Delta L > 2.00$

sometimes has resulted in of subzygomatic area depression, which may induce more prominent zygomatic arch visually. Therefore, the current study assessed in depth the effect of BTX-A injection on the soft tissue in the subzygomatic area after treatment.

Based on reviewed literature, maximum research on changes in facial soft tissues was achieved by measurement methods such as graphic pictures, CT scan and ultrasound, where the accuracy is slightly lower than that of 3D scanning technology [10,12]. For quantitative evaluation, 3D scanning technique was used to accurately assess the soft tissue bulging degree changes in the masseter area after BTX-A injection for single longitudinal masseter hypertrophy, and to focus on concurrent soft tissue changes in the subzygomatic area. The advantages of the 3D measurement method include (1) no need to directly touch the face, which avoids squeezing the soft tissue and deformation [19] and (2) theoretically, the error rate of the camera system and the digital reconstruction system is minimal [20]. The digital measurement can accurately observe the bulging degree of depression in the subzygomatic area, which can provide scientific guidance for using BTX-A in the treatment of the masseter hypertrophy [11].

The shape of masseter muscle hypertrophy can be divided into five types: minimal type (no obvious bulge), single longitudinal type (mono type), double longitudinal type, triple longitudinal type, and excessive type (massive single bulge) [21]. Injection treatment is personalized according to the classification of the masseter muscle.

Here we carried out a standardized study, to find the most prominent point on the single longitudinal masseter muscle to inject BTX-A 60 U in total. The experiment would not only ensure the efficacy, but also unify the treatment method, which facilitates the observation and measurement of the bulging degree change of soft tissue in the masseter muscle area and the subzygomatic area.

Due to the anatomical characteristics of the subzygomatic area, there are no obvious body surface markers, so it is impossible to settle a specific range to measure the volume changes of soft tissue and muscle in the subzygomatic area. As an alternative, the curve length change was selected to reflect the degree of depression. Additionally, the nasal alar point and tragus point were selected as auxiliary markers to assist in 3D measuring the degree of depression in the subzygomatic area.

The results of 3D quantitative analysis on bulging degree change of surface point (point J and point L) were consistent with 2D photos of involved lateral cases: The mean length of DF and DG and the surface bulging degrees at point J reduced, which shows the therapeutic effect of BTX-A injection. Meanwhile, the surface bulging degrees at point L reduced, which shows the depression in the subzygomatic area. The reason behind injection causing the depression phenomenon is due to the reduced braced force of masseter muscle under the soft tissue in the subzygomatic area, which caused effect of BTX-A on the masseter muscle inducing volume reduction of masseter muscle. In addition, the reduced braced force also leads to the bulging reduction of the

buccal fat pad.

According to the experimental results, the percentage of lateral cases with obvious subzygomatic depression reached peak 2 months after the surgery, but at 6 months after the surgery, the percentage of lateral cases with obvious subzygomatic depression decreased significantly, while the percentage of lateral cases with mild depression increased relatively. At 6 months, only a few patients had mild changes in masseter area, while there was no significant change compared with preoperative period. There are several reasons for this phenomenon. First, the 6-month postoperative subzygomatic depression might be caused by the gradual metabolism of BTX-A in the human body, the effect gradually weakened, thus the degree of depression in the subzygomatic area was alleviated and the thin muscle in this area might have reacted more obvious to BTX-A than masseter muscle. Second, there was still a mild volume change in the masseter area, slight depression change in masseter muscle might cause soft tissue bulging degree reduction in subzygomatic area. Third, soft tissue depression in subzygomatic area might be more obvious than the counterpart in masseter area in visual. Therefore, to maintain the shape of the masseter muscle further, the injection should be repeated regularly on time. The data suggested that the subzygomatic depression lasts longer than the soft tissue bulging degree decrease in masseter muscle area.

Based on the data collected, we found a soft tissue bulging degree reduction in the subzygomatic area, which might be related to the injection site: Most prominent point of the masseter muscle in the safe injection region was selected as a single injection point—common injection method for treating single longitudinal masseter hypertrophy, depending on the shape of the patient's masseter muscle [10,21]. The results show that the subzygomatic depression can also occur under this injection method, which might be caused by low concentration of the buffer with high speed of diffusion. Additionally, when the injection points are too close to the upper boundary of the safe region, there is reduction in the bulging degree of the subzygomatic area. To prevent this complication, we suggest that when the most prominent point is close to subzygomatic area, the injection point at the lower part of the masseter is recommended, and the diffusion area needs to cover the most prominent point of the masseter muscle. In addition, a high concentration of BTX-A solution is recommended to reduce the drug diffusion in clinical practice.

Compared with 3D scanning technology, the disadvantages of CT and MRI are that patients need to pay during examination and that the methods of scanning and measuring focusing on the volume change of muscle are too complex and indirect to obtain measurement results. However, 3D scanning technology could build a 3D scanning module in few minutes and then superimpose two 3D scanning images to build a cloudy image that can directly show the soft tissue bulging change and present the morphological change in subzygomatic and masseter areas.

This study revealed a phenomenon that patients with single longitudinal masseter hypertrophy who receive BTX-A injection could experience complications of subzygomatic depression, which visually causes patients' lower face to sag. Only the single longitudinal masseter hypertrophy type was selected in this standardized experiment, so that other types of masseter hypertrophy could be excluded. While the maximum follow-up time was only 6 months, the subzygomatic depression in some patients did not fully recover, so the follow-up time should be appropriately extended in such patients to

summarize subzygomatic soft tissue changes and recovery rules and also other types of masseter hypertrophy should be study. Since the number of female patients was larger than male patients in this study, there was still bias existing in this study, which should be settled by expanding the sample size to include more male patients. In addition, in future experiments, we will focus on the association between the distance from most prominent point of masseter hypertrophy to the safe region upper boundary and the degree or the location of the subzygomatic depression.

Conclusion

BTX-A is an efficient therapy for patients with single longitudinal masseter hypertrophy, while it could result in the depression in subzygomatic area variably according to the data selected by 3D scanning technology. The 3D scanning technology may be an accurate and intuitive method for presenting reliable data given that a proper injection point is provided to avoid this complication.

Acknowledgment

Thanks for the experimental site and equipment provided by The Plastic and Aesthetic Center, The First Affiliated Hospital of Harbin Medical University.

Authors' Contribution

Zhang SQ and Zhang X wrote the main manuscript text and collected all data. Zhang SQ prepared figures 1-6 and Table 1. Chen XY performed the statistical analysis. All authors reviewed the manuscript.

Funding

This study was supported by National Natural Science Foundation of China (No. 82102356), Outstanding Young Medical Talents Training Funding Project of The First Affiliated Hospital of Harbin Medical University (No. 2021J05), Scientific Research and Innovation Foundation of The First Affiliated Hospital of Harbin Medical University (No. 2019B24), Applied Technology Research and Development Project of Heilongjiang Province (No. GA20C019) and Postgraduate Research & Practice Innovation Program of Harbin Medical University (YJSCX202088HYD).

References

1. Samizadeh S, Wu W. Ideals of facial beauty amongst the Chinese population: Results from a large national survey: An update. *Aesthetic Plast Surg.* 2020;44(4):1184-5.
2. Kim JH, Shin JH, Kim ST. Effects of two different units of botulinum toxin type A evaluated by computed tomography and electromyographic measurements of human masseter muscle. *Plast Reconstr Surg.* 2007;119(2):711-7.
3. Chang CS, Lin S, Wallace CG, Hsiao YC, Lin CM, Kang GCW, et al. Masseter muscle volume changes evaluated by 3-dimensional computed tomography after repeated botulinum toxin A injections in patients with square facial morphology. *Ann Plastic Surg.* 2019;82(1S):S29-S32.
4. Lindern JV, Niederragen B, Appel T. Type A botulinum toxin for the treatment of hypertrophy of the masseter and temporal muscles: An alternative treatment. *Plast Reconstr Surg.* 2001;107(2):327-32.
5. Smyth AG. Botulinum toxin treatment of bilateral masseteric hypertrophy. *Br J Oral Maxillofac Surg.* 1994;32(1):29-33.
6. Min Li, Lai Gui. Progress in surgical treatment of mandibular Angle hypertrophy. *Chin J Aesthet Med.* 2006;15(7):866-70.
7. Almukhtar RM, Fabi SG. The masseter muscle and its role in facial

- contouring, aging, and quality of life: a literature review. *Plast Reconstr Surg*. 2019;143(1):39e-48e.
8. To EW, Ahuja AT, Ho WS, Wong WK, King WW, Pang PC, et al. A prospective study of the effect of botulinum toxin A on masseteric muscle hypertrophy with ultrasonographic and electromyographic measurement. *Br J Plastic Surg*. 2001;54(3):197-200.
 9. Kim HJ, Yum KW, Lee SS, Heo MS, Seo K. Effects of botulinum toxin type A on bilateral masseteric hypertrophy evaluated with computed tomographic measurement. *Dermatol Surg*. 2003;29(5):484-9.
 10. Choe SW, Cho WI, Lee CK, Seo SJ. Effects of botulinum toxin type A on contouring of the lower face. *Dermatol Surg*. 2005;31(5):502-8.
 11. Adriaens J, Loon BV, Ingels KJ, Berge SJ, Maal TJ. Three-dimensional stereophotogrammetric method of quantifying the effect of botulinum toxin type A injections on masseter hypertrophy. *Plast Reconstr Surg*. 2012;130(2):376e-378e.
 12. Peng HLP, Peng JH. Complications of botulinum toxin injection for masseter hypertrophy: Incidence rate from 2036 treatments and summary of causes and preventions. *J Cosmet Dermatol*. 2018;17(1):33-8.
 13. No YA, Ahn BH, Kim BJ, Hong CK. Three-dimensional CT might be a potential evaluation modality in correction of asymmetrical masseter muscle hypertrophy by botulinum toxin injection. *J Cosmet Laser Ther*. 2016;18(2):113-5.
 14. Few JW. Book Review: Botulinum Toxin: Procedures in Cosmetic Dermatology Series. *Aesthet Surg J*. 2013;(7):E1-E2.
 15. Yeh YT, Peng JH, Peng HLP. Literature review of the adverse events associated with botulinum toxin injection for the masseter muscle hypertrophy. *J Cosmet Dermatol*. 2018;17(5):675-87.
 16. Wang SY, Luo S, Hao LJ. Application of 3D imaging measurement technology in evaluation of the effect of SVF-GEL injection in chin augmentation. *Chin J Aesthet Plast Surg*. 2020;31(08):462-5.
 17. Dong GX, Li, Lu J, Huang Y. Application of the bracing system in reduction Malarplasty in Asian Population. *Aesthet Plast Surg*. 2020;44(1):114-21.
 18. Chang CS, Kang GC. Achieving ideal lower face aesthetic contours: combination of tridimensional fat grafting to the chin with masseter botulinum toxin injection. *Aesthet Surg J*. 2016;36(10):1093-100.
 19. Bockey S, Berssenbrügge P, Dirksen D, Runte C. Computer-aided design of facial prostheses by means of 3D-data acquisition and following symmetry analysis. *J Craniomaxillofac Surg*. 2018;46(8):1320-28.
 20. Lu JM, Wang MJJ. Automated anthropometric data collection using 3D whole body scanners. *Expert Syst Appl*. 2008;35(1-2):407-14.
 21. Xie Y, Zhou J, Li H, Cheng C, Herrler T, Li Q. Classification of masseter hypertrophy for tailored botulinum toxin type A treatment. *Plastic Reconstructive Surg*. 2014;134(2):209e-218e.