



Prophylactic Endoscopic Vacuum Therapy in Esophagogastric Anastomosis? Let's do it

Guedes HG^{1*}, Viana BO², Oliveira HA³ and Ugalde PA⁴

¹Division of Gastrointestinal Endoscopy, Sirio-Libanes Hospital, Brazil

²Centro Universitário de Brasília, Brazil

³Division of Thoracic Surgery, Sirio-Libanes Hospital, Brazil

⁴Institut Universitaire de Cardiologie et de Pneumologie de Québec, Canada

Abstract

The use of Vacuum Therapy (PEVT) is a modern approach that aims to treat possible complications from esophagectomy, such as leakage of the gastroesophageal anastomosis. Before that, the prophylactic use of the method, especially in high-risk patients, aims to prevent these complications, by accelerating the healing process. With the use of only one device, it is possible to allow post-pyloric feeding and vacuum therapy, ensuring patient recovery, hospital discharge and earlier oral nutrition.

Keywords: Endoscopic vacuum therapy; Esophagectomy; Endoscopy; Vacuum assisted closure

Introduction

The high effectiveness of Vacuum Endoscopic Therapy (EVT) as a rescue therapy has induced few authors to use EVT prophylactically in high-risk patients undergoing esophagectomy for locally advanced esophageal cancer [1-6]. Here, we describe a case report with an innovative handmade device.

Case Presentation

A 52-years-old male patient, with Squamous Cell Carcinoma (SCC) of the middle esophagus and paraesophageal PET/CT positive lymph nodes, underwent neoadjuvant therapy with chemoradiotherapy with an interval of 6 weeks (CROSS protocol). Subsequently, without gastric emptying, he underwent robotic esophagectomy by the Ivor Lewis technique and with sutured neck anastomosis with stapled intrathoracic anastomosis. The intraoperative upper endoscopic evaluation confirmed a good gastric tube axis and mild anastomotic edema and ischemia. A preemptive endoscopic vacuum system composed of a handmade polyurethane sponge device (Granufoam, KCI-3M. USA) was attached to a triple-lumen nasoenteric tube (Freka Trelumina 16/9 Ch, Fresenius Kabi, United Kingdom) through sutures, preventing their migration, and installed in the anastomosis. Anastomotic negative pressure and a post-pyloric enteral nutrition was ensured (Figure 1). EVT was set at - 125 mmHg with high and continuous intensity, during 5 days (E-vac, KCI-3M. USA). Enteral diet was started on postoperative day one. At postoperative day 5, the endoscopic review showed a complete healed anastomosis (Figure 2). The EVT was removed and the oral nutrition was started. On postoperative day 8, the nasoenteric tube was removed and the patient was discharged home on full pasty diet without drains.

Results and Discussion

Esophagogastric and esophageal anastomoses have a high rate of complications that can vary from 5% to almost 30% [1]. Endoscopic Vacuum Therapy (EVT) is a modern endoluminal approach to treat gastrointestinal acute leaks and fistulas through a less invasive method and with at least similar results than the standard therapy [2]. Healing process is accelerated through: Macrodeformation, microdeformation, changes in mucosa perfusion and exudate control with bacterial clearance [3] leading to granulation tissue formation and reepithelization with mucosal recovery. This case describes an uneventful postoperative recovery of esophagectomy with cervical gastroesophageal anastomosis with the use of preemptive EVT. To our knowledge, no prophylactic methods are described to prevent gastroesophageal anastomotic leak, but in our opinion, PETV can be a game-changing approach. Neumann et al. [4] in 2017 reported the effectiveness of treatment

OPEN ACCESS

*Correspondence:

Hugo Gonçalo Guedes, Division of Gastrointestinal Endoscopy, Sirio-Libanes Hospital, Brasília - DF 70200-730, Brazil, Tel: +55-61-99660-0860; E-mail: hugoguedes@yahoo.com.br

Received Date: 04 Jan 2021

Accepted Date: 20 Jan 2021

Published Date: 22 Jan 2021

Citation:

Guedes HG, Viana BO, Oliveira HA, Ugalde PA. Prophylactic Endoscopic Vacuum Therapy in Esophagogastric Anastomosis? Let's do it. *Clin Surg*. 2021; 6: 3035.

Copyright © 2021 Guedes HG. This is an open access article distributed under the Creative Commons Attribution License, which permits unrestricted use, distribution, and reproduction in any medium, provided the original work is properly cited.




Figure 1: Simple devices that used to manufactured the vacuum device and promotes the aspiration therapy and enteral nutrition in a only nasoenteric tube.

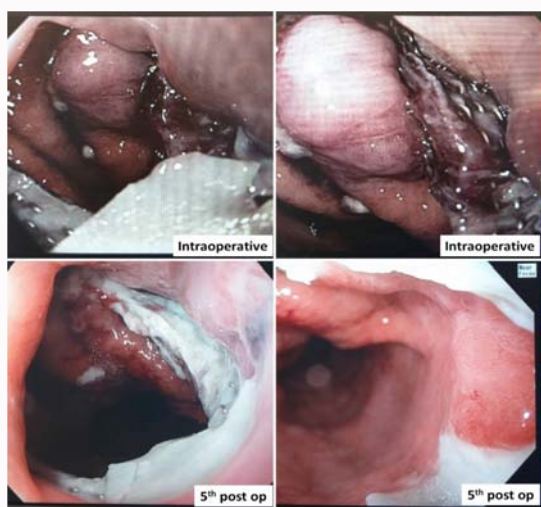


Figure 2: Final endoscopic anastomosis aspect at 5th post-operative day. A good and total healing appearance without complications.

with EVT in cases of mucosal ischemia, before anastomotic fistula. Of the 8 patients, 6 had complete recovery of the mucosa and 2 developed anastomotic leak that resolved with continuous EVT [5]. The use of PEVT in post-esophagectomy patients to prevent anastomotic leak is a new concept and was first described by Loske [6] in a case of retro-esophageal schwannoma with partial esophageal resection and cervical end-to-end esophagoesophagostomy cervical anastomosis. PEVT was stopped at post-operative day 3 and the anastomosis was hidden within the circular patterned epithelium without complications. Subsequently, Gubler et al. [5] was the first to report a series of 19 patients using intraoperatively PEVT in esophagogastric anastomosis. Only one patient with significant morbidity had a 2nd EVT installed on postoperative day 12. In total, 20 EVTs were successfully performed with zero postoperative mortality and no

complications in 19 of the 20 the procedures performed. The EVT device was removed three to six days after surgery and most had an uneventful transition to a normal diet. Displacement of the nasogastric tube, on the first postoperative day, was a common complication in up to 62% of patients. The innovation in our case is the possibility of post-pyloric feeding and the use of negative aspiration therapy with a single device. An open-pored polyurethane sponge is fitted to a 150 cm long (with 40 cm in length of its jejunal component) triple lumen gastric tube, sufficient to insert the post-pyloric tube and enteral nutrition avoiding gastric reflux. The hand molded polyurethane sponge (10 cm × 1.5 cm) is fixed in the multiperforated suction area and positioned under direct vision at the level of the esophagogastric anastomosis. This lumen is connected to the negative pressure pump set at 125 mmHg continuous high negative pressure therapy. This level has been validated by previous reports (REFs). The adoption of this sponge allows easy positioning with transnasal insertion, without the overtube, providing a large area of negative pressure that will protect not only the anastomosis, but also part of the gastric tube. With the handmade device patients do not need a surgical jejunostomy, which also decreases the time and morbidity of the surgery.

Conclusion

We have presented a case in which Preemptive EVT (PEVT) was used with the placement of a unique handmade device, in order to allow vacuum therapy and enteral feeding with a single technique. In reporting this case, we hope to analyze the use of PEVT, especially in high-risk patients, in order to prevent complications of anastomosis.

References

1. Min YW, Kim T, Lee H, Min BH, Kim HK, Choi YS, et al. Endoscopic vacuum therapy for postoperative esophageal leak. *BMC Surg.* 2019;19(1):37.
2. Scognamiglio P, Reeh M, Karstens K, Bellon E, Kantowski M, Schön G, et al. Endoscopic vacuum therapy versus stenting for postoperative esophago-enteric anastomotic leakage: Systematic review and meta-analysis. *Endoscopy.* 2020;52(8):632-42.
3. de Moura DTH, de Moura BFBH, Manfredi MA, Hathorn KE, Bazarbashi AN, Ribeiro IB, et al. Role of endoscopic vacuum therapy in the management of gastrointestinal transmural defects. *World J Gastrointest Endosc.* 2019;11(5):329-44.
4. Neumann PA, Mennigen R, Palmes D, Senninger N, Vowinkel T, Laukoetter MG. Pre-emptive endoscopic vacuum therapy for treatment of anastomotic ischemia after esophageal resections. *Endoscopy.* 2017;49(5):498-503.
5. Gubler C, Vetter D, Schmidt HM, Müller PC, Morell B, Raptis D, et al. Preemptive endoluminal vacuum therapy to reduce anastomotic leakage after esophagectomy: A game-changing approach? *Dis Esophagus.* 2019;32(7).
6. Loske G, Schorsch T, Müller CT. First report of intraluminal Endoscopic Negative Pressure Therapy (ENPT) for anastomotic prophylaxis in a case of tubular resection of cervical esophagus. *Clin Surg.* 2017;2.