



# Primary Tuberculosis of the Oral Cavity Presenting as the Ulcers: A Case Report

Meng Yu Li<sup>1</sup>, Zhi Yuan Zhang<sup>1</sup>, Chi Yang<sup>1</sup>, Zeng Tong Zhou<sup>2</sup> and Shaoyi Wang<sup>1\*</sup>

<sup>1</sup>Departments of Oral Surgery, Shanghai Ninth People's Hospital, College of Stomatology, Shanghai Jiao Tong University School of Medicine, National Clinical Research Center of Oral Disease, China

<sup>2</sup>Department of Oral Mucosal Diseases, Shanghai Key Laboratory of Stomatology, Shanghai Ninth People's Hospital, Shanghai Jiao Tong University School of Medicine, China

## Abstract

Tuberculosis is an infectious and chronic granulomatous disease, which involves almost any organ in the body. Here we report a rare presentation of primary oral tuberculosis in a 51-year-old male, who presented to us with ulcers of the tongue, palate and buccal mucosa. This case emphasizes the importance of early diagnosis of primary oral tuberculosis. Biopsy and histopathological examination revealed tuberculous etiology of the lesion and the patient responded well to antitubercular therapy. The underdiagnosis of extrapulmonary tuberculosis lesions, along with an emerging global resistance to antitubercular drugs, warrants an increased awareness of the involvement of mycobacterium tuberculosis in atypical lesions of oral cavity. Clinicians should be therefore aware of the possible occurrence of oral lesions of tuberculosis and consider it while making a differential diagnosis of suspicious oral ulcers.

**Keywords:** Oral tuberculosis; Primary lesions; Underdiagnosis; Antitubercular therapy

## Introduction

Tuberculosis, as known universally, a chronic infectious disease, is caused by *Mycobacterium tuberculosis*, an acid fast *Bacillus* that is transmitted primarily through the respiratory tract [1]. It chiefly affects the pulmonary system, but it also can involve extrapulmonary site too. Oral tuberculosis is a rare manifestation of extrapulmonary tuberculosis, which is nonspecific in its clinical presentation with approximately 0.1% to 5% of all tuberculosis infections [2-4]. It can be misdiagnosed especially when oral lesions are present before systemic symptoms become apparent.

Nowadays, as the emergence of drug-resistant tuberculosis and acquired immune-deficiency syndrome, oral manifestations of tuberculosis are re-appearing alongside many forgotten extrapulmonary infections [5]. Oral lesions of tuberculosis are mainly secondary to pulmonary tuberculosis and rarely primary in origin [6,7]. Here we report a case of primary oral tuberculosis with an unusual presentation. In this case, the patient presented with ulcers of the tongue, palate and buccal mucosa without respiratory disease or symptoms. Histological analysis eventually confirmed the diagnosis, by finding necrotizing granulomas and demonstrating acid-fast *Bacilli*.

## Case Presentation

A 56-year-old male patient presented at the Department of Oral Surgery, Shanghai Ninth People's Hospital with chief complaints of severe pain and oral ulcerations. The ulcer was initially painless but became painful later with increased severity over time. And the sore tongue caused difficulty in eating, drinking, swallowing, and even talking. But there was no history of fever, cough and weight loss. There was no history of diabetes, hypertension, or any other significant disease including pulmonary tuberculosis.

On examination, he had three superficial ulcerated lesions of the tongue at the tip and lateral margin, that respectively measured 1.5 cm × 2.0 cm, 1.5 cm × 1.0 cm (Figure 1A) and 1.5 cm × 1.5 cm (Figure 1B) with surrounding erythema and indurations, and the ulcer was covered with sloughing tissue. There was also a superficial ulcer, 0.6 cm × 0.8 cm in diameter, on the soft palate (Figure 1C) and the left buccal mucosa (Figure 1D).

Complete blood count was within normal limits except for a raised Erythrocyte Sedimentation Rate (34 mm in the first hour). His chest radiograph (Figure 2) was clear with no obvious lesion, but

## OPEN ACCESS

### \*Correspondence:

Shaoyi Wang, Departments of Oral Surgery, Shanghai Ninth People's Hospital, College of Stomatology, Shanghai Jiao Tong University School of Medicine, National Clinical Research Center of Oral Disease, Shanghai Key Laboratory of Stomatology, Shanghai Research Institute of Stomatology, Shanghai, China,  
E-mail: wangshaoyi163@163.com

Received Date: 26 May 2020

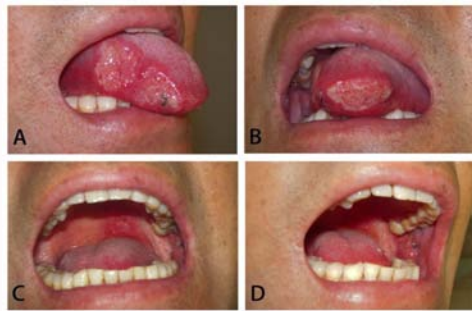Accepted Date: 02 Jul 2020

Published Date: 08 Jul 2020

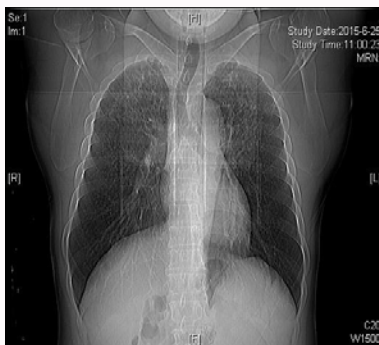### Citation:

Li MY, Zhang ZY, Yang C, Zhou ZT, Wang S. Primary Tuberculosis of the Oral Cavity Presenting as the Ulcers: A Case Report. *Clin Surg*. 2020; 5: 2856.

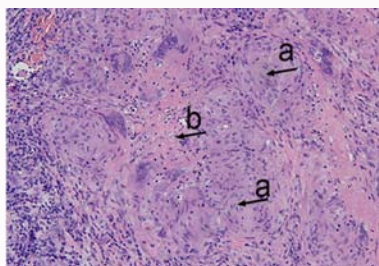
**Copyright** © 2020 Shaoyi Wang. This is an open access article distributed under the Creative Commons Attribution License, which permits unrestricted use, distribution, and reproduction in any medium, provided the original work is properly cited.



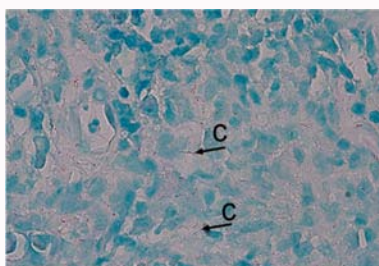
**Figure 1:** The tubercular ulcer on the tongue, soft palate and the left buccal mucosa.



**Figure 2:** Chest radiograph (PA) showing normal lung parenchyma, trachea and mediastinum, without any fibrocavitary lesion.



**Figure 3:** Histopathological examination of the ulcer showing typical findings of tubercular granulomas (arrows).



**Figure 4:** Ziehl-Neelsen stain showing acid-fast bacilli (arrows).

the tuberculin test was positive. Histological analysis of the excisional biopsy from the tongue showed lymphoplasmocytic infiltrate and multiple tuberculous granulomatous lesions (Figure 3). And acid fast bacilli were found in Ziehl-Neelsen stained sections (Figure 4). With a final diagnosis of primary oral tuberculoma, the patient was started on antitubercular therapy and follow-up showed good response.

## Discussion

The World Health Organization (WHO) estimates that one third of the world's population are infected with tuberculous bacilli and the incidence is growing at 1% a year [8,9]. The main reason may be the emergence of multidrug resistant strains of *M. tuberculosis*, which leads to the high mortality rates of the patients with HIV infection and AIDS [10]. Oral tuberculosis reported was approximately 0.1% to 5% of all TB infections; the incidence of actual oral tuberculosis may be slightly higher than those reports because of misdiagnosis or underreporting [11].

Most oral manifestations of tuberculosis involve lesions secondary to pulmonary tuberculosis, while the primary form of the disease is uncommon in the oral cavity [12]. In our case, no evidence of lung or other systemic involvement was found, supporting the diagnosis of primary oral tuberculosis. Primary tuberculosis is rare and presents as single painless ulcer with regional lymph node enlargement, while secondary lesions are common, usually present as single, indurated, irregular, painful ulcer [4]. Patients of secondary lesions often occurs in middle-aged and elderly patients, however, primary lesions are mainly seen in younger patients [13]. As for the site for oral TB lesions, it may occur at any location on the oral mucosa, but the tongue is most commonly affected [2,14]. The common manifestation of oral tuberculosis is an ulcerative lesion of the mucosa, but it may present in a variety of other forms such as nodules, tuberculoma and granulomas [15]. In this patient, it involved five ulcerative lesions at the tongue, soft palate and buccal mucosa. These lesions are characterized by progressive pain that profoundly interferes with proper nutrition and rest. Classically, tubercular ulcers of the tongue may involve the tip, lateral margins, dorsum, the midline, and base of the tongue.

Because of variable and non-specific clinical manifestation, the diagnosis of primary oral tuberculosis may be difficult. The following chronic ulcers should be distinguished, including syphilis, actinomycosis, histoplasmosis, traumatic lesions, pemphigoid, lichen planus, Crohn's disease and sarcoidosis [16]. Determining oral ulceration requires taking medical history, clinical examination and accessory investigations. Patients suspected of TB, chest radiograph is mandatory. Tuberculin skin test is helpful in the diagnosis, but its positive result does not always mean active TB, and it may also indicate previous infection or administration of BCG vaccine [17]. If the systemic signs and symptoms of tuberculosis were not observed, the diagnosis needed to be established only after a biopsy and histological examination.

In this patient, systemic examination did not reveal any abnormal findings. Chest X-ray together with laboratory tests including complete blood count, coagulation profile, urea and electrolytes, as well as renal and liver function test were reported to be within normal limits, but the tuberculin test was positive. Histological analysis of the excisional biopsy from the tongue showed lymphoplasmocytic infiltrate and multiple tuberculous granulomatous lesions. And several acid-fast *Bacilli* were identified with a Ziehl-Neelsen stain, situated within the granulomas, consistent with tuberculous granulomatous infection. Histological examination eventually confirmed the diagnosis. It is therefore important to be aware of possible occurrence of primary oral tuberculosis, being familiar with its clinical features and diagnostic means are available.

## Acknowledgement

This work was supported by the National Natural Science Foundation of China (81271114).

## References

1. Getahun M, Blumberg HM, Sinshaw W, Diriba G, Mollalign H, Tesfaye E, et al. Low prevalence of *Mycobacterium bovis* in tuberculosis patients, Ethiopia. *Emerg Infect Dis*. 2020;26(3):613-5.
2. Rout P, Modipalle V, Hedge SS, Patel N, Uppala S, Shetty PK. Prevalence of oral lesions in tuberculosis: A cross sectional study. *J Family Med Prim Care*. 2019;8(12):3821-5.
3. Lee ST, Jang SB, Kwon TG, Choi SY. Oral tuberculosis mimicking a traumatic denture ulcer. *J Prosthet Dent*. 2019;121(2):225-8.
4. Sharma S, Bajpai J, Pathak PK, Pradhan A, Singh P, Kant S. Oral tuberculosis - current concepts. *J Family Med Prim Care*. 2019;8(4):1308-12.
5. Teng CJ, Huon LK, Zheng YM, Yeh CM, Tsai CK, Liu JH, et al. Increased risk of tuberculosis in oral cancer patients in an endemic area: A nationwide population-based study. *Clin Oral Investig*. 2019;23(12):4223-31.
6. Clough S, Shaw A, Morgan C. Tuberculosis and oral healthcare provision. *Br Dent J*. 2018;224(12):931-6.
7. Arora KS, Garg S, Kaur P, Mohapatra S. Primary oral tuberculosis on the tongue mimicking squamous cell carcinoma. *Indian J Tuberc*. 2018;65(1):84-6.
8. Li L, Wang Y, Zhang R, Liu D, Li Y, Zhou Y, et al. Diagnostic value of polymerase chain reaction/acid-fast *bacilli* in conjunction with computed tomography-guided pleural biopsy in tuberculous pleurisy: A diagnostic accuracy study. *Medicine (Baltimore)*. 2019;98(29):e15992.
9. Krishna M, Gole SG. Comparison of conventional Ziehl-Neelsen method of acid fast *Bacilli* with modified bleach method in tuberculous lymphadenitis. *J Cytol*. 2017;34(4):188-92.
10. Wolday D, Kebede Y, Legesse D, Siraj DS, McBride JA, Kirsch MJ, et al. Role of CD4/CD8 ratio on the incidence of tuberculosis in HIV-infected patients on antiretroviral therapy followed up for more than a decade. *PLoS One*. 2020;15(5):e0233049.
11. Valenzuela-Narvaez R, Valenzuela DA, Valenzuela DR, Bailon A, Machco H, Mena C, et al. An unusual granular ulcer secondary oral tuberculosis of vestibule mandibular mucosa. *Eur J Dent*. 2020;14(2):331-4.
12. Pecho-Silva S, Navarro-Solsol AC. First case report in Latin America: Oral treatment of multidrug-resistant tuberculosis with delamanid and bedaquiline in combination with linezolid, moxifloxacin and clofazimine following a DRESS syndrome in a peruvian patient. *Pulmonology*. 2020;S2531-0437(20)30044-1.
13. Mesman AW, Calderon R, Soto M, Coit J, Aliaga J, Mendoza M, et al. Mycobacterium tuberculosis detection from oral swabs with Xpert MTB/RIF ULTRA: A pilot study. *BMC Res Notes*. 2019;12(1):349.
14. Battista G, Lo Russo L, Padovano Di Leva A, Rubini C, Sberna MT, Bollero R, et al. Oral tuberculosis: A tongue case report. *Minerva Stomatol*. 2013;62(4 Suppl 1):75-81.
15. Ju WT, Fu Y, Liu Y, Tan YR, Dong MJ, Wang LZ, et al. Clinical and pathologic analyses of tuberculosis in the oral cavity: Report of 11 cases. *Oral Surg Oral Med Oral Pathol Oral Radiol*. 2018;125(1):44-51.
16. Bhatia R, Mahajan R, Arava S, Singh S, Kandasamy D. A non-healing oral ulcer as a manifestation of systemic tuberculosis in an immunocompetent man. *Indian J Dermatol Venereol Leprol*. 2017;83(2):238-41.
17. Sabri A, Quistrebert J, Naji Amrani H, Abid A, Zegmout A, Abderrhamani Ghorfi I, et al. Prevalence and risk factors for latent tuberculosis infection among healthcare workers in Morocco. *PLoS One*. 2019;14(8):e0221081.