



# Primary Intracranial Intra Axial Ewing's Sarcoma: A Rare Case Report with Unusual Location & Short Review on Literature

Naresh Panwar\*, Somnath Sharma and Devendra K Purohit

Department of Neurosurgery, SMS Medical College, Jaipur, India

## Abstract

Ewing's Sarcoma (ES) is one of the frequently seen and catastrophic malignancies of childhood incriminate long bones and soft tissue. As far intracranial manifestations of the disease are concerned, which are extremely rare in reality, Most of the reported cases of ES involving Central Nervous System (CNS) represent secondary metastases from extra cranial sites. Although there are very few cases reported of primary Ewing's sarcoma of cranium. A search of the literature suggests that these tumors are mostly dural based or extra axial mimicking as meningeal tumors and most commonly seen in younger population. We present the clinical, radiologic and pathologic findings of an primary intracranial intra axial Ewing sarcoma/pPNET in a 42-year-old male located in left Parieto-occipital sub cortical zone, and radiologically presenting as Glioblastoma Multiforme (GBM). This site is highly unusual for intra axial ES, and to the best of authors knowledge this is third case of intra-axial intra parenchymal ES/pPNET.

**Keywords:** Ewing sarcoma/peripheral primitive neuroectodermal tumor; Primary intracranial intra-axial; Central nervous system

## Introduction

Ewing Sarcoma/peripheral Primitive Neuroectodermal Tumor (ES/pPNET) is aggressive, highly malignant, embryonal tumor of diaphysis of long bones, flat bones and soft tissues commonly occurred in pediatric age group [1]. These tumors composed of undifferentiated or poorly differentiated neuroepithelial cells and belong to a large family of small-blue-round-cell tumors. Intracranial primary ES/pPNET is extremely rare and cause is considered metastasis from extra cranial location. Most of the available literature is in the form of case reports. An intra-axial presentation of these tumors often misdiagnosed as central nervous system PNET (c-PNET) or as other primary intracranial neoplasm, clinically and radiologically. The diagnostic challenges, management issues should be address properly to broaden further insight regarding these tumors. As the tumor presents in young age, long-term survival remains a challenge in management of ES/pPNET patients. We report a case of intracranial intraparenchymal ES/pPNET presenting as heterogeneously enhancing high grade glioma in a 42-year-old male with complains of seizure and unconsciousness, an unusual radio pathological presentation.

## Case Presentation

A 42-year-old male presented with a single episode of generalized tonic-clonic seizure followed by unconsciousness one month prior to admission at our institution, Since then he developed mild to moderate intensity bifrontal headache and later on he had history of vomiting. On examination, patient was conscious, oriented comfortable and co-operative. His Glasgow coma score was E4 V5 M6 (15/15). Contrast-Enhanced Computed Tomography (CECT) showed an intra-axial relatively defined hyper dense mass lesion measuring about 7 cm × 4.8 cm × 8.8 cm in size in left parieto-occipital region, which showed heterogeneous contrast enhancement (Figure 1a-1d). Magnetic Resonance Imaging (MRI) brain was done with T1 & T2 Weighted sequence, Post Gadolinium contrast and Diffusion Weighted Imaging (DWI) on 1.5 Tesla MR Scanner. Which showed a well defined, solid cystic mass lesion in left parieto-occipital convexity with significant perifocal white matter edema. Post contrast images showed thick wall nodular peripheral enhancement and medial limit of tumor extending till ependymal ventricular margin. The patient underwent left parieto-occipital craniotomy and gross total removal with decompression of the lesion was achieved.

## OPEN ACCESS

### \*Correspondence:

Naresh Panwar, Department of Neurosurgery, SMS Medical College, Jaipur, Flat no.301, Shiv Sai Residency, Plot -727, Adarsh Nagar, Ashok Chowk, Rajasthan, India, Tel: 919660888640; E-mail: panwaralice2005@yahoo.com

Received Date: 01 Mar 2018

Accepted Date: 12 Mar 2018

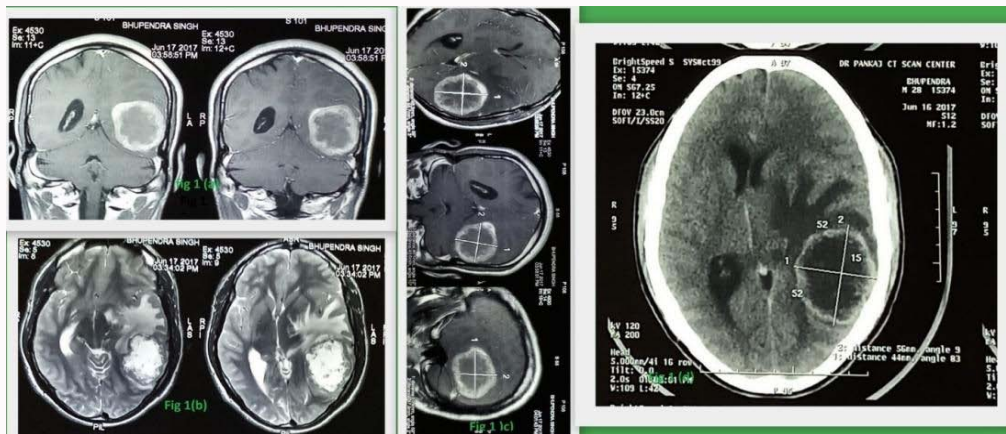
Published Date: 20 Mar 2018

### Citation:

Panwar N, Sharma S, Purohit DK. Primary Intracranial Intra Axial Ewing's Sarcoma: A Rare Case Report with Unusual Location & Short Review on Literature. *Clin Surg*. 2018; 3: 1946.

Copyright © 2018 Naresh Panwar.

This is an open access article distributed under the Creative Commons Attribution License, which permits unrestricted use, distribution, and reproduction in any medium, provided the original work is properly cited.



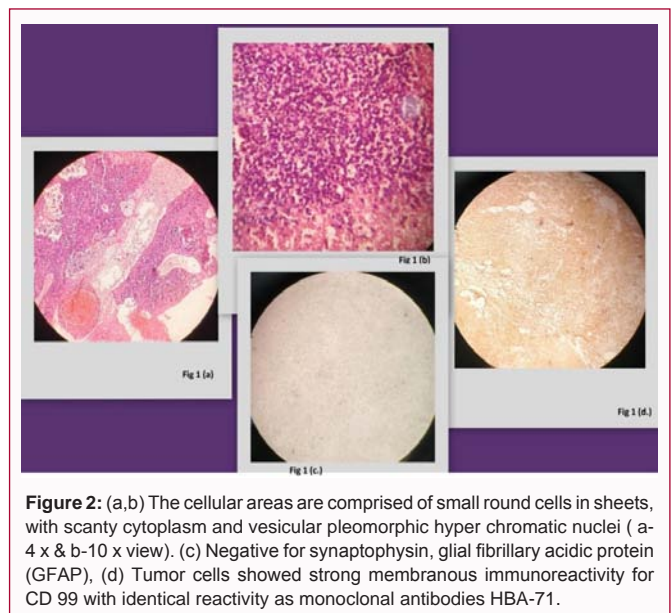
**Figure 1:** (a,c) Post Gadolinium contrast MR Scan showed a well defined, solid cystic mass lesion measuring about 5.8 cm x 4.8 cm x 1.6 cm in size in left parieto- occipital convexity with thick wall nodular peripheral enhancement, (b)-T2 weighted showed heterogenous hyperintense mass with midline shift, (d) Contrast-enhanced computed tomography (CECT) showed an intra-axial relatively defined hyperdense mass lesion left parieto- occipital region with perilesional edema).

Histopathologically neoplasm was predominantly revealing hyper cellular and hypo cellular areas. The cellular areas are comprised of small round cells in sheets, with scanty cytoplasm and vesicular pleomorphic hyper chromatic nuclei with occasional cells show prominent nucleoli. With a primary histological differential diagnosis of Round cell tumor, immunohistochemistry was done to further characterize the neoplasm. Tumor cells were negative for synaptophysin, Glial Fibrillary Acidic Protein (GFAP), cytokeratin, Leukocyte Common Antigen (LCA), Epithelial Membrane Antigen (EMA). Tumor cells showed strong membranous immunoreactivity for CD 99 antigen (using B Biocare Monoclonal Mouse Anti-Human MIC-2, clone 12E7 with identical reactivity as monoclonal antibodies HBA-71 and RFB-1) (Figure 2a-2d). The Ki-67 labeling index was 30% with a diagnosis of ES/pPNET Extensive workup was done including CECT scans of the thorax, abdomen, and pelvis, to search for extra cranial primary sites or metastatic deposits, which were all negative. Final diagnosis was primary ES/pPNET.

## Discussion

An American pathologist James Stephan Ewing (1866-1943) first described the tumor, establishing that the disease was highly aggressive, malignant and different from the known malignancies of first half of 20<sup>th</sup> century [2]. In 1920; he published his first work on a new kind of malignant osteoma, which later received his name. Since last approximately more than 100 years Ewing's sarcoma remains a challenging and lethal malignant pathology of pediatric age group and most frequently originates in the diaphysis long bones (47%), pelvis or ribs [3]. The involvement of skull is rare and hardly less than 4% of total cases, with the frontal and parietal bones being the most common location [4,5]. In past two decades, Ewing Sarcoma/peripheral Primitive Neuroectodermal Tumor (ES/pPNET) has gain popularity as a discrete disease entity that affects young adults, with indistinguishable sex propensity. When we reviewed the available literature on ES/pPNET affecting Central Nervous System (CNS), Which is extremely rare, these tumors are usually located either dural based supratentorially or involves the paravertebral regions of the spine [6]. Due to radiological and histological similarity, when these lesions arise in the intraparenchymal compartment leads to diagnostic challenge and commonly mimics as central -PNET (c-PNET) or other primary CNS tumors.

If we talk on occurrence of cranium ES, these two series provide



**Figure 2:** (a,b) The cellular areas are comprised of small round cells in sheets, with scanty cytoplasm and vesicular pleomorphic hyper chromatic nuclei ( a- 4 x & b-10 x view). (c) Negative for synaptophysin, glial fibrillary acidic protein (GFAP), (d) Tumor cells showed strong membranous immunoreactivity for CD 99 with identical reactivity as monoclonal antibodies HBA-71.

brief insight that "how less the entity actually"???. An epidemiological study of 2500 cases of brain tumor conducted by Paulus et al. [7] found only 9 cases of histopathological proven sarcoma, and ultimately one case turn out as ES. A recent retrospective epidemiological analysis 332 cases of ES during a span of 11 years conducted by Krishnamani et al. [8] at their institution detected only 7 cases of ES that primarily involved skull. Further knowledge on epidemiology of cranium ES is enhanced by Vandenhevel KA et al.[9]. They reviewed the available literature on the topic and described the detail of 26 cases reported so far, they found that out of 26 cases only two cases were of primary intra axial intraparenchymal ES/pPNET of the CNS that have been reported in the English literature [9]. To the best of our knowledge this is the third case report of primary intra axial intraparenchymal ES/pPNET of the CNS. Certainly, Jay et al. [10] was the first who describe a case of histopathologically proven medulloblastoma in posterior fossa but on further molecular workup demonstrated the t(11;22) (q24;q12) translocation, which ultimately turns out ES/pPNET.

Diagnosis requires a histopathological examination, immunohistochemistry, and cytogenetics. The histological

examination reveals that these tumors are composed of nearly uniform population of round to oval cells with scanty, basophilic cytoplasm, undifferentiated neuroectodermal cells with distinct immunohistochemical and/or electron microscopic features of glial or neuronal differentiation. Immunohistochemistry for CD 99 (MIC-2 gene product) shows strong membrane positivity in more than 97% of the patients of ES/pPNETs [11]. The chromosomal translocation t(11, 22) (q24;q12), detected by in situ hybridization technique is found in approximately 90% of these tumors.

Being a rare category of diseases, still there is no certain defined therapeutic protocol for management of patients with ES/pPNET affecting the CNS. However, available literature and studies conducting so far suggest that a multidisciplinary treatment approach is necessary. Although standard treatment guidelines for primary intraparenchymal ES/pPNETs is not available, so we deal our case as per treatment protocol for skull ES. Concisely speaking, a multidisciplinary approach, with a combination of different modalities of treatment, is preferred way of choice to treat this entity. ES/pPNET is also radiosensitive and the dose of 1.5 to 2 gy/days for 5 days/weeks is recommended followed by four drug CT regime. Due to the rarity of diseases, the prognosis of Es/pPNET is not clearly known.

## Conclusion

The case reported here raises necessity regarding further awareness of this entity ES/ pPNET, its rare presentation, diagnostic challenges and appropriate management protocol. We suggest that, ES/pPNET has to be kept in mind in the differential diagnosis of intracranial especially dural based tumors. This case also highlights that we cannot deny the presence of isolated primary intracranial intra-axial Ewing's sarcoma.

## References

1. Variend S. Small cell tumors in childhood: A review. *J Pathol.* 1985;145:25
2. Brand RA. Biographical Sketch: James Stephen Ewing, MD (1844–1943). *Clin Orthop Relat Res.* 2012;470(3):639-41.
3. Falk S, Alpert M. The clinical and Roengen aspects of Ewing's sarcoma. *Am J Med Sci.* 1965;250(5):492-508.
4. Bhansali SK, Desai PB. Ewing sarcoma observation on 107 cases. *J Bone Joint Surg.* 1963;45:541-53.
5. Steinbok P, Flodmark O, Norman MG, Chan KW, Flyer CJ. Primary Ewing's sarcoma of the base of the skull. *Neurosurgery.* 1986;19:104-7.
6. Dedeurwaerdere F, Giannini C, Sciot R, Rubin BP, Perilongo G, Borghi L, et al. Primary peripheral PNET/Ewing's sarcoma of the dura: A clinicopathologic entity distinct from central PNET. *Mod Pathol.* 2002;15(6):673-8.
7. Paulus W, Slowik F, Jellinger K. Primary intracranial sarcomas: Histopathological features of 19 cases. *Histopathology.* 1991;18(5):395-402.
8. Krishnamani K, Kumar TN, Gandhi LV, Raghunadharao D, Sadashivudu G, Megha U. Primary Ewing's sarcoma of the cranium: Case series and review of literature. *J Cancer Res Ther.* 2014;10(2):377-80.
9. VandenHeuvel KA, Al-Rohil RN, Stevenson ME, Qian J, Gross NL, McNall-Knapp R, et al. "Primary Intracranial Ewing's Sarcoma with Unusual Features." *Int J Clin Exp Pathol.* 2015;8(1):260-74.
10. Jay V, Zielenska M, Lorenzana A, Drake J. An unusual cerebellar primitive neuroectodermal tumor with t(11;22) translocation: pathological and molecular analysis. *Pediatr Pathol Lab Med.* 1996;16(1):119-28.
11. Sandberg AA, Bridge JA. Updates on cytogenetics and molecular genetics of bone and soft tissue tumors: Ewing sarcoma and peripheral primitive neuroectodermal tumors. *Cancer Genet Cytogenet.* 2000;123(1):1-26.