



Primary Extradural Osteolytic Meningioma: A Case Report

Sushil Kumar^{1*}, Aparajita Singh² and Amit Handa¹

¹Department of Neurosurgery, St. Stephen's Hospital, Tis Hazari, Delhi, India

²Department of Radiology, St. Stephen's Hospital, Tis Hazari, Delhi, India

Abstract

A 35-year-old lady presented with gradually progressive painless swelling in the left frontal region which was hard anteriorly and soft posteriorly. Computed tomography (CT) showed an osteolytic expansile lesion, enhancing uniformly on contrast magnetic resonance imaging (MRI). The lesion was excised with a wide margin of healthy bone and on histology it was confirmed to be a meningothelial meningioma.

Keywords: Extradural meningioma; Osteolytic; Subdural extension

Introduction

Meningiomas commonly arise from the arachnoid cap cells located in the external layer of the arachnoid membrane. The extracranial meningiomas are rare, comprising 1-2% of all meningiomas [1,2]. Meningiomas originating outside the dural compartment are variously called ectopic, extradural, calvarial, cutaneous extracranial, extraneuraxial or intraosseous meningiomas. Lang et al. [3] proposed the term "primary extradural meningiomas" for this type of lesion and the term defines the origin of this tumor as being separate from the dural covering of the brain. Meningiomas in such locations may be hyperostotic, osteolytic or mixed. The osteolytic variety is the rarest hence being reported.

Case Presentation

A 35-year-old lady presented with gradually progressive painless swelling in the left frontal region for the last 2 years. There was no history of trauma or fever. On examination there was a diffuse swelling with the anterior part being hard and the posterior part being soft. The swelling was non-tender and the overlying skin could be pinched off the swelling. The swelling was fixed, non-fluctuant without any cough impulse.

Computed tomography scan revealed a left sided frontal intradiploic mass expanding the calvaria with prominent bone destruction (Figure 1). The lesion extended through the skull defect both intra and extracranially. Magnetic resonance imaging revealed the mass to be hyperintense on T1 weighted images and isointense on T2 weighted images (Figure 2a and 2b). Gadolinium administration showed homogenous enhancement of the lesion (Figure 2c). MRI also revealed the small subdural extension of the lesion (Figure 2c).

The pre-operative diagnosis was intradiploic meningioma of the osteolytic variety. At surgery the tumor was solid, well defined, expanded both the inner and outer table of the skull, destroyed the dinner table at one place and perforated in to the subdural space through a thinned out but not infiltrated dura (Figure 3). After removal of the tumor along with a wide margin of healthy bone, cranioplasty was done using methylmethacrylate. Histopathology confirmed the diagnosis of meningothelial meningioma without any evidence of malignancy.

Discussion

Intradiploic meningiomas usually present as painless expansile masses without any neurological symptoms and signs. However symptoms if present are dependent on tumor location, size and involvement of the neighboring structures. Meningiomas presenting with scalp swelling and extracranial soft tissue mass are more aggressive in nature than their cranial counterparts [4]. However our case did not show any sign of malignancy on histologic examination. Intradiploic meningiomas are typically either osteoblastic or osteolytic or at times mixed types.

OPEN ACCESS

*Correspondence:

Sushil Kumar, Department of Neurosurgery, St. Stephen's Hospital, Tis Hazari, Delhi, India,
E-mail: sushilneuro@rediffmail.com

Received Date: 15 May 2017

Accepted Date: 07 Jul 2017

Published Date: 13 Jul 2017

Citation:

Kumar S, Singh A, Handa A. Primary Extradural Osteolytic Meningioma: A Case Report. *Clin Surg*. 2017; 2: 1560.

Copyright © 2017 Sushil Kumar. This is an open access article distributed under the Creative Commons Attribution License, which permits unrestricted use, distribution, and reproduction in any medium, provided the original work is properly cited.

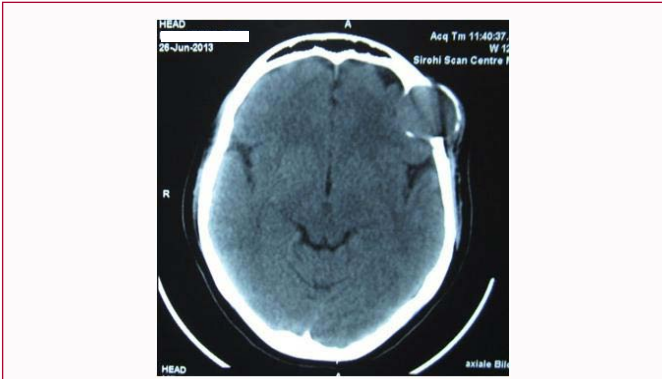


Figure 1: Computerized tomography scan axial view showing expansion and destruction of the left frontal bone.

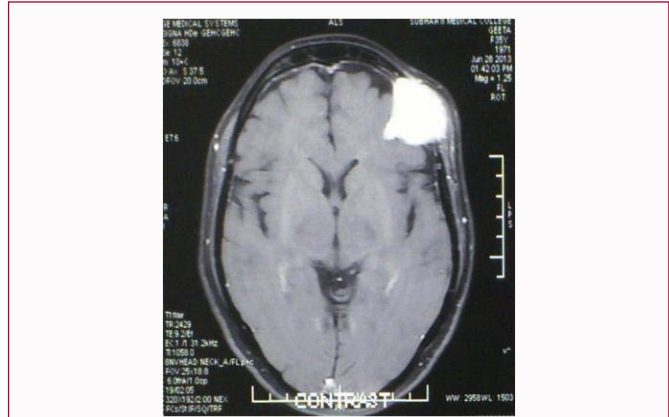


Figure 2c: MRI axial sections-Homogenously enhancing after contrast administration on T1 weighted image.

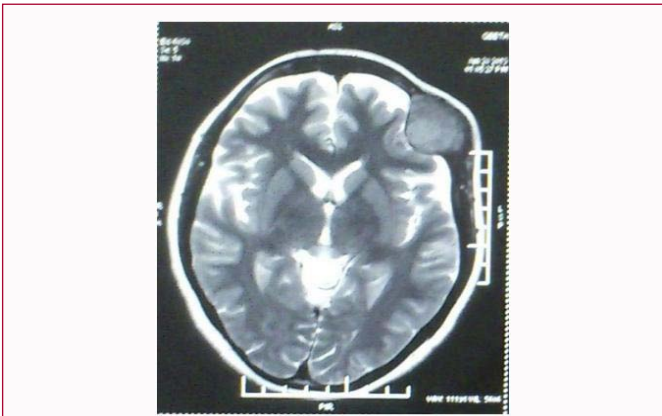

Figure 2a: MRI axial sections-T2 weighted image showing the lesion to be isointense.

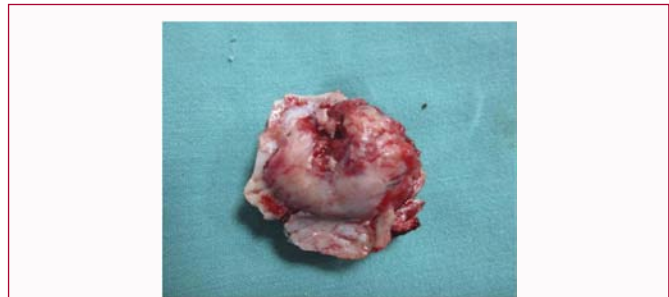

Figure 3: Photograph of excised specimen showing well delineated tumor on the inner aspect of the bone.

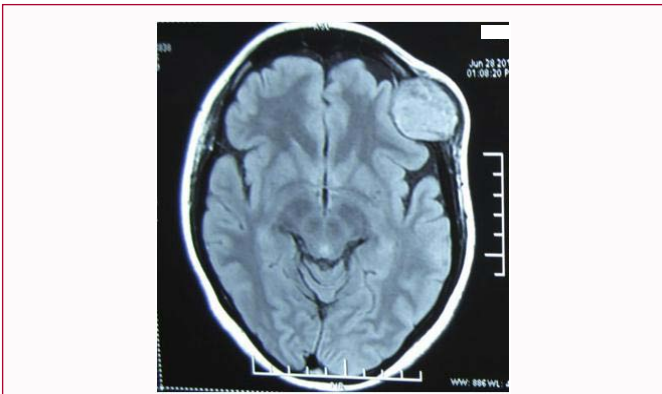


Figure 2b: MRI axial sections-Hyperintense on T2FLAIR image.

Osteolytic type appears as radiolucent on plain X-Rays. The osteolytic lesion may appear as hypodense on plain computed tomography with thinning, expansion and discontinuity of the inner and outer cortical layers. Tumor enhances on contrast administration [5]. All these features were typically seen in our patient. On magnetic resonance imaging (MRI), T1 weighted images show hypointense or isointense signal while T2 weighted images are usually hyperintense. Homogenous enhancement after gadolinium administration is typical and was observed in our case as well. The intradiploic osteolytic subtype is extremely rare and only 17 cases have been reported in the literature [6,7]. The only curative treatment is wide surgical resection accompanied by cranioplasty in the same sitting. If the resection is subtotal as is usual in the basal region, the tumor should be followed

up radiologically and irradiated if progression is there [8].

Lang classified intraosseous meningiomas as purely extracalvarial (Type I), purely calvarial (Type II) or calvarial with extracalvarial extension (Type III). The latter two are further divided as convexity(C) or skull base (B) forms. In our case as the epicenter of the tumor was in extracalvarial space, it was believed to have arisen away from the dura with later impingement, thinning and perforation of a small nubbin, through the dura into the subdural space. Only 8 cases with intradural component of this type have been reported in the literature [9,10]. Our case is of primary extradural type as the dura was displaced inwards from the dinner table of the skull, a finding thought to be consistent with an extradural growth. Som et al. [11] reported that direction of the bone displacement and subsequent bone remodeling caused by tumor growth is suitably accurate in ascertaining the presumed site of origin.

Many hypotheses have been formed to explain the origin of primary extradural meningiomas. Azar K et al. [12] postulated their origin from meningiocytes trapped in the cranial sutures during head molding at birth. Zulch et al. [13] postulated their origin to entrapment of arachnoid within the site of fractures. Lopez et al. [14] postulated arachnoid cells along the peripheral portion of the cranial nerves to be responsible for primary extradural meningioma in PNS, orbit and neck.

Shuangshoti et al. [15] proposed that primary extradural meningioma arise directly from multipotential mesenchymal cells or from metaplasia of mesenchymal cell types, e.g. fibroblasts and Schwann cells. By the foregoing postulations it seems primary extradural meningiomas have a multifactorial etiology.

References

1. Mazumdar DP, Vengsarkar US, Bhatjiwale MG, Goel A. Diffuse calvarial meningioma: a case report. *J Postgrad Med.* 2001;47(2):116-8.
2. Whicker JH, devine KD, McCarty CS. Giagnostic and therapeutic problems in extracranial meningiomas. *Am J Surg.* 1973;126(4):452-7.
3. Lang FF, MacDonald OK, Fuller GN, DeMonte F. Primary extradural meningioma: a report of nine cases and review of literature from the era of computerized tomography scanning. *J Neurosurg.* 2000;93(6):940-50.
4. Muthukumar N. Primary calvarial meningiomas. *Br J neurosurg.* 1997;11(5):388-92.
5. Agrawal V, Ludwig N, Agrawal A, Bulsars KR. Intraosseous intracranial meningioma. *AJNR Am J Neuroradiol.* 2007;28(2):314-5.
6. Rosahl SK, Mirzayan MJ, Samii M. Osteolytic intraosseous meningiomas: illustrated review. *Acta Neurochir (Wein).* 2004;146(11):1245-9.
7. Sheikhezai A, Meybodi AT, Hashemi M, Shafiee S. Primary intraosseous osteolytic meningioma of the skull: a case report. *Cases J.* 2009;2:7413.
8. Crawford TS, Kleinschmidt-DeMasters BK, Lillehei KO. Primary intraosseous meningioma. Case report. *J Neurosurg.* 1995;83(5):912-5.
9. Oka K, Hirakawa K, Yoshida S. Primary calvarial meningiomas. *Surg Neurol.* 1989;32(4):304-10.
10. Arana E, Menor F, Lloret RM. Intraosseous meningioma. *J Neurosurg.* 1996;85(2):362-3.
11. Som PM, Sachdev VP, Sacher MM. Intrafrontal sinus primary meningioma. *Neuroradiology.* 1991;33(3):251-2.
12. Azar-Kia B, Sarwar M, Marc JA. Intraosseous meningioma. *Neuroradiology.* 1974;6(5):246-53.
13. Zulch KJ. *Brain tumors: Their biology and pathology.* 3rd Ed. Berlin: Springer-Verlag. 1986:72-77.
14. Lopez DA, Silvers DN, Helwig EB. Cutaneous meningiomas-a clinicopathological study. *Cancer.* 1974;34(3):728-44.
15. Shuangshoti S, Netsky MG, Fitz-Hugh GS. Parapharyngeal meningioma with special reference to cell of origin. *Ann Otol Rhinol Laryngol.* 1971;80(3):464-73.