



Presurgical Assessment and Surgical Treatment in Extra Temporal Lobe Epilepsy: A National Comprehensive Epilepsy Surgery Program in Cuba

Lilia Maria Morales Chacón*, Judith González González, Nelson Quintanal Cordero, Martha Ríos, Manuel Dearriba Romanidy, Juan E. Bender del Busto, Aisel Santos Santos, Margarita M. Báez Martín, Sheila Berrillo Batista, Randis Garbey Fernández, Zenaida Hernández Díaz, Karla Batista García-Ramo, Bárbara Estupiñan Díaz, Lidice Galán García, Marilyn Zaldívar Bermúdez, Maite Solomon, Orestes López Piloto, Lourdes Lorigados Pedre, Liana Portela, Ricardo Valdés Yerena and Abel Sánchez Coroneux

International Center for Neurological Restoration, National Epilepsy Surgery Program, Cuba

Abstract

This paper presents an Electro clinical outcome of Extra Temporal Lobe Epilepsy (ExTLE) patients derived from a national comprehensive epilepsy surgery program in Cuba. Twenty-three patients with pharma co resistant Ext TLE underwent thorough pre surgical evaluations as well as resective and disconnective surgical procedures tailored by sequential intra operative ElectroCorticography (ECoG). Seizure outcome assessment for each patient was carried out one and two years after seizure. Logistic regression analysis was used to consider the potential predictive factors, which included demographic, presurgical and surgical variables. Resective surgical techniques were performed on frontal, occipital, pericentral and parietal lobes. Hemispherectomy was implemented in one patient for Rasmussen encephalitis. Anterior callosotomies for drop attacks were completed in two children; and focal frontal resection was carried out in one patient additionally to anterior callosotomy. About 80.9% of the surgeries were done in non-dominant hemispheres. Furthermore, surgical resection encroaching upon eloquent cortex was accomplished in 42.8% of the Ext TLE patients. During presurgical evaluation, the most common seizure types were aware and non-aware focal seizure which evolved to bilateral tonic clonic seizures. Regional interictal Electroencephalography pattern was documented in 61.5% of the patients; while 66.6% exhibited non-lateralized or bilateral interictal epileptiform discharge. Ictal EEG pattern was lateralized in 69.2% and regional in 76.9% of the cohort. Magnetic Resonance Imaging did not indicate a distinct lesion in 52.1% of the cases. After one-year follow up, 52.6% was labeled (Engel class I) and 47.3% (class II-III); at 24 months: 41.1% cases were registered class I, and 58.8% class II-IV. Clinical evolutions did not show significant modification concerning the assessed terms (Friedman ANOVA $p=0.15$); and there was no variation in the number of cases registered Engel class I two years after surgical treatment compared to the previous year ($p=0.47$ Sign test). A drop in the Absolute Spike Frequency (ASF) was observed in the post resective intra operative ECoG performed in all resective surgeries. The ASF during pre-resection ECoG was lower in patients Engels Class I one and two years after surgery ($*p<0.05$, Mann U test). A multivariate logistic regression analysis demonstrated that an acute postoperative seizure was the sole postoperative variable related to Engel classification. ($p=0.01$), odd ratio 3.88. This multi-disciplinary and multi-modal program for presurgical epilepsy workup and surgical procedures guided by sequential intra operative ECoG indicates favorable outcomes that show a safe and viable procedure with mild morbidity, and no mortality.

Keywords: Extratemporal lobe epilepsy; Epilepsy surgery; Seizure outcome; Intraoperative ElectroCorticography

Introduction

About one-third of epilepsy cases exhibit pharmaco-resistant seizures; and approximately 70% among those are identified with Temporal Lobe Epilepsy (TLE) while the residual 30% are characterized by extratemporal lobe epilepsy seizures [1,2]. Extratemporal Lobe Epilepsy (ExTLE) involves a range of seizures which can arise from the cerebral cortex outside of the temporal lobe; making up Frontal Lobe Epilepsy (FLE) the majority of those cases [3].

Nowadays, hitches in defining the epileptogenic zone, ascertaining the borders of the surgical

OPEN ACCESS

*Correspondence:

Lilia Maria Morales Chacón,
International Center for Neurological
Restoration, National Epilepsy Surgery
Program, 25th Ave, No 15805, Havana,
Cuba, Tel: +53-72-730-920;
E-mail: lily@neuro.ciren.cu

Received Date: 19 Jun 2019

Accepted Date: 02 Aug 2019

Published Date: 12 Aug 2019

Citation:

Morales Chacón LM, González JG, Cordero NQ, Ríos M, Romanidy MD, Bender del Busto JE, et al. Presurgical Assessment and Surgical Treatment in Extra Temporal Lobe Epilepsy: A National Comprehensive Epilepsy Surgery Program in Cuba. *Clin Surg*. 2019; 4: 2546.

Copyright © 2019 Lilia Maria Morales Chacón. This is an open access article distributed under the Creative Commons Attribution License, which permits unrestricted use, distribution, and reproduction in any medium, provided the original work is properly cited.

resection, and the connection of the epileptogenic zone to high functionality areas still make surgical management of extra temporal epilepsies demanding.

Current developments in noninvasive procedures such as epilepsy specific Magnetic Resonance Imaging (MRI) protocols comprising post processing analysis, Single Photon Emission Computed Tomography (SPECT) and Positron Emission Tomography (PET) have enhanced the ExtTLE diagnostic tools, enabling surgical behavior [4-6]. Likewise, intra operative Electrocorticography (ECoG) might also provide useful information in relation with the interictal activity varying the planned resection extension [7].

Nonetheless, outcomes of surgical treatment in TLE are more satisfactory than in ExTLE. In addition, existing technology is not usually available in developing countries where 80% of epilepsy patients do not have comprehensive epilepsy surgery programs, especially, to treat pharmacoresistant ExTLE epilepsy [8]. That is why, hard work is done to categorize foretelling features that help describe potential candidates for resective surgery [9-12]. Considering the needs previously stated, we set up the first comprehensive epilepsy surgery center in Cuba [13]. This paper summarizes presurgical assessment and surgical treatment in extratemporal lobe epilepsy patients, and communicates the establishment of a national comprehensive Epilepsy Surgery Program in Cuba. The study examines a cohort of patients who underwent surgery for pharmacoresistance extratemporal treatment, and identifies pre and surgical predictors of postoperative seizure recurrence.

Materials and Methods

Patient population

Subjects submitted to ExtTLE epilepsy surgery with over one-year follow-up after operation was included in this communication whereas those with prior brain surgical procedure were left out. Additionally, cases were required to be non-responsive to at least two Antiepileptic Drugs (AEDs) trials as a result of inefficacy and intolerance; thus, recurrently compromised by seizures. Individuals with pharmacoresistant epilepsy were referred from all the country [14]. Family and patient's approval was received in all cases.

Presurgical examination

The presurgical examination plan included: (a) prolonged Video-Electroencephalography (V EEG) monitoring with scalp electrodes placed according to the international 10 to 20 system and additional electrodes considering the epileptogenic zone presumed; (b) Magnetic Resonance Imaging (MRI) scans with a 1.5T or 3T scanner (Siemens Magnetom Symphony) (c) A comprehensive battery of neuropsychological tests (executive functions, attention assessment and memory, higher verbal and visual functions), (d) multimodal evoked potentials, somatosensory, visual and auditive [15-17]. In patients with non-visible lesion in MRI interictal and ictal brain perfusion Single Photon Emission Computed Tomography (SPECT) using ^{99m}Tc-Ethylene-Cysteine Dimer (ECD) were carried out. During the administration of the radiopharmaceutical, the patient remained monitored by EEG. The SISCOM methodology was also implemented in this cases Figure 1A. Besides, MRI post processing comprising voxel based morphometric and volumetric analysis with functional neuroimaging using Magnetic Resonance Spectroscopy (MRS) were also implemented in these patients in accordance with our previously published protocol [16].

Presurgical video-EEG monitoring: Patients underwent Video-EEG monitoring for 6.6 ± 2.74 -day range (1 to 11 days). The distribution of Interictal Epileptiform Discharges (IEDs) during prolonged video-EEG monitoring was assessed by (LM) analyzing fifteen- minute-interictal EEG samples every one hour. The data recorded in relation to events was identified by button presses, seizure or spike detection programs.

Interictal epileptic form activity and ictal onset pattern were categorized as regional involving one lobe, and ipsilateral contiguous or non-regional [1,2]. Ictal and interictal Video-EEG were analyzed by a well-qualified epileptologist (LM).

Presurgical magnetic resonance imaging: Presurgical 1.5 (n=9) or 3T (n=14) MRI scans of the patients integrating T1-weighted images with and without gadolinium-DTPA, T2-weighted images, fluid-attenuated inversion recovery images and magnetization-prepared rapid gradient echo sequences were also reviewed by a knowledgeable neuroradiologist (ZH). MRI findings were classified as (1) MR visible/MR non-visible; (2) according etiology, tumor, cortical development malformation, vascular and others; and (3) (eloquent cortex/non-eloquent) adjacent to or overlapping with eloquent areas (the primary motor cortex or Broca's area, sensorial, language) based on anatomic landmarks; (4) laterality (dominant hemisphere/non-dominant). Since 2016, we have discussed patient test results monthly, not only with a multidisciplinary team at epilepsy surgery conferences held at our Center, but also with specialists of the national epilepsy surgery program.

Surgical procedures and histopathology

Surgical procedures encompassed local resection, functional hemispherectomy, multiple subpial transection, and corpus callosotomy. Lobectomy was the prime practice when all or most parts of the lobe were involved in the epileptogenic zone. In addition, lengthy lesionectomy was performed in patients with local seizure onset and MRI visible lesion. The extension of the resection was tailored by sequential pre and post resection ECoG. Eloquent cortical areas were labeled according to Changes taxonomy; and comprised the rolandic cortex (pre- and postcentral gyrus), the Supplementary Motor Area (SMA), insula, primary visual cortex as well as Broca and Wernicke's areas [18].

ECoG data acquisition was performed with a Medicid-5 digital Electroencephalographic system (Neuronic SA, Cuba) using AD-TECH subdural electrodes (grid and strips). In the pre and post resection ECoG Absolute Spike Frequency (ASF) were calculated, and variation percentage of the ASF was also estimated. The extension of resection in lesional and non lesional cases was adjusted according to presurgical evaluation and intra operative sequential ECoG. Subtotal resection was intentionally performed when the lesion overlapped with eloquent cortex. The accurate detection of lesion localization relative to eloquent cortex was derived from intraoperative ECoG using cortical mapping with somatosensory evoked potentials and electrical stimulation Figure 1B.

Histopathological analysis: In this study, epilepsy substrates were determined by histopathology, and resected specimens varied in size depending on the presurgical evaluation and intra operative ECoG results. Haematoxylin-eosin and Kluver-Barrera myelin special stain were performed in specimens. Histopathological findings comprised four chief groups: cortical development malformations, neoplasms, vascular lesions, and other nonspecific histopathological

Table 1: Demographic and presurgical assessment of the overall cohort of extratemporal epilepsy patients.

Mean age at surgery (years ± SD range)	24,1±10,1 (range5-47)
Mean age at seizure onset (years ± SD range)	7.5 ± 5,18 (range 1-20)
Gender	Male: 18/23 (55%) Female: 5/23 (45%)
Mean epilepsy duration (year ± SD range)	17.1 ±10.5 (range 2-42)
	< 5 years 3/23 (13 %)
	> 5 years 20/23 (86.9 %)
Risk factors, n (%)	77.5%, (47.6% perinatal insult)
Mean number of antiepileptic drugs ± SD (range)	2,9 ± 0.6, (range 2–4)
Seizure frequency n (%)	< 20/ months 21% > 20/months 84.2%
Generalized tonic clonic seizure occurrence, n (%)	Yes 56.5% No 43.4%
Seizure types	Aware and non-aware focal seizure evolved to bilateral tonic clonic seizure 5/23 (21.7%) Non aware focal seizure evolved to bilateral tonic clonic seizure 6/23 (26%) Aware and non-aware focal seizure 7/23 - 30.4% Non aware focal seizure 2/23 (8 %) motor and non motor generalized seizure in 2/23 (8 %) Non aware focal seizure and motor and non-motor generalized seizure 1/23
Interictal EEG topography, n (%)	Regional (61.5. %) Non-regional (38.4 %)
Interictal EEG lateralization EEG, n (%)	Lateralized (33.3 %) Non-lateralized (66.6 %)
Ictal EEG topography, n (%)	Regional (76.9 %) Non-regional (23%)
Ictal EEG lateralization, n (%)	Lateralized (69.2 %) Non lateralized (30.7 %)
MRI lesion, n (%)	MRI visible (47.8%) MRI non-visible (52.1%)
SPECT interictal e ictal with EEG co registration, n (%)	Yes (42.1%) No (57.8%)

abnormalities. For microscopic diagnosis and Focal Cortical Dysplasia classification, the system proposed by the International League Against epilepsy was used [19]. For Central Nervous System tumor histopathological diagnosis purpose, the World Health Organization (WHO) classification was employed [20]. Unspecific histopathological abnormalities included gliosis, scars, among others.

Neoplasms were classified as glial tumors (astrocytomas, oligoastrocytomas, and oligodendrogliomas) and neuroepithelial tumors (gangliogliomas and Dysembryoplastic Neuroepithelial Tumors [DNTs]).

Seizure outcomes

Patients were routinely evaluated twelve, and twenty-four months after surgery. Some cases were gauged at appropriate intervals of seizure recurrence. Seizure outcome assessment was based on Engel's scale [Engel class I, free of disabling seizures; class IA, seizure-free; class II, rare seizures (fewer than three seizures per year); class III, worthwhile improvement (reduction in seizures of 80% or more); class IV, no benefit] [21]. To exemplify, class I was categorized as "satisfactory" outcome, while classes II, III and IV as "non-satisfactory" seizure relief outcome.

In patients with acute postsurgical seizures, the recurrence period was determined by the time of the first seizure after one postsurgical week. For the interests of this study, acute postsurgical seizures were defined as those occurring within the first postoperative week (<7 days).

Statistics study

Data were collected from follow-up visits, and sequentially entered into the database. Indicators were summarized with descriptive statistics for each variable comprising means, medians, and standard deviations for continuous variables and frequencies for categorical variables. Normality of the data was tested using Shapiro-Wilk test. Results showed non-normal distribution of some variables for comparisons, non-parametric inference was used. Mann Whitney test was employed to compare differences between two independent populations. Additionally, the Friedman ANOVA and sign test were utilized to assess the electroclinical follow-up one and two years following surgery. A significance level of 0.05 was used. Multivariable analyses were performed by logistic regression to examine the potential predictive and prognostic factors, including demographic, presurgical and surgical analyzed variables.

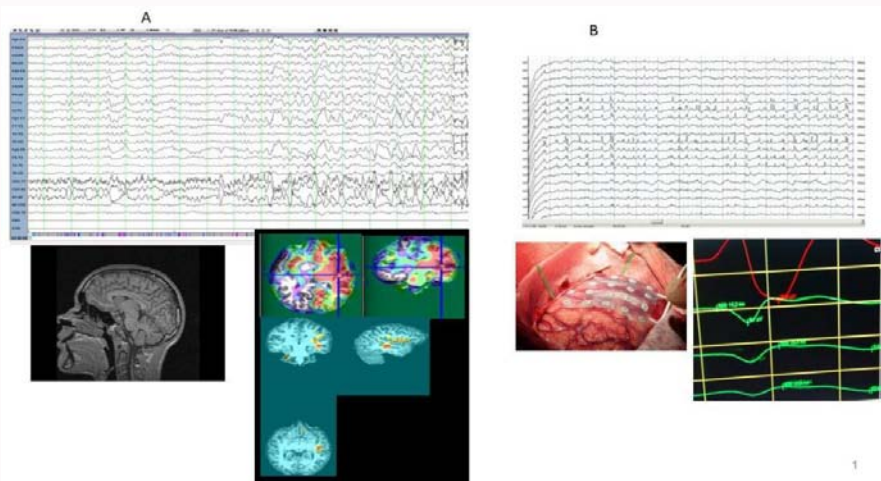


Figure 1: A. Presurgical evaluation in non-lesional extra-temporal epilepsy. Magnetic resonance imaging T1- and T2-weighted sequences were normal. Extracranial EEG shows rhythmic activity at seizure onset in channels containing the frontocentral leads. SISCOM study performed in the patient allowed the detection of focal hyperperfusion in the right sensory motor area during ictal SPECT. B. Intraoperative Electrocoorticography reveals repetitive spike pattern. This activity was recorded in the pericentral region. Somatosensory evoked potential was recorded to delineate eloquent cortex and it showed phase reversal in the contact over rolandic area. This patient was submitted to a focal resection and histopathological examination reported focal cortical dysplasia type I according ILAE classification.

Ethical considerations

The current study was accepted by the scientific and ethics committee of the International Center for Neurological Restoration (CIREN37/2012), and all the actions accomplished followed the guidelines of the Declaration of Helsinki for human research from 1975.

Results

The Comprehensive Epilepsy Surgery Program aimed at carrying out epilepsy surgeries at significantly concessional rates began at CIREN Havana, Cuba in 2001. In 2010, sporadic extratemporal lesional epilepsy surgeries were practiced. Four years later, a regular surgery program to extratemporal epilepsy was established. In May 2016, we set up a comprehensive national epilepsy surgery program in pediatric and adult epilepsy patients incorporating the National Neurosurgery and Neurological Institute as well as the pediatric hospital “Juan Manuel Marquez”, in order to optimize human and technological resources, extent the comprehensive epilepsy surgery program to other centers, and to perform epilepsy surgery in non-lesional and/or epileptogenic zone adjacent to or overlapping eloquent cortex cases.

Demographic profile and presurgical assessment

Most patients (86.9 %) had more than five years of seizure duration. Mean age at seizure onset was 7.2 ± 5.2 (range 1 year to 20 year.), and presurgical seizure frequency was 20/months or more in 84.2%. All patients had been taking 2 to 4 antiepileptic drugs being Lamotrigine 47.3%, Carbamazepine 36.8%, Clonazepam 31.5%, Valproic Acid 21%, Clobazam 31.5%, Levetiracetan 26.3% the most frequent Antiepileptic Drugs (AEDs). About 47% were taking three or more AED at surgery time Table 1.

Pre-surgical assessment: During extracranial Video-EEG monitoring a mean of 24.6 ± 23.6 seizures per patient was recorded with a mean Video-EEG monitoring efficiency equal 0.72. In the whole group the first seizure occurred from day 1; and the third on day 4. Data about awake and sleep seizures per day were 1.88 and 0.37 respectively. Regional interictal EEG pattern was documented

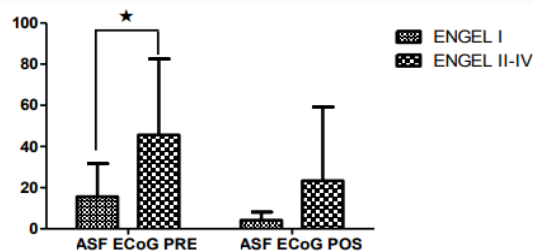


Figure 2: Bar graph shows values of absolute spike frequency on the pre and postresection intraoperative Electrocoorticography (mean and standard deviation SD) in extratemporal lobe patients with satisfactory (Engel class I) and unsatisfactory (Engel class II-IV) outcome. The absolute spike frequency during pre-resection Electrocoorticography was lower in patients in Engels Class I ($p < 0.05$, Mann Whitney U test).

in 61.5% of the cases while 66.6% had non-lateralized or bilateral Interictal Epileptiform Discharges (IED) (Table 1). In contrast, ictal EEG pattern was lateralized in 69.2% and regional in 76.9% of the 10 subjects. Most patients exhibited aware and non-aware focal seizures which evolved to bilateral tonic clonic seizures. MRI did not illustrate a distinct lesion in 52.1% of the cases. On the other hand, patients submitted to 3T MRI did not indicate more positive findings compared to patients who underwent 1.5T MRI. Besides, lesional cases on MRI showed a lesion limited to the frontal lobe (44.4%) and extra frontal lesion (55.5%).

Surgical procedures

Table 2 shows an overview on surgical variables. Resective processes were located as follows: frontal (n=12), occipital (n=4), pericentral (n=3) and parietal (n=1). About 77.7% of the surgeries were performed in non-dominant hemispheres whereas 47% of the ExtLE patients underwent surgical resection encroaching upon eloquent cortex. The resection amount in patients was based on a result combination obtained from presurgical evaluation and intraoperative ECoG findings. Multiple subpial transections were done additionally to resection in eloquent areas in five patients (two in primary motor and three in pericentral cortex). Hemispherectomy was implemented in a patient due to Rasmussen encephalitis. Anterior

Table 2: Surgical histopathological and electrocorticographic characteristics of the overall cohort of extratemporal epilepsy patients.

Surgery Type	Frontal resection 12
	. Primary motor area 2
	. Supplementary Motor Area (SMA) 2
	. Dorsolateral 6
	. Orbitofrontal 2
	Pericentral resection 3
	Parietal resection 1
	Occipital resection 4
	Corpus Callosotomies 2
	Functional Hemispherectomy 1 (Multiple subpial transection was done additionally to a resection in 5 cases associate with a focal resection)
	1 callosotomy was done in addition to a frontal resection)
Laterality, n (%)	dominant hemisphere 19%
	Non-dominant 80.9%
adjacent to or overlapping with eloquent areas	eloquent cortex 42.8%
	non-eloquent) 57.1%
ECoG pattern Specific patterns of interictal spikes	Yes 83.3%
	No 20%
Presection ECoG Interictal epileptiform discharges Absolute Discharges Frequency (ADF)	51.45± 112.5/min (range 1.89 -464.15)
Postresection ECoG Interictal epileptiform discharges Absolute Discharges Frequency (ADF)	7.64 ± 8,56/min (range 1.05-32.9)
ECoG variation percentage of the Interictal epileptiform discharges Absolute Discharges Frequency (ADF)	80.06 ± 13.5 % (range62.9-100)
Histopathology, n (%)	Cortical development malformations (61.1 %)
	Tumor (16.6 %)
	Cavernoma (5 %)
	Microangiomas 5%
	Not specific (16.6 %)
	Rasmussen encephalitis associated to FCD 1 patient
APOS, n (%)	Yes 56.25 %
	No 43.75%

ECoG: Electrocorticography; APOS: Acute postoperative seizures; SD: Standard deviation

callosotomies for drop attacks were performed in two children; in one case both focal frontal resection and anterior callosotomy were carried out.

Intraoperative electrocorticography: findings and surgical outcome: Pre resection and sequential post resection ECoG was performed in all patients. The numbers of sequential ECoGs were between 2 to 4 records and the mean duration of the records was 16.78 ± 8.25 min. Bispectral index monitoring in between 38 to 70 was used to monitor depth of anesthesia. Repetitive interictal spikes and other specific patterns of interictal spikes were seen in 83.3% of the cases, and absolute spike frequency decreased significantly in the last post-resection ECoG, $p=0.001$ (Wilcoxon Matched pairs test).

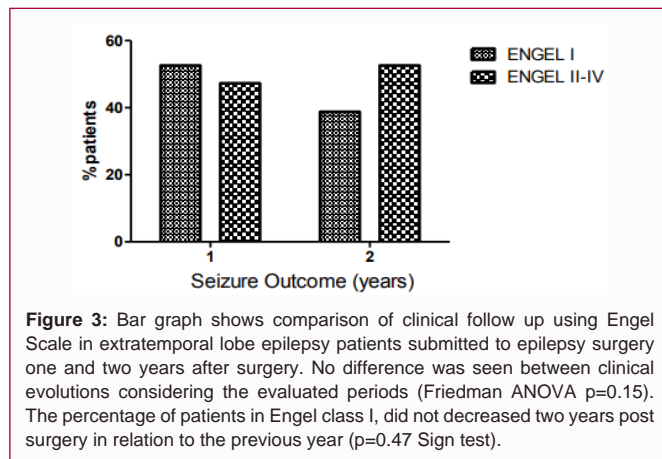
The ASF during pre ECoG was lower in patients in Engels Class I one and two years after surgery ($*p<0.05$, Mann U test) as shown in Figure 2A specific pattern of interictal spikes was recorded in 83.3% of the cases, being also lower in patients with satisfactory postsurgical outcome.

Histopathological findings: As shown in Table 2, malformations of cortical development accounted for 61.1% of all histopathological

findings followed by neoplasms and cavernomas. About 16.6% revealed nonspecific histopathological findings, and one case had microangiomas. Cortical development malformations were the most common histopathological findings in our series. There was similar proportion of patients with FCD type I, and Type II (40% vs. 60%) [$p=0.30$ difference between two proportions], one patient had polymicrogyria, while other presented heterotopy associated with FCD. In addition, neoplasms observed were glial tumors (astrocytomas, and neuroepithelial tumors (gangliogliomas and Dysembryoplastic Neuroepithelial Tumors [DNTs]).

Seizure outcome

After one-year follow up, 52.6% was categorized (Engel class I) and 47.3% (class II-III); at 24 months, 41.1% of the cases was registered class I, and 58.8% was listed class II-IV. There was no difference between clinical evolutions considering the evaluated periods (Friedman ANOVA, $p=0.15$). The percentage of patients regarded as Engel class I did not diminish a couple of years after operation in relation to the preceding year ($p=0.47$ Sign test) Figure 3. APOS was seen in 56.2% of the cases, and patients kept their AEDs for at least 2 years post-surgery.



Logistic regression analysis demonstrated that the APOS was the only postoperative factor associated with Engel classification outcome. ($p=0.01$), odd ratio 3.88. Moreover, occurrence of bilateral tonic clonic seizures and lesional MRI showed a tendency to predict seizure outcome in this cohort.

Operative complications: As to surgical complications, there was no mortality in our cohort. However, postoperative neurological deficits like paresis were perceived in three patients whereas other three cases showed surgical complications such as deep vein thrombosis, wound infection, and visual dysfunction, respectively. Most of these conditions were resolved during the postoperative course. Permanent neurological morbidity was observed in only three patients (13%), described as paresis and sightlessness. On the other hand, one patient Engel Class I, died from cardiovascular disease fifteen months after surgery.

Discussion

Results demonstrate that surgery in patients with extra-temporal epilepsy is related to promising seizure outcome and minimum complication outline. The success of this comprehensive national epilepsy surgery program in pediatric and adult epilepsy patients strongly suggests the possibility of developing a committed comprehensive epilepsy surgery program with a national collaborative approach in a Latin American region. One year after surgery, 52.6 % of the patients was cataloged Engel I class. This result is in line with Tellez-Zenteno et al report; and to some extent improved in relation to other series [9,11,22,23]. The surgical outcome in our cohort is also consistent with a large case surgery series for extratemporal lobe epilepsies reported, in which 49% of the patients were Engel Ia at an average of 54 months postoperatively [2]. In Delev D's report, Engel I outcome after frontal and parietal resections was 65% and 71%, respectively, while other studies informed Engel I outcome ranging from 45.1% to 57.5% [24-26].

A variety of information for seizure outcome after extratemporal resections is particularly noticeable in the available works. Some authors have reported moderately steady Engel I rate over years in nearly 50% adults and children [9,27,28]. Controversially, McIntosh et al. [29] stated initial seizure freedom in 40.7% of the cases, falling to 14.7% five years after operation [29]. Furthermore, a retrospective study that involved children with FCD and benign tumors submitted to frontal lobe resection described that at last follow-up, 63% patients stayed seizure-free; however, 37% had discontinuance in antiepileptic drugs [30]. Other series from Latin America and other developing

countries involved in temporal and extratemporal epilepsy surgery such as Argentina comprising lobectomies, lesionectomies, callosotomies, multiple subpial transection, vagus nerve stimulations and hemispherectomies revealed Engel class I outcome in 68.21% at 12 months' follow-up [31]. Mikati MA also stated 70% Engel class I, 9% class II, 14% class III, and 7% class IV after resective surgery in 93 adults and children who had undergone epilepsy surgery including extratemporal (22%), and temporal resections in 54% and multilobar resections (13%), hemispherectomy (4%), vagal nerve stimulation (6%), and corpus callosotomy (1%) of the cases at the American University of Beirut [32]. On the other hand, Jayalakshmi S, reported Engel's favorable outcome in temporal and extra-temporal resection in adolescents and children respectively, in 59 (75.6%) of the cases [33]. In addition, Vermeulen L informed good seizure outcome for at least one year at the last visit in 62% for extra-temporal lobe interventions [34]. Recently, satisfactory outcomes were observed in 92.5% of the pediatric patients submitted to corpus callosotomies and resective procedures [35].

Most procedures carried out for extratemporal epilepsies are frontal resections, which were performed in 52.1% of our cohort; followed by occipital, pericentral and parietal resection as well as palliative and disconnection procedures [36]. Equivalent findings were reported in Delev D's series, with 48% of frontal lobe operations, whereas parietal, occipital, and insular resections accounted for 24% of the procedures [2]. They also reported that the most positive epileptological outcomes were attained in individuals with frontal and parietal resections (Engel I 65.0% and 71.4%, respectively), as insular resections revealed less auspicious results (Engel I 52.2%).

We executed corticectomy of Supplementary Motor Area (SMA) guided by sequential ECoG in two patients classified as Engel Scale II one year after surgery. Recently, Alonso-Vanegas MA described that 61% of the patients who underwent lesionectomy and/or corticectomy of the SMA guided by ECoG were Engel Class I. Concerning functional hemispherectomy; reports have specified 66% in a group of patients with grade I control according to Engel's classification, in average follow ups of 48 months [8]. Observably, such comparisons are restricted by both referral patterns and selection criteria, which are expected to vary from different centers in Latin American nations. So as to homogenize these criteria, cases were analyzed in an epilepsy surgery conference including a multidisciplinary team with specialists of the national epilepsy surgery program.

It can be noticed that a pathology-based approach to epilepsy surgery is essential as it might improve not only the explanation of the outcomes but also the understanding of the failure causes. Noticeably, cortical development malformations, specifically FCD were the most common histopathological finding in our series, with similar proportion between FCD Type I and Type II. Moreover, FCD has been considered as a foremost reason of pharmacoresistant extra temporal resections, especially in children and adolescents [37-39], while the rate of seizure free once resection improved from 52% to 68.9% [40-42].

As described in other studies, we found a quite high prevalence of FCD among operated cases with normal MRI [43-45]. In this framework, some authors have pointed out that even the unseen primary pathology, specifically FCD, can represent a favorable prognostic indicator in case of complete removal of the EZ when compared with all other etiologies [46-48].

In one recent extra temporal series, FCD accounted for 46.5% of all histopathological findings followed by tumors, gliosis, and cavernomas [2]. Similarly, in our study, astrocytomas, gangliogliomas and DNTs were the tumors found in patients; being the latter of the group of long-term epilepsy associated tumors. With respect to histopathology, most favorable seizure outcomes have been described in patients with cavernomas and glioneuronal tumors (gangliogliomas and DNTs) with 89% and 85% seizure-free (Engel I) patients, respectively. Consistent with previous reports, 2/3 (66.6 %) our patients with tumor conditions remain seizure-free.

Even with this histopathological profile, our seizure freedom outcome (Engel class I) was equivalent to other series in developed and developing countries. This points to epilepsy surgery as an effective treatment for carefully selected patients with pharmacoresistant extra temporal lobe epilepsy.

Apart from the ambiguity concerning the choice of the most prospective candidates, surgical treatment of extratemporal epilepsies stays with difficulties in localizing and defining the extension of the epileptogenic zone. Thus, we also implemented a sequential pre and postresection ECoG in order to define the extension of the epileptogenic zone in addition to developing a presurgical evaluation based on multimodal data acquisition derived from ictal and interictal SPECT coregistered with EEG, SISCOM and quantitative neuroimaging in case with non-visible lesion in MRI [16;49].

The present work highlights our practice with ECoG and its usefulness in epilepsy surgery [50]. A significant modification was observed between pre and post resection Absolute Spike Frequency (ASF) which was lower in patients classified Engles class I. It is recognized that the attainment of epilepsy surgery is governed by precise localization and entire resection of the epileptogenic tissue, which are both assisted by intra operative ECoG. The presence of persistent spikes on post-resection ECoG has been a noteworthy numerical relation to poor seizure freedom post-surgery [51]. This author concluded that the intra operative ECoG is a valuable adjunctive test in epilepsy surgery to accomplish ideal seizure freedom in cases of mesial temporal sclerosis plus, focal cortical dysplasia and tumors.

In contrast, there is extensive difference in clinical practice about the role of electrocorticography closely after resection (post-resection ECoG) in pediatric epilepsy surgery. It has been stated that results can guide further resection of potentially epileptogenic tissue. On the other hand, there is a hypothesis that post-resection ECoG spiking represents a biomarker of the epileptogenic zone, and predicts seizure outcome in children undergoing epilepsy surgery. In Geiner HM's report, the best outcomes were obtained with resection of both the seizure-onset zone and ECoG abnormalities [7].

As a whole, in terms of complications the rate is higher in extra temporal location compared to temporal resections with a reported perioperative mortality of 1.2% in extra temporal resections [52]. Appreciably, stable morbidity of extra temporal procedures fluctuates between 3% and 43% in different series [53-55]. In our study, there was no mortality. Besides, long-lasting complications were only observed in three of the cases, and surgical resections involved eloquent areas in 42.8% (almost a half of the cases); hence, the complication number appears to be reasonable.

Equally to Delev D's series, we had no perioperative death; and permanent morbidity associated with surgical and neurological

complications reached 13% [2]. This figure is parallel to others reporting a stable morbidity between 10% and 15% [2,27,28,56].

Thorough lesion resection, short term epilepsy, younger age at surgical procedure, and circumscribed histopathological results are among the most predictive variables related to seizure outcome post ExTLE operation [27,57,58]. Moreover, remoteness from the epileptogenic zone to eloquent cortex was linked to a more auspicious outcome (Engel I), despite no meaningful effect on seizure outcome of the resection localization [12].

It was observed that acute postoperative seizures were an independent predictor of clinical outcome in our extra temporal patients, being FDC the most common pathological substrate. This result overlaps with Jin B et al. [59], who reported that incomplete resection of FCD, presence of IEDs on 3 months to 6 months postoperative EEG, and presence of habitual APOS are powerful predictive factors for seizure recurrence after surgery [59]. On the other hand, in a large cohort of the spectrum of malformations of cortical development including FCD, 66.67% of the patients were seizure-free and aura-free at last follow-up. The authors detected that shorter duration of epilepsy was the single most important pre-operative variable, and that the absence of spikes in post-operative EEG predicts a long-term favorable seizure outcome [60].

In this study, other clinical features available prior to resection show a tendency to predict seizure outcome such as the occurrence of generalized tonic clonic seizures and non lesional/lesional IRM. This might help classify individuals who are likely to take advantage of extra temporal surgical procedure.

In a recent revision, a multivariate study described that observable lesions on MRI, non-eloquent location, absence of postoperative seizures, circumscribed pathology, patient age under 18 at surgery (<18 yr), and epilepsy duration correlated with better seizure outcome in extra temporal epilepsy [2].

Conclusion

A multi-disciplinary and multi-modal program for presurgical epilepsy workup and surgical procedures for extra temporal pharmacoresistant epilepsy guided by sequential intra operative ECoG indicates favorable outcomes. The approaches adopted show a safe and viable procedure with mild morbidity and no mortality.

Limitations

The low sample size precludes the extraction of valuable information about potential prognostic factors in this study; however, the standardized diagnostic and surgical procedures in extratemporal pharmacoresistant epilepsy still provide relevant information. The outcomes reveal a number of patients being seizure-free similar to other series, and emphasize the value of presurgical assessment and sequential ECoG in extra temporal epilepsy surgery outcome.

Authors Contribution

The authors of this article were all extensively involved in the surgical program. Dr. Morales was responsible for designing the project. In addition to analyzing and discussing the results she also wrote the paper.

References

1. Roper SN. Surgical treatment of the extratemporal epilepsies. *Epilepsia*. 2009;50(Suppl 8):69-74.

2. Delev D, Oehl B, Steinhoff BJ, Nakagawa J, Scheiwe C, SchulzeBonhage A, et al. Surgical Treatment of Extratemporal Epilepsy: Results and Prognostic Factors. *Neurosurgery*. 2019;84(1):242-52.
3. Mihara T. [Surgical treatment for extratemporal lobe epilepsy]. *Rinsho Shinkeigaku*. 2005;45(11):924-7.
4. Ansari SF, Maher CO, Tubbs RS, Terry CL, Cohen-Gadol AA. Surgery for extratemporal nonlesional epilepsy in children: a meta-analysis. *Childs Nerv Syst*. 2010;26(7):945-51.
5. Lascano AM, Perneger T, Vuillimoz S, Spinelli L, Garibotto V, Korff CM, et al. Yield of MRI, high-density electric source imaging (HD-ESI), SPECT and PET in epilepsy surgery candidates. *Clin Neurophysiol*. 2016;127(1):150-5.
6. Elkins KC, Moncayo VM, Kim H, Olson LD4. Utility of gray-matter segmentation of ictal-Interictal perfusion SPECT and interictal 18F-FDG-PET in medically refractory epilepsy. *Epilepsy Res*. 2017;130:93-100.
7. Greiner HM, Horn PS, Tenney JR, Arya R, Jain SV, Holland KD, et al. Should spikes on post-resection ECoG guide pediatric epilepsy surgery? *Epilepsy Res*. 2016;122:73-8.
8. Tahir MZ, Sobani ZA, Quadri SA, Ahmed SN, Sheerani M, Siddiqui F, et al. Establishment of a comprehensive epilepsy center in Pakistan: initial experiences, results, and reflections. *Epilepsy Res Treat*. 2012;2012:547382.
9. Hanáková P, Brázdil M, Novák Z, Hemza J, Chrastina J, Ošlejšková H, et al. Long-term outcome and predictors of resective surgery prognosis in patients with refractory extratemporal epilepsy. *Seizure*. 2014;23(4):266-73.
10. Hardy SG, Miller JW, Holmes MD, Born DE, Ojemann GA, Dodrill CB, et al. Factors predicting outcome of surgery for intractable epilepsy with pathologically verified mesial temporal sclerosis. *Epilepsia*. 2003;44(4):565-8.
11. Englot DJ, Breshears JD, Sun PP, Chang EF, Auguste KI. Seizure outcomes after resective surgery for extra-temporal lobe epilepsy in pediatric patients. *J Neurosurg Pediatr*. 2013;12(2):126-33.
12. Englot DJ, Raygor KP, Molinaro AM, Garcia PA, Knowlton RC, Auguste KI, et al. Factors associated with failed focal neocortical epilepsy surgery. *Neurosurgery*. 2014;75(6):648-5.
13. Morales Chacón LM, García Maeso I, Baez Martin MM, Bender Del Busto JE, García Navarro ME, Quintanal Cordero N, et al. Long-Term Electroclinical and Employment Follow up in Temporal Lobe Epilepsy Surgery. A Cuban Comprehensive Epilepsy Surgery Program. *Behav Sci (Basel)*. 2018;8(2).
14. Foldvary N. Symptomatic focal epilepsies. In: Wyllie E, editor. *The treatment of epilepsy. Principles and practice*. 3rd ed. Philadelphia: Lippincott Williams & Wilkins; 2001. p. 467-74.
15. Báez-Martín MM, Morales-Chacón LM, García-Maeso I, Estupiñán-Díaz B, Lorigados-Pedre L, García ME, et al. Temporal lobe epilepsy surgery modulates the activity of auditory pathway. *Epilepsy Res*. 2014;108(4):748-54.
16. Morales-Chacon LM, Alfredo Sanchez Catusas C, Minou Baez Martin M, Rodriguez Rojas R, Lorigados Pedre L, Estupiñan Diaz B. Multimodal imaging in nonlesional medically intractable focal epilepsy. *Front Biosci (Elite Ed)*. 2015;7:42-57.
17. Morales LM, Sánchez C, Bender JE, Bosch J, García ME, García I, et al. A neurofunctional evaluation strategy for presurgical selection of temporal lobe epilepsy patients. *MEDICC Rev*. 2009;11(1):29-35.
18. Chang EF, Raygor KP, Berger MS. Contemporary model of language organization: an overview for neurosurgeons. *J Neurosurg*. 2015;122(2):250-61.
19. Blümcke I, Aronica E, Miyata H, Sarnat HB, Thom M, Roessler K, et al. International recommendation for a comprehensive neuropathologic workup of epilepsy surgery brain tissue: A consensus Task Force report from the ILAE Commission on Diagnostic Methods. *Epilepsia*. 2016;57(3):348-58.
20. Louis DN, Perry A, Reifenberger G, von Deimling A, Figarella-Branger D, Cavenee WK, et al. The 2016 World Health Organization Classification of Tumors of the Central Nervous System: a summary. *Acta Neuropathol*. 2016;131(6):803-20.
21. Engel J Jr. Update on surgical treatment of the epilepsies. Summary of the Second International Palm Desert Conference on the Surgical Treatment of the Epilepsies (1992). *Neurology*. 1993;43(8):1612-7.
22. Téllez-Zenteno JF, Hernández Ronquillo L, Moien-Afshari F, Wiebe S. Surgical outcomes in lesional and non-lesional epilepsy: a systematic review and meta-analysis. *Epilepsy Res*. 2010;89(2-3):310-8.
23. Chaudhry N, Radhakrishnan A, Abraham M, Kesavadas C, Radhakrishnan VV, Sankara Sarma P, et al. Selection of ideal candidates for extratemporal resective epilepsy surgery in a country with limited resources. *Epileptic Disord*. 2010;12(1):38-47.
24. Schramm J, Kral T, Kurthen M, Blümcke I. Surgery to treat focal frontal lobe epilepsy in adults. *Neurosurgery*. 2002;51(3):644-54.
25. Binder DK, Von Lehe M, Kral T, Bien CG, Urbach H, Schramm J, et al. Surgical treatment of occipital lobe epilepsy. *J Neurosurg*. 2008;109(1):57-69.
26. Babajani-Feremi A, Rezaie R, Narayana S, Choudhri AF, Fulton SP, Boop FA, et al. Variation in the topography of the speech production cortex verified by cortical stimulation and high gamma activity. *Neuroreport*. 2014;25(18):1411-7.
27. D'Argenzio L, Colonnelli MC, Harrison S, Jacques TS, Harkness W, Scott RC, et al. Seizure outcome after extratemporal epilepsy surgery in childhood. *Dev Med Child Neurol*. 2012;54(11):995-1000.
28. Elsharkawy AE, Pannek H, Schulz R, Hoppe M, Pahs G, Gyimesi C, et al. Outcome of extratemporal epilepsy surgery experience of a single center. *Neurosurgery*. 2008;63(3):516-25.
29. McIntosh AM, Averill CA, Kalnins RM, Mitchell LA, Fabinyi GC, Jackson GD, et al. Long-term seizure outcome and risk factors for recurrence after extratemporal epilepsy surgery. *Epilepsia*. 2012;53(6):970-8.
30. Ramantani G, Kadish NE, Anastasopoulos C, Brandt A, Wagner K, Strobl K, et al. Epilepsy surgery for glioneuronal tumors in childhood: avoid loss of time. *Neurosurgery*. 2014;74(6):648-57.
31. Donadio M, D'Giano C, Moussalli M, Barrios L, Ugarnes G, Segalovich M, et al. Epilepsy surgery in Argentina: long-term results in a comprehensive epilepsy centre. *Seizure*. 2011;20(6):442-5.
32. Mikati MA, Ataya N, El-Ferezli J, Shamseddine A, Rahi A, Herlopian A, et al. Epilepsy surgery in a developing country (Lebanon): ten years experience and predictors of outcome. *Epileptic Disord*. 2012;14(3):267-74.
33. Jayalakshmi S, Panigrahi M, Kulkarni DK, Uppin M, Somayajula S, Challa S. Outcome of epilepsy surgery in children after evaluation with non-invasive protocol. *Neurol India*. 2011;59(1):30-6.
34. Vermeulen L, van Loon J, Theys T, Goffin J, Porke K, Van Laere K, et al. Outcome after epilepsy surgery at the University Hospitals Leuven 1998-2012. *Acta Neurol Belg*. 2016;116(3):271-8.
35. Fernández-Concepción O, López Jiménez M, Valencia-Calderón C, Calderón-Valdivieso A, Recasén-Linares A, Reyes-Haro L, et al. Safety and effectiveness of surgery for epilepsy in children. Experience of a tertiary hospital in Ecuador. *Neurologia*. 2018.
36. Bauer S, Hamer HM. Extratemporal epilepsies. *Handb Clin Neurol*. 2012;107:241-56.
37. Blumcke I, Russo GL, Najm I, Palmmini A. Pathology-based approach to epilepsy surgery. *Acta Neuropathol*. 2014;128(1):1-3.

38. Kloss S, Pieper T, Pannek H, Holthausen H, Tuxhorn I. Epilepsy surgery in children with Focal Cortical Dysplasia (FCD): results of long-term seizure outcome. *Neuropediatrics*. 2002;33(1):21-6.
39. Yao K, Mei X, Liu X, Duan Z, Liu C, Bian Y, et al. Clinical characteristics, pathological features and surgical outcomes of Focal Cortical Dysplasia (FCD) type II: correlation with pathological subtypes. *Neurol Sci*. 2014;35(10):1519-26.
40. Xue H, Cai L, Dong S, Li Y. Clinical characteristics and post-surgical outcomes of focal cortical dysplasia subtypes. *J Clin Neurosci*. 2016;23:68-72.
41. Fauser S, Bast T, Altenmüller DM, Schulte-Mönting J, Strobl K, Steinhoff BJ, et al. Factors influencing surgical outcome in patients with focal cortical dysplasia. *J Neurol Neurosurg Psychiatry*. 2008;79(1):103-5.
42. Fauser S, Essang C, Altenmüller DM, Staack AM, Steinhoff BJ, Strobl K, et al. Long-term seizure outcome in 211 patients with focal cortical dysplasia. *Epilepsia*. 2015;56(1):66-76.
43. Tassi L, Pasquier B, Minotti L, Garbelli R, Kahane P, Benabid AL, et al. Cortical dysplasia: electroclinical, imaging, and neuropathologic study of 13 patients. *Epilepsia*. 2001;42(9):1112-23.
44. Aligholi H, Rezayat SM, Azari H, Ejtemaei Mehr S, Akbari M, Modarres Mousavi SM, et al. Preparing neural stem/progenitor cells in PuraMatrix hydrogel for transplantation after brain injury in rats: A comparative methodological study. *Brain Res*. 2016;1642:197-208.
45. Tassi L, Colombo N, Garbelli R, Francione S, Lo Russo G, Mai R, et al. Focal cortical dysplasia: neuropathological subtypes, EEG, neuroimaging and surgical outcome. *Brain*. 2002;125(Pt 8):1719-32.
46. McGonigal A, Bartolomei F, Régis J, Guye M, Gavaret M, Trébuchon-Da Fonseca A, et al. Stereoelectroencephalography in presurgical assessment of MRI-negative epilepsy. *Brain*. 2007;130(Pt 12):3169-83.
47. Nobili L, Cardinale F, Magliola U, Cicolin A, Didato G, Bramerio M, et al. Taylor's focal cortical dysplasia increases the risk of sleep-related epilepsy. *Epilepsia*. 2009;50(12):2599-604.
48. Bonini F, Barletta G, Plebani M. A real-world evidence-based approach to laboratory reorganization using e-Value benchmarking data. *Clin Chem Lab Med*. 2017;55(3):435-40.
49. Trápaga-Quincoses O, Morales-Chacon LM. [Volumetric measurement and digital electroencephalography in patients with medication-resistant medial temporal lobe epilepsy submitted to surgery]. *Rev Neurol*. 2008;46(2):77-83.
50. Morales Chacón L, Estupiñán B, Lorigados Pedre L, Trápaga Quincoses O, García Maeso I, Sanchez A, et al. Microscopic mild focal cortical dysplasia in temporal lobe dual pathology: an electrocorticography study. *Seizure*. 2009;18(8):593-600.
51. Ravat S, Iyer V, Panchal K, Muzumdar D, Kulkarni A. Surgical outcomes in patients with intraoperative Electrocorticography (EcoG) guided epilepsy surgery-experiences of a tertiary care centre in India. *Int J Surg*. 2016;36(Pt B):420-8.
52. Hader WJ, Tellez-Zenteno J, Metcalfe A, Hernandez-Ronquillo L, Wiebe S, Kwon CS, et al. Complications of epilepsy surgery: a systematic review of focal surgical resections and invasive EEG monitoring. *Epilepsia*. 2013;54(5):840-7.
53. Behrens E, Schramm J, Zentner J, König R. Surgical and neurological complications in a series of 708 epilepsy surgery procedures. *Neurosurgery*. 1997;41(1):1-9.
54. Blount JP. Extratemporal resections in pediatric epilepsy surgery-an overview. *Epilepsia*. 2017;58(Suppl 1):19-27.
55. Cascino GD. Surgical Treatment for Extratemporal Epilepsy. *Curr Treat Options Neurol*. 2004;6(3):257-62.
56. Sarkis RA, Jehi L, Bingaman W, Najm IM. Seizure worsening and its predictors after epilepsy surgery. *Epilepsia*. 2012;53(10):1731-8.
57. Elsharkawy AE, Behne F, Oppel F, Pannek H, Schulz R, Hoppe M, et al. Long-term outcome of extratemporal epilepsy surgery among 154 adult patients. *J Neurosurg*. 2008;108(4):676-86.
58. Englot DJ. Epilepsy surgery trends in the United States: Differences between children and adults. *Epilepsia*. 2015;56(8):1321.
59. Jin B, Wang J, Zhou J, Wang S, Guan Y. A longitudinal study of surgical outcome of pharmacoresistant epilepsy caused by focal cortical dysplasia. *J Neurol*. 2016;263(12):2403-10.
60. Radhakrishnan A, Abraham M, Vilanilam G, Menon R, Menon D, Kumar H, et al. Surgery for "Long-term epilepsy associated tumors (LEATs)": Seizure outcome and its predictors. *Clin Neurol Neurosurg*. 2016;141:98-105.