



Postoperative COVID-19 Infection after Two Negative Preoperative Tests in a Patient Undergoing Coronary Artery, Mitral Valve, and Left Atrial Cryoablation Surgery

Benjamin Vickery¹, Taylor Jaraczewski², Xavier V Jean³, Matthew Gonzalez¹, Antonio Roki², Paul S Pagel¹ and Hossein Almassi G^{2*}

¹Department of Anesthesiology, Medical College of Wisconsin, USA

²Department of Cardiothoracic Surgery, Medical College of Wisconsin, USA

³Department of Surgery, Medical College of Wisconsin, USA

Abstract

The COVID-19 pandemic has substantially impacted cardiac surgery in Veterans Affairs Medical Centers including mandated use of Reverse Transcription-Polymerase Chain Reaction (RT-PCR) testing prior to cardiac surgery to identify COVID-19 in asymptomatic patients. We describe an elderly man who underwent coronary artery, mitral valve, and left atrial cryoablation surgery after two negative preoperative COVID-19 tests within a week before surgery, but subsequently developed symptoms concerning for active COVID-19 infection with suggestive imaging findings confirmed with RT-PCR testing during the immediate postoperative period. This case illustrates the potential fallibility of preoperative RT-PCR testing for COVID-19, the need for maintaining a high index of suspicion for the infection in postoperative patients, and the importance of personal protective equipment regardless of a patient's assumed COVID-19 status.

Keywords: SARS-CoV-2; COVID-19; RT-PCR testing; Cardiac surgery; Coronary artery disease; Mitral regurgitation

Introduction

Despite aggressive implementation of mandated Reverse Transcription-Polymerase Chain Reaction (RT-PCR) testing and strict public health measures (e.g., wearing of masks, social distancing) designed to mitigate its spread, the Severe Acute Respiratory Syndrome-Coronavirus 2 (SARS-CoV-2; COVID-19) has impacted cardiac surgery in Veterans Affairs Medical Centers. Even negative preoperative RT-PCR testing does not guarantee that postoperative COVID-19 infection will not occur or be disseminated among those responsible for their care. Our case describes an elderly man undergoing complex cardiac surgery after two negative preoperative COVID-19 tests within a week before surgery, subsequently developing active COVID-19 infection confirmed with RT-PCR testing during the immediate postoperative period.

Case Presentation

A 75-year-old man with hypertension, hyperlipidemia, diabetes mellitus, a tobacco use disorder, and chronic obstructive pulmonary disease was referred to our cardiac surgery service for management of severe three-vessel coronary artery disease, mitral valve regurgitation resulting from posterior mitral leaflet flail, and chronic atrial fibrillation that was unresponsive to medical management, cardio version, and radiofrequency ablation. Two days before the scheduled surgery, the patient tested negative for COVID-19 with RT-PCR. The patient denied COVID-19 symptoms. Upon arrival the morning of surgery, he stated he neglected to discontinue several medications (including metformin and lisinopril) as instructed, so his operation was postponed for five days. Repeat RT-PCR testing performed the day before the rescheduled surgery was also negative. The patient again denied symptoms of COVID-19. His scheduled three-vessel coronary artery bypass graft surgery, mitral valve repair, left atrial cryoablation (MAZE procedure), and left atrial appendage closure were performed without complication. He was transported to the Intensive Care Unit (ICU) after surgery and his trachea was extubated later that day. The patient's initial postoperative course was uneventful, but he developed a barking, nonproductive cough and gradually increasing oxygen requirements on the 3rd postoperative day. Bi level positive airway pressure was required to maintain

OPEN ACCESS

*Correspondence:

Hossein Almassi G, Department of Cardiothoracic Surgery, Medical College of Wisconsin, 8700 Watertown Plank Road, Milwaukee, WI 53226, USA, Tel: 414-955-6919; Fax: 414-955-0074;

E-mail: halmassi@mcw.edu

Received Date: 08 Jan 2021

Accepted Date: 03 Feb 2021

Published Date: 12 Feb 2021

Citation:

Vickery B, Jaraczewski T, Jean XV, Gonzalez M, Roki A, Pagel PS, et al. Postoperative COVID-19 Infection after Two Negative Preoperative Tests in a Patient Undergoing Coronary Artery, Mitral Valve, and Left Atrial Cryoablation Surgery. *Clin Surg.* 2021; 6: 3073.

Copyright © 2021 Hossein Almassi G. This is an open access article distributed under the Creative Commons Attribution License, which permits unrestricted use, distribution, and reproduction in any medium, provided the original work is properly cited.

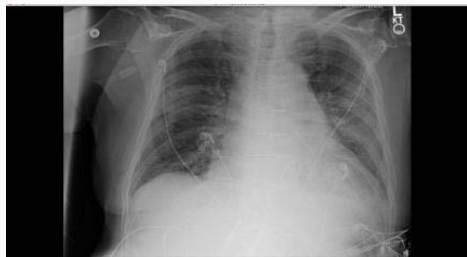

Figure 1: Chest radiograph demonstrating post-operative changes with bilateral infiltrates and a left pleural effusion.

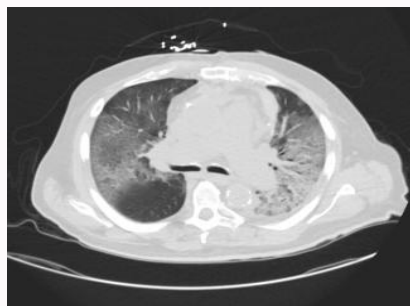


Figure 2: Axial thoracic computed tomographic image demonstrating bilateral ground glass opacities and interlobar septal thickening.

oxygen saturation greater than 90%. The patient reported malaise and fatigue, but he was afebrile and denied other constitutional complaints. Serial white blood cell counts remained in the normal range. A chest radiograph showed left retro cardiac consolidation (Figure 1). Thoracic computed tomography demonstrated bilateral ground-glass opacities and intralobular septal thickening consistent with multifocal pneumonia and inflammation (Figure 2). Based on the patient's worsening clinical condition and the computed tomography results, another RT-PCR test for COVID-19 was obtained. This test was positive. The patient transferred from the surgical ICU to our hospital's dedicated COVID ICU. He was treated with humidified high-flow nasal cannula oxygen (Vapotherm Precision Flow®, Exeter, New Hampshire), Remdesivir, convalescent plasma, and dexamethasone. Following slow improvement, he transferred out of the COVID ICU ten days after the diagnosis was established and discharged from the hospital on the 31st postoperative day after extensive rehabilitation. Notably, several staff nurses, residents, and medical students providing care for the patient in the surgical ICU before he developed COVID-19 symptoms tested positive for the infection despite following Centers for Disease Control guidelines. These affected individuals isolated at home until they recovered.

Discussion

To our knowledge, this report is the first to describe a patient with two negative preoperative RT-PCR tests within one week of cardiac surgery who subsequently developed COVID-19 symptoms and tested positive for the disease during the immediate postoperative period. Several cases of postoperative COVID-19 have been previously described in cardiac surgery patients, but these cases occurred either in conjunction with urgent or emergent surgery (circumstances in which patients were unable to be tested) or in asymptomatic individuals who were not tested before elective surgery (as was sometimes done before widespread antibody testing was available early during the pandemic) [1,2]. Several cases of postoperative COVID-19 were also described in patients undergoing

other types of surgery who had negative preoperative tests but later manifested active infection [3,4]. Our patient and those described previously [3,4] illustrate the temporal limitations of currently available COVID-19 testing that rely upon a measurable antibody response or a sufficient viral load in patients who do not yet display characteristic clinical symptoms. Indeed, while RT-PCR testing has a high specificity, negative tests may be encountered if the viral titer is low early in the disease course. Some propose computed tomography as an alternative testing modality for COVID-19 that may be useful for identifying the disease in patients with negative tests whose clinical presentation is suspicious [5,6], as illustrated in our patient. Giannitto et al. [7] reported that computed tomography has a higher sensitivity and lower specificity for COVID-19 in patients with negative RT-PCR tests. The authors argued for the early use of this imaging technique to help establish the diagnosis. The radiographic features noted on our patient's scan, including ground glass opacities, generalized inflammation, and multifocal pneumonia, are highly suggestive of COVID-19 infection. Repeat testing in this clinical context to confirm a COVID-19 infection was warranted in our patient, and indeed, his postoperative RT-PCR test was positive. Our patient's clinical presentation illustrates that the diagnosis of COVID-19 should be considered in postoperative cardiac surgery patients when unexpected or new respiratory complaints, relative hypoxemia, increasing oxygen requirements, or bilateral lung imaging abnormalities are present. Clearly, distinguishing such features from those anticipated during the normal course of postoperative recovery requires a high index of suspicion, but most likely should include prompt RT-PCR testing to establish or exclude COVID-19. Our experience also underscores the importance of using recommended personal protective equipment when caring for postoperative cardiac surgery patients independent of negative preoperative testing. Unfortunately, more than one hundred healthcare providers were exposed to COVID-19 before our patient tested positive for the infection during his postoperative course, with several subsequently testing positive. This mass exposure and its consequences emphasize the insidious, highly contagious nature of COVID-19.

References

1. Rescigno G, Firstenberg M, Rudez I, Uddin M, Nagarajan K, Nikolaidis N. A case of postoperative COVID-19 infection after cardiac surgery: Lessons learned. *Heart Surg Forum*. 2020;23:E231-3.
2. Yates MT, Balmforth D, Lopez-Marco A, Uppal R, Oo AY. Outcomes of patients diagnosed with COVID-19 in the early postoperative period following cardiac surgery. *Interact Cardiovasc Thorac Surg*. 2020;31:483-5.
3. Kane AD, Paterson J, Pokhrel S, Berry SK, Monkhouse D, Brand JW, et al. Peri-operative COVID-19 infection in urgent elective surgery during a pandemic surge period: A retrospective observational cohort study. *Anaesthesia*. 2020;75(12):1596-604.
4. Prieto M, Gastaca M, Ruiz P, Ventoso A, Palomares I, Rodriguez-Alvarez RJ, et al. A case of COVID-19 immediately after liver transplantation: not only bad news. *Ann Hepatobiliary Pancreat Surg*. 2020;24:314-8.
5. Xie X, Zhong Z, Zhao W, Zheng C, Wang F, Liu J. Chest CT for typical Coronavirus Disease 2019 (COVID-19) pneumonia: Relationship to negative RT-PCR testing. *Radiology*. 2020;296:E41-5.
6. Tavare AN, Braddy A, Brill S, Jarvis H, Sivaramakrishnan A, Barnett J, et al. Managing high clinical suspicion COVID-19 in patients with negative RT-PCR: A pragmatic and limited role for thoracic CT. *Thorax*. 2020;75:537-8.
7. Giannitto C, Sposta FM, Repici A, Vatteroni G, Casiraghi E, Casari E, et al. Chest CT in patients with a moderate or high pretest probability of COVID-19 and negative swab. *Radiol Med*. 2020;125:E1260-70.