



Posterior Percutaneous Full-Endoscopic Cervical Foraminotomy as a Treatment for Cervical Osseous Foraminal Stenosis

Zhen Lin¹, Dingsheng Zha¹, Wuyan Xu¹, Lek Hang Cheang², Fernando Cardoso Gomes² and Hao Wu^{1*}

¹Department of Orthopedics, First Affiliated Hospital of Jinan University, China

²Department of Physical Medicine and Rehabilitation, Centro Hospitalar Conde S. Januario, China

Abstract

Objective: To investigate the clinical effects of Posterior Percutaneous Full-Endoscopic Cervical Foraminotomy (P-PECF) for cervical osseous foraminal stenosis.

Methods: A total of 11 patients of cervical osseous foraminal stenosis underwent P-PECF from Jan 2016 to Jan 2018. The Visual Analog Scale score (VAS) and Japanese Orthopedic Association Scores (JOA) were evaluated preoperative, immediate postoperatively, 1 months, 6 months and 12 months post-surgery. The excellent and good rate of surgery was evaluated by the modified Macnab criteria at the last follow-up.

Results: All operations were successful. No spinal cord injury, nerve root or vascular injuries were found. The operation time was 73 min (range from 50 min to 120 min). The intraoperative bleeding was 37 mL (range from 20 mL to 50 mL). The average of hospital stay was 3.1 days (range from 2 to 7 days). All patients were followed up for 12 to 36 months. The VAS scores at immediate postoperatively and at 1, 3, 12 month postoperative were 2.91 ± 1.22 , 2.27 ± 0.90 , 1.64 ± 1.28 , 1.27 ± 1.00 respectively, which was significantly lower than preoperative scores (7.64 ± 1.50) ($P < 0.05$); The JOA scores at immediate postoperatively and at 1, 3, 12 month postoperative were 12.63 ± 1.80 , 15.45 ± 1.36 , 16.09 ± 0.94 , 16.36 ± 0.81 respectively, which was significantly higher than preoperative scores (11.82 ± 1.54) ($P < 0.05$); According to modified Macnab criteria, 9 cases showed excellent results, 1 case showed good result, and 1 case showed fair result, with an excellent and good rate of 90.9%.

Conclusion: P-PECF is a sufficient treatment for cervical osseous foraminal stenosis, and its clinical efficacy was good.

Keywords: Cervical vertebrae; Endoscopy; Minimally invasive; Osseous foraminal stenosis; Posterior cervical foraminotomy

Introduction

Cervical radiculopathy is a dysfunction of a nerve root of the cervical spine causing pain and other symptoms. Cervical osseous foraminal stenosis is a common type of cervical radiculopathy, mainly refers to foraminal narrowing from osteophyte formation, such as hook joint hyperplasia, joint hyperplasia or decreased disc height [1]. Surgical decompression may become necessary when conservative treatment fail.

Anterior Cervical Discectomy and Fusion (ACDF) is currently the gold standard treatment for patients with cervical radiculopathy or cervical osseous foraminal stenosis [2]. However, there are several disadvantages for ACDF, such as limitation of motion and accelerating degeneration of adjacent segment [3]. In recent years, posterior foraminotomy and discectomy was used to address the above problems associated with ACDF. Due to the development of minimally invasive spine surgery and the endoscopic techniques, posterior percutaneous endoscopic cervical discectomy (P-PECD) has become increasingly applied [4,5]. P-PECD has several advantages, such as minimizing the dissection of soft tissue, shortening the stay of hospitalization and reducing the incidence of complication [6]. In 2008, Rutten et al. [7] firstly applied Posterior Percutaneous Full-Endoscopic Cervical Foraminotomy (P-PECF) to treat cervical radiculopathy and obtained satisfactory curative

OPEN ACCESS

*Correspondence:

Hao Wu, Department of Orthopedics,
First Affiliated Hospital of Jinan
University, Guangzhou, Guangdong,
China,

E-mail: woohao@163.com

Received Date: 20 May 2019

Accepted Date: 24 Jun 2019

Published Date: 01 Jul 2019

Citation:

Lin Z, Zha D, Xu W, Cheang LH, Gomes FC, Wu H. Posterior Percutaneous Full-Endoscopic Cervical Foraminotomy as a Treatment for Cervical Osseous Foraminal Stenosis. *Clin Surg*. 2019; 4: 2496.

Copyright © 2019 Hao Wu. This is an open access article distributed under the Creative Commons Attribution License, which permits unrestricted use, distribution, and reproduction in any medium, provided the original work is properly cited.

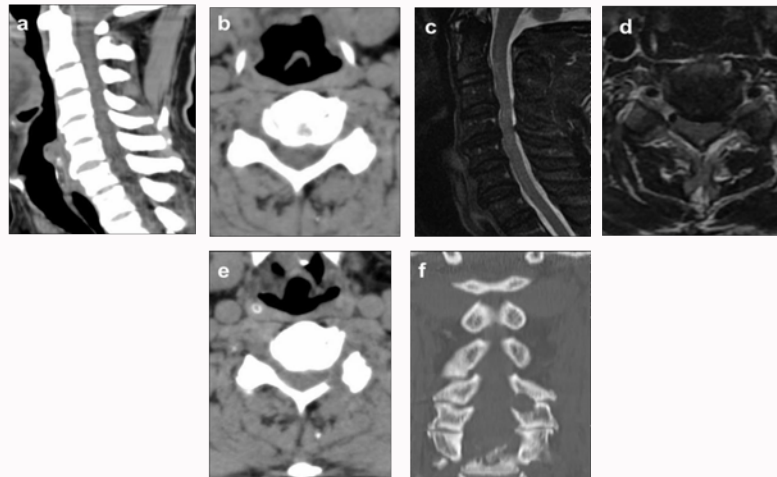


Figure 1: A classic case report, a 48-year-old female patient with osseous foraminal stenosis at C5/6 a. Preoperative cervical CT scan (sagittal); b. Preoperative cervical CT scan (Horizontal position); c. Preoperative cervical MRI scan (sagittal); d. Preoperative cervical MRI scan (Horizontal position); e & f. Cervical CT scan showed nerve root canal enlarged and nerve root relaxed at 1 week after operation.

Table 1: Characteristics of Patients.

Case	Sex	Age (Y)	Level	Blood (ml)	Operation Time (Min)	Hospital Stay (Day)
1	M	46	C5/6	30	70	2
2	M	57	C6/7	80	100	5
3	M	49	C4/5	60	90	2
4	M	52	C6/7	30	80	3
5	M	45	C6/7	100	90	3
6	M	37	C5/6	150	120	7
7	F	48	C5/6	30	70	2
8	F	56	C5/6	40	70	2
9	F	52	C6/7	40	100	2
10	F	46	C5/6	70	120	7
11	F	53	C5/6	50	80	3

effect. In 2015, Kim et al. [8] reported that cervical curvature does not worsen after P-PECD for cervical radiculopathy. Together, P-PECF has widely applied for patients with cervical radiculopathy due to lateral disk herniation.

However, cervical foraminal stenosis is different from disk herniation, which may arise without any disk herniation. The application of P-PECF for patients with osseous foraminal stenosis requires completely relieving pressure in the nerve root from foraminal stenosis [9]. Currently, few studies investigated therapeutic effect of PECF on patients with cervical osseous foraminal stenosis.

In this study, we reviewed 11 patients with cervical osseous foraminal stenosis treated with P-PECF in our department from 2017 to 2018. The purpose of the study was to evaluate clinical outcomes of P-PECF on cervical osseous foraminal stenosis and discuss the technical complications.

Methods

General information

Eleven patients (6 men, 5 women; mean age, 49.1 ± 12 years; range from 37 to 58 years) who underwent Posterior Percutaneous Endoscopic Cervical Foraminotomy and discectomy (P-PECF) between Jan 2017 and Jan 2018 were retrospectively reviewed.

Inclusion criteria

One-sided radiculopathy with arm pain, numbness, decreased muscle strength. Imaging examination revealing cervical osseous foraminal stenosis with no obvious disc herniation. Imaging diagnosis is consistent with clinical symptoms. Conservative treatment was ineffective for more than 3 months, or inability to tolerate the pain.

Exclusion criteria

Patients with central or lateral disc herniation were excluded. Cervical deformity or obvious instability was an absolute exclusion criterion. Cervical spondylotic myelopathy, ossification of the posterior longitudinal ligament, multi-segmental intervertebral foramen stenosis were not included in this study. Spinal cord injury, tumor, blood system diseases and infectious diseases were also excluded.

Surgical methods

The surgical process was described in previous reports. Briefly, patients were placed in a prone position after general anesthesia. A fixation device was applied to fix the cervical vertebra. Neuroelectrophysiological examination was used during surgery. A 7 mm skin incision was made above the medial junction of the inferior and superior facet joint. Then, the obturator with 6.9 mm outer diameter was applied. The tip of the obturator was placed at

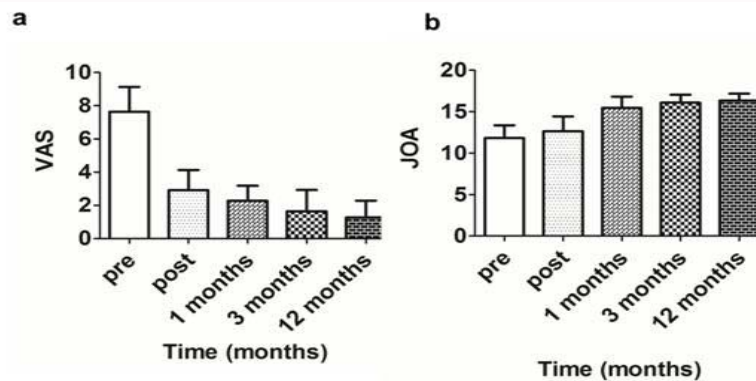


Figure 2: VAS and JOA scales.

Table 2: VAS and JOA scales.

	Preoperative	Postoperative	1 Months	3 Months	12 Months	P Value
VAS	7.64 ± 1.50	2.91 ± 1.22	2.27 ± 0.90	1.64 ± 1.28	1.27 ± 1.00	P<0.05
JOA	11.82 ± 1.54	12.63 ± 1.80	15.45 ± 1.36	16.09 ± 0.94	16.36 ± 0.81	P<0.05

the V-point using fluoroscopic guidance. The working channel and the endoscope was introduced. 0.9% saline solution was continuous irrigated during the operation. The working channel was directed toward the medial side of facet joint to avoid nerve root injury. The V-point was exposed by removing the remnant soft tissue. Then, a 3 mm drill was used to remove the bone and osteophyte. When the hyperplastic bone is grinded to a very thin extent, the thin bone was removed with rongeur. After the ligamentum flavum exposure, the nerve root and the dura mater is fully exposed. The nerve roots were carefully separated by the probe and confirmed the nerve roots were decompressed thoroughly. The working channel was removed and the incision was closed. A suction drain was placed if epidural bleeding was a concern after operation.

Clinical evaluation

Examinations were conducted preoperative, immediate postoperatively and at 1, 3, 12 months postoperative. Pain scoring of upper arm and neck was assessed by Visual Analogue Scale (VAS). The neurological recovery was evaluated by the Japanese Orthopedic Association (JOA) for cervical spondylosis score (17 points). The clinical validity was assessed by the modified Macnab criteria. CT and MRI were performed postoperatively to ensure the decompression of cervical foraminal.

Results

Eleven patients with cervical osseous foraminal stenosis was enrolled in the study. The mean operation time was 73 min, which range from 50 min to 120 min. Foraminotomy and fully decompression of the nerve root canal were conducted in all patients. CT scans was performed 1 week after the operation (Figure 1). The mean intraoperative bleeding was 37 mL, which range from 20 mL to 50 mL. The average of hospital stay was 3.1 days, which range from 2 to 7 days. Characteristics of Patients were showed in Table 1. The clinical outcomes were showed in Table 2 and Figure 2. The VAS scores at immediate postoperatively and at 1, 3, 12 month postoperative were 2.91 ± 1.22, 2.27 ± 0.90, 1.64 ± 1.28, 1.27 ± 1.00 respectively, which was significantly decreased (P<0.05) compared with the preoperative scores (7.64 ± 1.50). The JOA scores at immediate postoperatively and at 1, 3, 12 month postoperative were 12.63 ± 1.80, 15.45 ± 1.36, 16.09

± 0.94, 16.36 ± 0.81 respectively, which was significantly improved (P<0.05) compared with the preoperative scores (11.82 ± 1.54). According to modified Macnab criteria, 9 cases showed excellent results, 1 case showed good result, and 1 case showed fair result, no cases were recorded as bad, with an excellent and good rate of 90.9%. CT scans demonstrated the fully enlargement of the intervertebral foramen. All patients were followed up at least 12 months. One patient had cerebrospinal fluid leakage postoperative, and recovered after conservative treatment for 3 days. No other intraoperative or postoperative complications, such as spinal cord injury, nerve root or vascular injuries were founded.

Discussion

Cervical osseous foraminal stenosis, as a common type of cervical radiculopathy, was caused by joint bone hyperplasia, hyperplasia of the hook vertebral joint and narrowing of the intervertebral space. This type of cervical stenosis often shows symptom of one nerve root on one side. Surgery may become necessary when nonsurgical treatment failed. Surgery is needed to relieve pressure in the nerve root from foraminal stenosis. Cervical Anterior Discectomy and Fusion (ACDF) is the golden standard for cervical radiculopathy. However, ACDF has several disadvantages, such as losing activity of the fusion segment, accelerating the degeneration of the adjacent segments and risk of vascular or nerve injury.

Posterior Percutaneous Endoscopic Cervical Discectomy (P-PECD), as one of the most representative MIS surgery of spine, has become increasingly applied [10,11]. P-PECD has several advantages, such as less trauma, less bleeding, faster recovery and shorter duration of hospital stay compared with traditional surgery [12]. Currently, P-PECD mainly includes P-PECF and discectomy and is mainly used in patients with cervical laterally located soft disc herniation. In 2008, Ruetten et al. [7] firstly applied P-PECF for patients with cervical radiculopathy by a 6.9-mm working channel. In 2015, Kim et al. [8] demonstrated that both P-PECD and tubular retractor-assisted procedure achieved good clinical results for patients with foraminal soft-disk herniation [13]. In addition, patients with cervical kyphotic is associated with poor outcome. In other article, Kim et al. showed cervical curvature, disc height, and segmental angle had not

worsened 2 years after P-PECD [8]. Therefore, posterior endoscopic technique is an alternative option to ACDF for patients with cervical radiculopathy.

However, there are only few reports on the treatment of cervical osseous foraminal stenosis with endoscopic technique. In 2016, Oertel et al. [9] reported 43 cases of cervical osseous foraminal stenosis treated by posterior P-PECF. Pain were relieved in 41 patients, 35 patients were recovered to have normal muscle strength. However, symptom becomes worse in 1 patient. One patient occurred hematoma and 8 patients had recurrence after surgery [9]. In general, clinical efficacy of P-PECF for the treatment of cervical osseous foraminal stenosis is satisfying. However, the recurrence rate and complications are still high. In 2017, Ye et al. reported 9 cases of cervical osseous foraminal stenosis treated by posterior P-PECF and obtained good curative effect. There were no complication and recurrence postoperative [14]. Therefore, it is eager to confirm the efficacy and safety of P-PECF in the treatment of cervical osseous foraminal stenosis, and discuss the complication of this technique.

The aim of our study was to evaluate the clinical outcomes of P-PECF for patients with unilateral cervical osseous foraminal stenosis. Results indicated that foraminotomy and fully decompression of the nerve root canal were conducted in all patients. The arm pain were relieved significantly, VAS scores at immediate postoperatively and at 1, 3, 12 month postoperative were significantly decreased compared with the preoperative scores ($P < 0.05$). JOA scores at immediate postoperatively and at 1, 3, 12 month postoperative were significantly improved compared with the preoperative scores ($P < 0.05$). The modified Macnab results were satisfactory at the last follow up. One patient had cerebrospinal fluid leakage postoperative, and recovered after conservative treatment for 3 days. No other intraoperative or postoperative complications, such as spinal cord injury, nerve root or vascular injuries occurred.

Many percutaneous endoscopy related complications have been reported in the articles, such as nerve root injury, vascular injury, postoperative paresthesia, dural mater injury, cerebrospinal fluid leakage and residual symptoms [15,16]. Among them, nerve root injury is the most common complication in the approach. In our study, no nerve root injury was found postoperative. The following methods should be applied to avoid the incidence of nerve root injury. Firstly, the drill must be directed toward the V point (lateral edge of the facet joint). Secondly, the soft tissue around the nerve root should be carefully examined and checked with the probe before removing. Thirdly, the field of vision must be kept clear, don't tear blindly to avoid injury to the nerve root. Cerebrospinal fluid leakage occurred in 1 patient postoperative, which is common in traditional spine surgery. No dural injury was found during operation; however, cerebrospinal fluid leakage occurred 3 h postoperative. The patient recovered after conservative treatment for 3 days. No hematoma, vascular injury or wound infection occurred. There was no recurrence or reoperation at the last follow-up. P-PECF is a good alternative surgical technique for cervical osseous foraminal stenosis; however, the specific complications of P-PECF should be noticed and avoided.

References

- Burkhardt BW, Muller S, Oertel JM. Influence of Prior Cervical Surgery on Surgical Outcome of Endoscopic Posterior Cervical Foraminotomy for Osseous Foraminal Stenosis. *World Neurosurg.* 2016;95:14-21.

- Lan Z, Huang Y, Xu W. Relationship Between T1 Slope Minus C2-7 Lordosis and Cervical Alignment Parameters After Adjacent 2-Level Anterior Cervical Discectomy and Fusion of Lower Cervical Spine. *World Neurosurg.* 2019;122:e1195-e201.
- Wagner SC, Sebastian AS, Butler JS, Kaye ID, Morrissey PB, Hilibrand AS, et al. C5 Motor Palsy After Single- and Multi-level Anterior Cervical Discectomy and Fusion: A Retrospective Review. *J Am Acad Orthop Surg.* 2019;27(8):e390-e4.
- Wu PF, Li YW, Wang B, Jiang B, Tu ZM, Lv GH. Posterior Cervical Foraminotomy Via Full-Endoscopic Versus Microendoscopic Approach for Radiculopathy: A Systematic Review and Meta-analysis. *Pain Physician.* 2019;22(1):41-52.
- Park JH, Jun SG, Jung JT, Lee SJ. Posterior Percutaneous Endoscopic Cervical Foraminotomy and Discectomy With Unilateral Biptoral Endoscopy. *Orthopedics.* 2017;40(5):e779-e83.
- Zheng C, Huang X, Yu J, Ye X. Posterior Percutaneous Endoscopic Cervical Discectomy: A Single-Center Experience of 252 Cases. *World Neurosurg.* 2018;120:e63-e7.
- Ruetten S, Komp M, Merk H, Godolias G. A new full-endoscopic technique for cervical posterior foraminotomy in the treatment of lateral disc herniations using 6.9-mm endoscopes: prospective 2-year results of 87 patients. *Minim Invasive Neurosurg.* 2007;50(4):219-26.
- Kim CH, Shin KH, Chung CK, Park SB, Kim JH. Changes in cervical sagittal alignment after single-level posterior percutaneous endoscopic cervical discectomy. *Global Spine J.* 2015;5(1):31-8.
- Oertel JM, Philipps M, Burkhardt BW. Endoscopic Posterior Cervical Foraminotomy as a Treatment for Osseous Foraminal Stenosis. *World Neurosurg.* 2016;91:50-7.
- Lee U, Kim CH, Chung CK, Choi Y, Yang SH, Park SB, et al. The Recovery of Motor Strength after Posterior Percutaneous Endoscopic Cervical Foraminotomy and Discectomy. *World Neurosurg.* 2018;115:e532-8.
- Liao C, Ren Q, Chu L, Shi L, Yu Q, Yan Z, et al. Modified posterior percutaneous endoscopic cervical discectomy for lateral cervical disc herniation: the vertical anchoring technique. *Eur Spine J.* 2018;27(6):1460-8.
- Komp M, Oezdemir S, Hahn P, Ruetten S. Full-endoscopic posterior foraminotomy surgery for cervical disc herniations. *Oper Orthop Traumatol.* 2018;30(1):13-24.
- Kim CH, Kim KT, Chung CK, Park SB, Yang SH, Kim SM, et al. Minimally invasive cervical foraminotomy and discectomy for laterally located soft disk herniation. *Eur Spine J.* 2015;24(12):3005-12.
- Ye ZY, Kong WJ, Xin ZJ, Fu Q, Ao J, Cao GR, et al. Clinical Observation of Posterior Percutaneous Full-Endoscopic Cervical Foraminotomy as a Treatment for Osseous Foraminal Stenosis. *World Neurosurg.* 2017;106:945-52.
- Wu PF, Liu BH, Wang B, Li YW, Dai YL, Qing YL, et al. Complications of Full-Endoscopic Versus Microendoscopic Foraminotomy for Cervical Radiculopathy: A Systematic Review and Meta-Analysis. *World Neurosurg.* 2018;114:217-27.
- Zhou C, Zhang G, Panchal RR, Ren X, Xiang H, Xuexiao M, et al. Unique Complications of Percutaneous Endoscopic Lumbar Discectomy and Percutaneous Endoscopic Interlaminar Discectomy. *Pain Physician.* 2018;21(2):E105-12.