



Possibility and Prevention of Iatrogenic Blind - Ending Uterine Corpus Occurring after Myomectomy

Hwa Sook Moon^{1*}, Jaseong Koo¹, Hyeyoung Lee¹, Bo Sun Joo², Tae Kyoung Kang¹ and Gyeong Il Nam¹

¹Department of Obstetrics and Gynecology, Center for Minimally Invasive Surgery and Treatment, Good Moonhwa Hospital, Korea

²Infertility Research Institute, Pohang Women's Hospital, Pohang, Kyungsangbuk-do, Korea

Abstract

No case of uterine corpus separation from the cervix following myomectomy has been reported. This report introduces a case of possibility and prevention of iatrogenic blind-ending uterine corpus occurring after secondary myomectomy amenorrhea resulting from iatrogenic separation of the uterine corpus from the cervix following myomectomy. A nulligravida presented with complaints of serious cyclic pelvic pain and secondary amenorrhea. She previously underwent open myomectomy and enucleation of ovarian endometriotic cyst 17 months before at another hospital. Ultrasonography and pelvic magnetic resonance imaging revealed a complete separation of the uterine corpus from the cervix. Laparoscopic finding showed severe adhesion between uterine fundus and bladder, left round ligament and sigmoid colon, and the space between uterine corpus and cervix had been replaced with soft tissue, showing complete loss of continuity between the uterine fundus and cervix. A parasitic myoma on the mesentery and ovarian endometriotic cyst were found. We report a blind uterine corpus as a serious complication of myomectomy.

Keywords: Myomectomy; Secondary amenorrhea; Blind uterine corpus

OPEN ACCESS

*Correspondence:

Hwa Sook Moon, Department of Obstetrics and Gynecology, Center for Minimally Invasive Surgery and Treatment, Good Moonhwa Hospital, 119 Bumil-ro, Dong - gu, Busan, 48735, Korea, Tel: 82 51 630 0750; Fax: 82 51 633 8552;

E-mail: moonhwas@gmail.com

Received Date: 23 Jul 2018

Accepted Date: 14 Aug 2018

Published Date: 16 Aug 2018

Citation:

Moon HS, Koo J, Lee H, Joo BS, Kang TK, Nam G Il. Possibility and Prevention of Iatrogenic Blind - Ending Uterine Corpus Occurring after Myomectomy. Clin Surg. 2018; 3: 2075

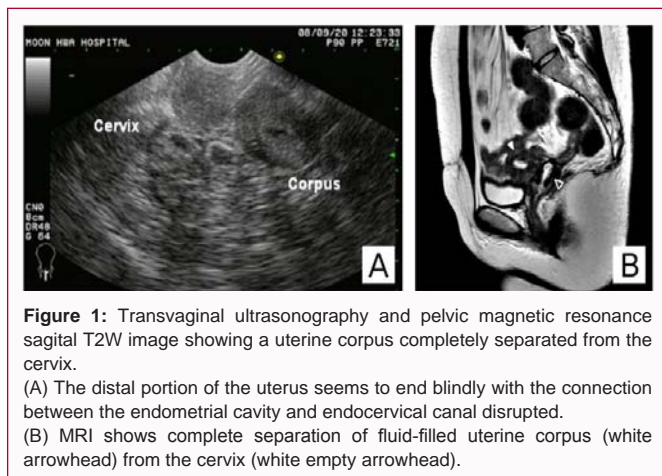
Copyright © 2018 Hwa Sook Moon. This is an open access article distributed under the Creative Commons Attribution License, which permits unrestricted use, distribution, and reproduction in any medium, provided the original work is properly cited.

Introduction

Various rare postoperative complications of myomectomy such as utero-peritoneal fistula and uterine artery pseudoaneurysm have been reported [1]. However, no case of uterine corpus separation from the cervix resulting in blind-ending uterine corpus following myomectomy has been reported although a few studies reported cases of crushing trauma of the pelvis by vehicle accident causing complete separation of the uterine cervix from the corpus [2,3]. This report introduces a case of amenorrhea resulting from iatrogenic separation of the uterine corpus from the cervix following myomectomy.

Case Presentation

A 36 - year-old woman, gravida 0, presented with complaints of serious cyclic pelvic pain and secondary amenorrhea. She had previously undergone open myomectomy and enucleation of ovarian endometriotic cyst at another hospital 17 months before. She had received six cycles of gonadotropin releasing hormone (GnRH) agonist treatment as an adjuvant treatment of endometriosis after myomectomy. At that time, she had no abnormal symptoms. However, she became suffered from cyclic pelvic pain, which was very similar to menstrual pain and which developed three months after completion of the GnRH agonist treatment. However, her menstruation did not resume and she visited our hospital. According to the medical record of the previous hospital, at the time of myomectomy, myoma size on the ultrasonographic examination was 4.8 cm x 3.3 cm x 3.5 cm, whereas pathologic report showed a resected tissue measured 6.5 cm x 4.4 cm x 4 cm and weighed 50 g, and an endometrial tissue was included in the specimen. At our hospital, transvaginal ultrasound revealed complete separation of uterine corpus from the cervix. The distal portion of the uterus seemed to end blindly with the connection between the endometrial cavity and endocervical canal disrupted (Figure 1A). Pelvic magnetic resonance imaging showed stenosis and angulation at the endocervical level, and complete separation of uterine corpus from the cervix (Figure 1B). Laparoscopic examination demonstrated a small uterus with severe adhesion to the bladder, left round ligament and sigmoid colon. The space between uterine corpus and cervix had been replaced with soft tissue, showing complete loss of continuity. Laparoscopic excision of the uterine corpus that had been separated from the cervix was done. The weight of the excised



uterus was 20 gm. Other surgical findings included a 1 cm x 1 cm sized parasitic myoma found on the mesentery and a 3 cm x 2 cm sized right ovarian endometriotic cyst. Laparoscopic excision of the parasitic myoma and enucleation of the right ovarian endometriotic cyst were also performed. The patient's postoperative course was uneventful. The study was approved by written consent form the patient for publication.

Discussion

The present study shows that iatrogenic separation of the uterine corpus from the cervix can occur as a serious complication of myomectomy. This seems to be very unusual as it has not been described in the literature to date. The following three findings support the assumption that this unusual condition has occurred as a complication of myomectomy. First, upon review of medical record from the previous hospital, the myoma size measured only 4.8 cm x 3.3 cm x 3.5 cm on ultrasonographic finding whereas the removed specimen measured 6.0 cm x 4.4 cm x 4 cm and weighed 50 g. Second, the pathological report from the previous hospital revealed presence of endometrial tissue in the specimen, which indicates disruption of the uterine cavity by excision of normal uterine wall including the endometrium. Third, in laparoscopic excision of the uterine corpus at our hospital, the weight of excised uterus was only 20 gm compared to the known normal weight of 45 to 60. This complication can be

possibly explained in two aspects. Firstly, the surgeon of the initial myomectomy might have failed to identify the exact relation of myoma with the endometrium. Especially with a large type 2 to 5 myoma, the opposite uterine wall is likely to be flattened due to compression by the myoma and it may be hard to determine exactly from which wall the myoma is arising. Secondly, all myomas are encapsulated by a pseudocapsule and failure to identify this pseudocapsule could have also led to unnecessary removal of normal tissue [4]. The following three points can help to prevent such unwanted complication. 1) The exact relation of myoma with the endometrium should be identified to decide the appropriate site of incision in the uterine wall, especially with a large type 2 to 5 myoma. MRI or intraoperative transabdominal ultrasound with a transcervically placed sound in the uterine cavity can help to understand the relation between the myoma and endometrium. 2) All myomas are encapsulated by a pseudocapsule, and careful attention is needed not to resect any normal uterine tissue beyond this capsule. 3) Keeping 8 Fr Foley catheter in the uterine cavity through the operation is helpful to confirm in case of accidental entry into the cervical canal or uterine cavity.

Conclusion

In conclusion, this case shows that separation of the uterine corpus from the cervix resulting in iatrogenic blind uterine corpus can be occurred as a complication of myomectomy. Therefore, surgeons must be cautious when removing the myoma, trying not to excise the surrounding normal myometrium considering the two points suggested earlier in the discussion.

References

1. Kesterson J, Dietrich J, Yussman M, Hertweck SP. Secondary amenorrhea resulting from traumatic separation of the cervix from the uterine corpus. *Obstet Gynecol.* 2007;110(2 Pt 2):528-30.
2. Altgassen C, Kuss S, Berger U, Löning M, Diedrich K, Schneider A. Complications in laparoscopic myomectomy. *Surg Endosc.* 2006;20(4):614-8.
3. Kumar S, Sharma JB, Verma D, Gupta P, Roy KK, Malhotra N. Disseminated peritoneal leiomyomatosis: an unusual complication of laparoscopic myomectomy. *Arch Gynecol Obstet.* 2008; 278(1):93-5.
4. Vollenhoven B. Introduction: the epidemiology of uterine leiomyomas. *Ballieres Clin Obstet Gynaecol.* 1998;12(2):169-76.