



Patient-Derived Orthotopic Xenograft Model in Gastric Cancer: A Systematic Review

Rossella Reddavid¹, Simona Corso², Hogla Aridai Resendiz Aguilar¹, Sara Ruscio¹, Silvia Sofia¹, Daniel Moya-Rull³, Stefania Durando³, Silvia Giordano² and Maurizio Degiuli^{1*}

¹Department of Oncology, University of Turin, Italy

²Department of Oncology, University of Torino, Italy

³Department of Oncology, Candiolo Cancer Institute, Italy

Abstract

Background: Patient-Derived Xenografts (PDXs) are, so far, the best preclinical model to validate targets and predictors of response to therapy. While subcutaneous implantation very rarely allows metastatic dissemination, orthotopic implantation (Patient-Derived Orthotopic Xenograft- PDOX) increases metastatic capability.

Methodology: Using a modified tool to analyze model validity, we performed a systematic review of Embase, PubMed, and Web of Science up to December 2018 to identify all original publications describing gastric cancer (GC) PDOXs.

Results: We identified 10 studies of PDOX model validation from January 1981 to December 2018 that fulfilled the inclusion and exclusion criteria. Most models (70%) were derived from human GC cell lines rather than tissue fragments. In 90% of studies, the implantation was performed in the sub serosal layer. Tumour engraftment rate ranged from 0 to 100%, despite the technique. Metastases were observed in 40% of PDOX models implanted into the sub serosal layer, employing either cell suspension or cell-line derived tumour fragments. According to our modified model validity tool, half of the studies were defined as unclear because one or more validation criteria were not reported.

Conclusion: Available GC PDOX models are not adequate according to our model validity tool. There is no demonstration that the submucosal site is more effective than the sub serosal layer, and that tissue fragments are better than cell suspensions for successful engraftment and metastatic spread. Further studies should strictly employ model validity tools and large samples with orthotopic implant sites mirroring as much as possible the donor tumour characteristics.

Keywords: Gastric cancer; Stomach tumour; PDOX; Orthotopic transplantation; PDX; Model validity tool

OPEN ACCESS

*Correspondence:

Maurizio Degiuli, Department of Oncology, Surgical Oncology and Digestive Surgery, San Luigi University Hospital, University of Turin, Regione Gonzole 10, 10043 Orbassano (TO), Italy, Tel: +39 335 8111286; E-mail: maurizio.degiuli@unito.it

Received Date: 05 Aug 2019

Accepted Date: 27 Sep 2019

Published Date: 04 Oct 2019

Citation:

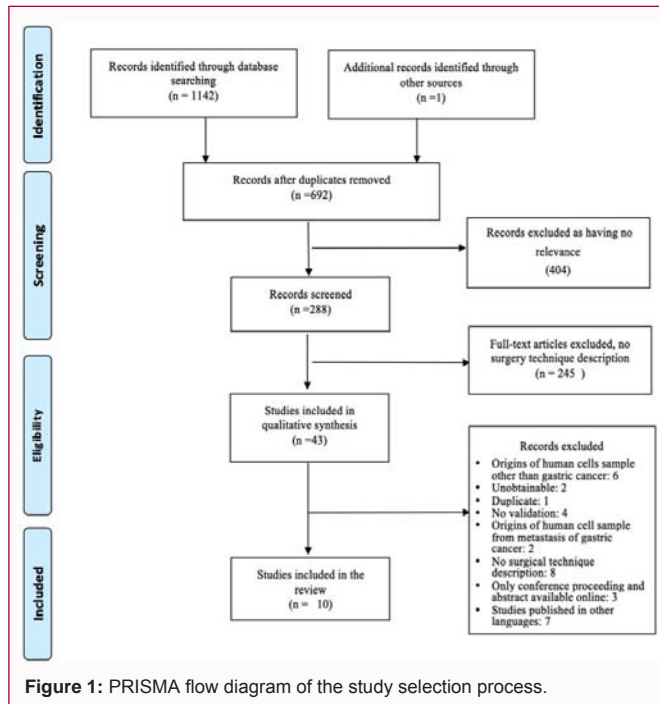
Reddavid R, Corso S, Aridai Resendiz Aguilar H, Ruscio S, Sofia S, Moya-Rull D, et al. Patient-Derived Orthotopic Xenograft Model in Gastric Cancer: A Systematic Review. *Clin Surg.* 2019; 4: 2606.

Copyright © 2019 Maurizio Degiuli.

This is an open access article distributed under the Creative Commons Attribution License, which permits unrestricted use, distribution, and reproduction in any medium, provided the original work is properly cited.

Introduction

Gastric Cancer (GC) is the third leading cause of cancer mortality worldwide (8.2%) after colorectal (9.2%) and lung (18.4%) cancers in both sexes combined [1]. In spite of relevant improvements in surgery and preoperative and adjuvant chemotherapy, advanced and metastatic GC still show poor prognosis. Recent advances in knowledge of GC molecular biology and related signaling pathways provide hopeful strategies for targeted therapies treatment of the disease. So far, only two molecular therapies are worldwide approved: Trastuzumab (for HER2+GCs) and Ramucirumab (targeting angiogenesis) [2,3]. Very recently, Pembrolizumab has been approved as an immunostimulatory treatment in PDL1 positive GCs [4]. To explore the molecular mechanisms supporting tumour growth and its responsiveness to medical treatment, animal models are very helpful. "At the moment, the best preclinical model to validate targets and positive/negative predictors of response to therapy is represented by Patient-Derived Xenografts (PDXs), an experimental model that retains the principal histologic and genetic characteristics of the donor tumour, is predictive of clinical outcome, and is a valuable tool for personalized medicine decisions". This model summarizes many of the disease hallmarks of cancer patients, and is increasingly being applied to investigate existing and new drug therapies, tumour growth, and mechanisms of drug resistance. PDXs are usually generated by transplantation of human tumour tissue or cells into seriously immunodeficient mouse host strains. "Tumors that successfully engraft are further passaged to generate cohorts of tumour-bearing mice for experimental studies. PDX models are generated and used by researchers



in academic, clinical, and pharmaceutical industry settings as well as specialized commercial organizations" [5]. Human subcutaneous tumour xenografts, grown in immunodeficient nude mice, morphologically, biologically, and biochemically closely resemble the original tumors [6-9]. The major problem of PDXs generated by subcutaneous implant is that the transplanted tumors are located in an abnormal microenvironment. Most subcutaneously implanted tumors are encircled by a pseudocapsule, and having little chance to spread to the surrounding tissues seldom metastasizes, regardless of their origin from highly aggressive tumors [8-12]. However, human tumors implanted orthotopically (that is, in the organs of origin of the tumour) in nude mice (Patient-Derived Orthotopic Xenograft-PDOX) show increased metastatic capability [12-15]. Therefore, human gastrointestinal tumors, orthotopically transplanted in any mice, can contribute to enhance our knowledge concerning cancer spreading growth and metastasis. Recently, the technique of orthotopic xenograft has been ameliorated, from the "sewing" method to the "adhering" method [4,16,17]. The progress made in the operative technique strongly decreases the procedure duration and improves animal's morbidity and mortality. However, to date, an optimal GC animal model of orthotopic implantation employing intact tumor tissues is not yet well established. In this review, we report the techniques for generating PDOX models so far described in literature and we objectively evaluate the validity and faithfulness of these animal models as a reliable platform for preclinical experimental medicine in gastric cancer [18].

Survey Methodology

Literature search and systematic review were done adhering to the Cochrane Collaboration guidance (Cochrane) to reduce the risk of bias and error. This Review was conducted according to the Preferred Reporting Items for Systematic Reviews and Meta-Analyses (PRISMA) statement [19].

Literature searches

The research was conducted to identify studies of GC PDOX

models, without any limitations by publication date, language, or publication status (published or unpublished). Search strategies are reported in Table 1. The following databases were investigated on 28 December 2018: Embase 1991_27/12/18, PubMed 1981_27/12/18, and Web of Science 1992_27/12/18 (Collins & Lang, 2018). The searches were performed by the authors with the support of the Federate Library of Medicine of Turin. Keywords were matched and included: in PubMed ("Stomach Neoplasms"[Mesh] OR ((gastric' OR stomach') AND (neoplasm' OR cancer OR cancers OR cancro' OR tumour' OR tumors OR tumora' OR malignant' OR carcinoma')) AND orthotopic' AND ("Mice"[Mesh] OR "Rats"[Mesh] OR "Animals"[Mesh] OR rat OR rats OR mouse OR mice OR murine' OR monkey' OR pig OR pigs OR porcine' OR animal' OR preclinical' OR pre-clinical' OR xenograft' OR xeno-graft' OR "Xenograft Model Anti Assays"[Mesh] OR PDOX), in Embase ('stomach cancer/exp OR ((gastric' OR stomach') AND (neoplas' OR cancer OR cancers OR cancro' OR tumour' OR tumor OR tumors OR tumora' OR malignant' OR carcinoma')) AND ('orthotopic transplantation'/exp OR orthotopic') AND ('mouse'/exp OR 'rat'/exp OR 'animal'/exp OR rat OR rats OR mouse OR mice OR murine' OR monkey' OR pig OR pigs OR porcine' OR animal' OR preclinical' OR pre-clinical' OR xenograft' OR xeno-graft' OR PDOX) and in Web of Science (((gastric' OR stomach') AND (neoplas' OR cancer OR cancers OR cancro' OR tumour' OR tumor OR tumors OR tumora' OR malignant' OR carcinoma')) AND orthotopic' AND (rat OR rats OR mouse OR mice OR murine' OR monkey' OR pig OR pigs OR porcine' OR animal' OR preclinical' OR pre-clinical' OR xenograft' OR xeno-graft' OR PDOX).

Inclusion and exclusion criteria

Inclusion and exclusion criteria are detailed in Table 2. All original reports which described in detail and validated the techniques to generate PDOX mouse models of human gastric cancer were included. Specifically, both the techniques of implantation of human cancer tissue fragments and cultures (≤ 3 passages) were searched. Xenografts generated from metastatic tissue, cell lines, and those established in animals were excluded. Human cells genetically manipulated before implantation were not included as well. Non-English language papers, meeting proceedings, abstracts, letters to the editor and commentaries were also excluded.

Study selection, data extraction, and data synthesis

Four independent reviewers screened titles and abstracts identified by literature search. Abstracts meeting all the inclusion criteria were obtained as full papers and were assessed to confirm whether also the full papers totally met these criteria. All studies excluded at this second step of the screening process were documented along with the reasons for exclusion. Any discrepancies among reviewers were solved through consensus. Data extraction was performed by three reviewers (AR, SR, and SS) and checked by a fourth reviewer (RR). Selected papers were identified by publication year and by the surname of the first Author.

Quality assessment

Study quality and model validity were assessed using SYRCLE's risk of bias tool for animal studies and Collins' certify tool adapted for PDOX, respectively (Table 3a) [20,21]. Authors followed the ARRIVE guidelines checklist to evaluate the adequacy of each study for reporting animal research [22]. The study quality of included studies was independently assessed by for reviewers and any contrarities were solved through discussion and consensus among them.

Table 1: Search strategies.

Data Base	Research Strategy	Studies Matched
PubMed	("Stomach Neoplasms"[Mesh] OR ((gastric' OR stomach') AND (neoplas' OR cancer OR cancers OR cancro' OR tumour' OR tumor OR tumors OR tumora' OR malignan' OR carcinoma))) AND orthotopic' AND ("Mice"[Mesh] OR "Rats"[Mesh] OR "Animals"[Mesh] OR rat OR rats OR mouse OR mice OR murine' OR monkey' OR pig OR pigs OR porcine' OR animal' OR preclinical' OR pre-clinical' OR xenograft' OR xeno-graft' OR "Xenograft Model Antitumor Assays"[Mesh] OR PDOX)	313
Embase	('stomach cancer'/exp OR ((gastric' OR stomach') AND (neoplas' OR cancer OR cancers OR cancro' OR tumour' OR tumor OR tumors OR tumora' OR malignan' OR carcinoma))) AND ('orthotopic transplantation'/exp OR orthotopic') AND ('mouse'/exp OR 'rat'/exp OR 'animal'/exp OR rat OR rats OR mouse OR mice OR murine' OR monkey' OR pig OR pigs OR porcine' OR animal' OR preclinical' OR pre-clinical' OR xenograft' OR xeno-graft' OR PDOX)	510
Web of science	((('gastric' OR stomach') AND (neoplas' OR cancer OR cancers OR cancro' OR tumour' OR tumor OR tumors OR tumora' OR malignan' OR carcinoma))) AND orthotopic' AND (rat OR rats OR mouse OR mice OR murine' OR monkey' OR pig OR pigs OR porcine' OR animal' OR preclinical' OR pre-clinical' OR xenograft' OR xeno-graft' OR PDOX)	319
Total		1142

Table 2: Inclusion and exclusion criteria.

Inclusion criteria	Exclusion criteria
Studies about surgical technique in creation of PDOX	Not surgical technique description
Human cells sample from gastric cancer	Origins of human cells sample other than gastric cancer
Studies published in English	Previous genetic manipulation of human cells
	Only conference proceeding and abstract available online
	Studies published in other languages

PDOX: Patient-Derived Orthotopic Xenografts

Results

Literature searches and inclusion assessment

Figure 1 summarizes the process of identification and selection of papers for inclusion in this systematic review, following the PRISMA guidelines [19]. Literature searches of electronic databases identified 1142 papers and hand searching retrieved 1 additional article. After de-duplication, 692 titles/abstracts were screened by reviewers and 404 articles were excluded as having no pertinence to this systematic review. Titles/abstracts of 288 potentially relevant papers were included for further evaluation and 245 of these were successively excluded because they didn't report technical details of PDOX generation. Of these, 33 papers were left out after examining in detail the full paper; the reasons for rejection are detailed in Figure 1. Overall, we identified 10 studies of PDOX model validation properly fulfilling inclusion and exclusion criteria. Table 4 provides a list of the included studies and their adherence to the Arrive guidelines.

Characteristics of PDOX models

Tables 5a and 5b summarize the main features of the PDOX models as described in the included studies. The majority of these studies reported the use of a PDOX model to improve the understanding of carcinogenesis, cancer spread and metastasis, and to support the research and the development of new and effective therapeutic concepts. Several mouse strains were employed for derivation of gastric cancer animal models; the most common was Balb/c nu/nu (6 studies), athymic nude (2 studies), Bl6/Rag2/Gamma C double knockout (1 study), and CD-1 nude (1 study) mice. The most used site of engraftment for the derivation of gastric models was subcutaneous tissue (60%), followed by the gastric wall. Most models were derived from the engraftment of gastric cancer cell lines (70%), rather than tissue fragments.

Characteristics of transplantation technique

In 1993, performed both orthotopic tumour tissue and cell suspension implantations (SC-1-NU from Nagoya University, H-1 11 from Osaka University, and St-4 and St-40 from the Central Institute for Experimental Animals Kawasaki lines) [23]. They reported two different techniques of orthotopic transplantation of tissue

fragments. In the first approach, "an incision was made through the left upper abdominal para-rectal line and peritoneum of the mice. The stomach wall was carefully exposed, and a part of the serosal membrane, about 3 mm in diameter in the middle of the greater curvature of the glandular stomach, was mechanically injured using scissors. A tumour piece of 150 mg was then fixed on each injured site of the serosal surface with a 4-0 Dexontransmural suture. In the other orthotopic tissue transplantation method, multiple tumour pieces were implanted on the top of the stomach where the serosa had been injured. An 8-0 surgical suture was used to penetrate these small tumour pieces and to suture them on the wall of the stomach" Furukawa. In a further method described by the same Author in this report, a tumor cell suspension (0.1 ml per mouse) was injected into the middle of the greater curvature of the exposed stomach. Mice were sacrificed 12 and 10 to 24 weeks after implantations of intact tissue fragments and cell suspension respectively, to evaluate tumour growth and metastasis. Both the rate of tumour engraftment and that of metastasis development were 100% after orthotopic implantation of intact human GC tissue fragments. On the contrary, they were reduced to 50% and 6.7%, respectively, after injection of cell suspension. The authors concluded emphasizing the importance of implanting intact original tissue fragments to replicate the metastatic behavior of the cancer.

In 1998, Cui et al. implanted surgical tumor specimens of 2 mm³ on the serosal surface of the greater curvature of the antrum and fixed them with 6-0 absorbable transmural suture without subcutaneous passages [24]. Mice were sacrificed at 7 to 21 weeks after tumour transplantation and at autopsy gastric tumors, enlarged lymph nodes, lungs, and livers were removed and addressed to routine histological examination. Tumour growth was reported in 12.5% of cases and metastases never occurred.

Illert et al., [25] published two articles in 2003 about orthotopic transplantation of human GC in nude mouse. In the first article, two groups of nude mice were used for xenotransplantation of GC specimens. In group I, tumor specimens originating from a gastric adenocarcinoma cell line 23132/87 (DSMZ Braunschweig, Germany) were transplanted onto the stomach; in group II, they

Table 3a: Model validity tool.

	Signalling question	Project specific notes	Decision	Justification	
REPORTING	1	Ethical statement specified. Was an ethical statement employed for animal manipulation?	Select reported/Not reported if the experimental protocols were approved by an ethical committee	Reported/Not reported Justification comment.-	
	2	Clear description of mouse model.	Provide details of mouse characteristics. - Provenance, species, age, weight, strain. Select partially reported if only one is reported.	Reported/Partially reported/Not reported Justification comment.-	
VALIDATION	3	Clear description of the routine maintenance of the mice before and after transplantation.	Provide details for mice feeding, isolation from other mice, temperature housing. Select partially reported if only one is reported.	Reported/Partially reported/Not reported Justification comment.-	
	4	Clear description of the preoperative care routine of the model before the experiment	Provide details for preoperative fasting, hair removal, antibiotics and/or analgesic administration. Select partially reported if only one is reported.	Reported/Partially reported/Not reported Justification comment.-	
	5	Clear description of the postoperative care routine of the model after the experiment	Provide details for postoperative fasting, antibiotics and/or analgesic administration. Select partially reported if only one is reported.	Reported/Partially reported/Not reported Justification comment.-	
	6	Clear description of the operative care routine	Provide details of anaesthetic, oxygen administration, hydration, Select partially reported if only one is reported.	Reported/Partially reported/Not reported Justification comment.-	
	7	Clear description of the model euthanasia deadline.	Provide details, indication and or timing for model euthanasia deadline. Select partially reported if only one is reported.	Reported/ Partially reported/Not reported Justification comment.-	
	8	Clear description of the orthotopic tumour implantation technique.	Provide details of the abdominal wall incision, implantation tumour size and place, suturing or fixing technique on the gastric wall. Select partially reported if only one is reported.	Reported/Partially reported/Not reported Justification comment.-	
	9	Clear description of source specimen before orthotopic transplantation.	Provide details of subcutaneous passages, injected gastric cancer cells or fresh specimen orthotopic transplantation.	Reported/Not reported Justification comment.-	
	A	OUTCOMES	Provide details of tumour local growth.	%/Not reported	
	B	OUTCOMES	Provide details of tumour Metastasis site.	% site/Not reported	
	RISK	Overall rating/reporting of model	Low= all domains clearly reported, and there are no concerns with model. Unclear =Any domains are unclear, but not high risk. High risk = there is a concern of high risk		Text to justify why model was given unclear or high rating

were transplanted subcutaneously into both axillaries. Animals of group I were operated on via a left-sided upper abdominal incision. "The stomach was exteriorized and the serosa of the anterior wall was removed with a scalpel. Two or 3 tumor cubes of approximately 10 mm³ to 20 mm³ were sewn on the prepared gastric wall with 9.0 non-absorbable sutures. Animals were sacrificed if the tumour showed a growth of 10 mm diameter or if their general condition declined; frozen sections of tumors and organs (abdominal organs, lymph nodes, lungs, and retroperitoneal organs) were histologically examined" Illert. The authors reported primary tumor growth in 90% of mice and metastases spread to the liver (70%), lung (10%), and lymph nodes (10%).

In their second article, Illert et al., [26] performed orthotopic xenotransplantation of primary GCs (series 1) and of tumour fragments derived from GC cell line 23132/87 (DSMZ, Braunschweig, Germany) (series 2). "Animals were laparotomized via a left-sided upper abdominal incision. The stomach was exteriorized, and the serosa of the anterior wall was removed with a scalpel. Two or three tumor cubes of approximately 2 mm to 3 mm in length were sewn onto the exposed gastric wall with 9.0 non-absorbable sutures, using microsurgical techniques. Animals were sacrificed after tumor growth reached 10 mm in diameter, or if tumour growth induced a general health decline in mice. All animals were dissected and examined macroscopically". Tumor growth was poor and slow in series 1 (22% growth rate), while all mice developed tumors in series 2 (100% growth rate) and distant metastases occurred in 11% and 88% in series 1 and 2, respectively.

In Jones-Bolin's trial, human GC xenograft tumors were generated by injecting human GTL-16 GC cells subcutaneously [27]. The reported orthotopic transplantation technique is characterized

by the following steps: a small horizontal skin incision was made over the left lateral abdominal area; once the underside of the stomach was exposed, two 2 mm³ × 2 mm³ tumor fragments were pierced with a needle of 6/0 prolene and gently glided onto the prolene wire. Tissue fragments were sown to the dorsal side of the stomach in the mid-section, using two or three knots. Mice were sacrificed when they lost >15% body weight, developed ascites or after 8 weeks from implantation. At necropsy, tumour spread throughout the peritoneum and to different organ sites was grossly assessed. The authors reported primary tumour growth in >90% of mice and metastasis spread to the liver (40%), lymph nodes (40%), and peritoneal surface (60%) involving several organs, such as kidney, spleen, or diaphragm, in addition to the development of ascites. In Bharghava's et al. [28] report, 3 different human GC cell lines ("AGS poorly differentiated, MKN-45 poorly differentiated, and NCI-N87 well differentiated, from the European Collection of Cell Cultures Salisbury, UK") were injected subcutaneously to originate tumour fragments. "The animals' abdomens were opened by a midline incision and the stomach was gently exteriorized. One small tissue pocket was prepared either in the submucosa of the distal stomach or the gastric cardiac using a micro scissor. One donor tumour fragment was placed into each gastric tissue pocket and fixed with one drop of tissue glue (Hystoacryl, B.Braun, Tuttlingen, Germany)" Bharghava's. Four, eight, and twelve weeks after implantation, 10 animals of both distal stomach or gastric cardiac implantation-site groups, and of each GC cell line group, were sacrificed and a necropsy was done to assess tumour spread. Implantation of donor tumour fragments resulted in orthotopic tumour growth in 100% of both implantation-site groups, despite the type of cell line used for obtaining the tissue fragment. Metastatic spread to the lung, pancreas, liver, bowel, retroperitoneum, and kidney was reported from 10 to 50% after 12

Table 3b: Model validity tool applied to studies described in this review.

ID STUDY	Question 1	Question 2	Question 3	Question 4	Question 5	Question 6	Question 7	Question 8	Question 9	A	B	Overall rating/reporting of model	
Furukawa [26]	Not reported	Partial reported	Partial reported	Not reported	Not reported	Partial reported	Reported	Reported	Reported	100% (intact tissue) 50% (cell suspension)	69.2% (intact tissue) 0% (Cell suspension)	High	No ethical statement. Unclear description of mice characteristics. No description of perioperative care. Unclear description of intraoperative protocol.
Cui [27]	Not reported	Partial reported	Not reported	Not reported	Not reported	Partial reported	Reported	Reported	Reported	12.5%	0%	High	No ethical statement. Unclear description of mice characteristics. No description of perioperative care Unclear description of intraoperative protocol. Low growth rate and metastases never occurred
Illert [28]	Reported	Reported	Reported	Not reported	Not reported	Partial reported	Reported	Partial reported	Reported	90%	70% liver, 10% lung, 10% lymph node	High	Unclear description of mice characteristics. No description of perioperative care Unclear description of intraoperative protocol
Illert [29]	Not reported	Reported	Reported	Not reported	Not reported	Partial reported	Reported	Partial reported	Reported	22% Fresh specimen 100% cellular lines	11% Fresh specimen 88% cellular lines	High	No ethical statement. Unclear description of mice characteristics. No description of perioperative care Unclear description of intraoperative protocol.
Jones- Bolin [30]	Reported	Reported	Partial reported	Not reported	Not reported	Reported	Reported	Reported	Reported	>90%	40% liver or lymph nodes 60% peritoneal surface involving other organs, such as kidney, spleen, or diaphragm	U/NR	not all validation criteria were met
Bhargava [18]	Not reported	Reported	Reported	Not reported	Partial reported	Reported	Reported	Reported	Reported	100%	33% liver, lung, pancreas, retroperitoneum, kidney, bowel	U/NR	not all validation criteria were met
Li [31]	Reported	Reported	Reported	Not reported	Not reported	Partial reported	Reported	Reported	Reported	100%	lymph nodes 58%, liver 78%, kidney 39%, and peritoneum, diaphragm 81%	U/NR	not all validation criteria were met
Li [32]	Reported	Reported	Reported	Not reported	Partial reported	Reported	Reported	Reported	Reported	100%	Lymph node 79%; liver 91%; kidney 62%; lung 25%; spleen 29%; testicle 20%; peritoneum 91%	Low	
Busuttill [33]	Reported	Partial reported	Reported	Not reported	Not reported	Reported	Reported	Reported	Reported	100%	80% thoracic or abdominal	U/NR	not all validation criteria were met
Feng [34]	Reported	Reported	Reported	Not reported	Not reported	Reported	Reported	Reported	Reported	100%	Liver, spleen, lung (20%)	U/NR	not all validation criteria were met

weeks. In Li's trial Li et al., [29] human gastric cancer cell suspensions (SGC-7901 poorly differentiated, obtained from the Centre of Cell Cultures of Chinese Academy of Medical Sciences, Shanghai, China) were inoculated subcutaneously into a nude mouse to originate solid tumors, and fragments of these tumors were engrafted beneath the serosal layer. A small tissue pouch was made in the serosal layer in the middle of the greater curvature with the help of a micro scissor. A tumour scrap was inserted into the small pouch and pasted with a spot of "medical tissue glue (Shunkang Corporation of Biological Adhesive, Beijing, China)" Li. Engrafted animals were progressively necropsies every two weeks to assess primary tumour growth, spread and metastasization. Primary tumour was reported to develop from 2 to 4 weeks, gradually increase in volume starting from the 6th week after implantation, and reach a growth peak at the 12th week. The rate and sites of metastasis were analyzed and "the following results were reported: lymph nodes 58%, liver 78%, kidney 39%, and peritoneum and diaphragm 81%" Li. Li et al., [30] in published a second article on orthotopic transplantation. Two different human GC cell suspensions ("SGC-7901 and BGC-823 purchased from the Centre of Cell Cultures of Chinese Academy of Medical Sciences,

Shanghai, China") were injected subcutaneously to originate solid tumors, and then tumor fragments were implanted under the serosal coat of the stomach. A left-lateral upper abdominal incision was made, the stomach was exteriorized, a small tissue pouch was done in the middle of the greater curvature with the help of a micro scissor, and then a tumour scrap was pasted into the tissue pouch with a spot of medical tissue adhesive (Shunkang corporation of Biological Adhesive, Beijing, China). At animals' death, mice were necropsies to assess tumour growth and metastases. The tumor uptake rate after orthotopic implantation in both groups was 100%. The Authors observed high incidence of metastases in lymph nodes (79%), liver (91.5%), kidney (62.5%), lung (25%), peritoneum or diaphragm (91%), spleen (58%), and testis (42%). In Busuttill's trial Busuttill et al., [31] the Authors tagged three different gastric cancer cell lines (MKN45, AGS, and MKN28 from Murdoch Children's Research Institute) with luciferase; tagged cell lines were then inoculated into the subserosalcoat of the stomach. In their surgical technique, "a sub-xiphoid midline incision was made and the stomach was exteriorized. A dissecting microscope was used to guide the needle containing 50 ul of the cell/madrigal suspension into the sub serosal layer of the

Table 4: List of included studies and records and their adherence to Arrive guidelines.

First Author (Year)	Article title	Primary research location	Country	Adherence to ARRIVE guidelines
Furukawa [26]	Orthotopic transplantation of histologically intact clinical specimens of stomach cancer to nude mice: correlation of metastatic sites in mouse and individual patient donors.	Department of Surgery, School of Medicine, Keio University. Tokyo, Japan	Japan.	No
Cui [27]	Intact tissue of gastrointestinal cancer specimen orthotopically transplanted into nude mice	Clinic for General Surgery and Thoracic Surgery, and Institute of Pathology, Christian-Albrechts-University, Kiel, Germany	Germany	No
Illert [28]	Detection of disseminated tumor cells in nude mice with human gastric cancer	Department of Surgery, University Hospital, University of Würzburg, Germany;	Germany	No
Illert [29]	Optimization of a metastasizing human gastric cancer model in nude mice	Department of Surgery, University of Würzburg, Würzburg, Germany	Germany	No
Jones-Bolin [30]	Orthotopic models of human gastric carcinoma in nude mice: applications for study of tumor growth and progression.	Oncology Research, Cephalon, Inc., West Chester, Pennsylvania	USA	No
Bhargava [18]	An orthotopic nude mouse model for preclinical research of gastric cardia cancer	Department of Surgery, Charité School of Medicine Campus Benjamin Franklin, Hindenburgdamm 30, 12203 Berlin, Germany	Germany	No
Li [31]	Serial observations on an orthotopic gastric cancer model constructed using improved implantation technique	Yan Li, Xiao-Ling Wu, Department of Gastroenterology, the Second Affiliated Hospital, Chongqing Medical University, Chongqing 400010, China	China	No
Li [32]	Characterization of gastric cancer models from different cell lines orthotopically constructed using improved implantation techniques	Yan Li, Xiao-Ling Wu, Department of Gastroenterology, the Second Affiliated Hospital, Chongqing Medical University, Chongqing 400010, China	China	No
Busuttill [33]	An orthotopic mouse model of gastric cancer invasion and metastasis	Upper Gastrointestinal Translational Research Laboratory, Peter MacCallum Cancer Centre, Parkville, VIC, Australia	Australia	No
Feng [34]	Characterization of an orthotopic gastric cancer mouse model with lymph node and organ metastases using bioluminescence imaging	Department of General Surgery and Hongqiao International Institute of Medicine, Shanghai Tongren Hospital	China	No

antral region of the stomach” Busuttill. The injection was given very slowly to avoid leakages because of unnecessary pressure. “The needle was withdrawn after 20 sec to allow the matrigel to set and prevent inadvertent abdominal seeding of the tumour cells. Successful positioning of the transplant was confirmed by the presence of a matrigel “bleb”” Busuttill. D-Luciferin (Xenogen) was then injected intraperitoneal and images were taken using IVIS Living Image 3.0 software. Engrafted tumor growth and spread were monitored by submitting mice to weekly diagnostic imaging. Animals were sacrificed at specific time frames and immediately autopsied. Soon after gross examination, the stomach and major organs were resected and submitted to imaging technique. Tumor uptake with GC cells ranged from 72.4% to 82% based on cell line aggressiveness. A high rate of metastasis was reported in multiple sites within abdominal and thoracic regions. In the last trial, Feng et al., [32] injected luciferase expressing NCI N87 human GC cells, obtained from the Shanghai Bio model Organisms Center Co., Ltd. (Shanghai, China), into the sub serosa of the gastric body. The orthotopic technique was performed opening the mouse abdomen via a midline incision and exteriorizing the stomach. Cancer cells were inoculated into the sub serosa of the middle of the stomach using a 100 µl syringe with 30 G needle. A cotton swab was pressed against the injection site for ≥ 20 sec to prevent tumour cell leakage into the peritoneal cavity. At 4, 6, 8, and 10 weeks after tumour cells injection, a 200 µl solution of D luciferin was intraperitoneally injected. “Subsequently, mice were anesthetized and at 8 min after D luciferin injection, placed in the Xenogen IVIS 200 chamber with right lateral recumbence for bioluminescence imaging of the orthotopic NCI N87 Luc tumour” Feng. To assess tumor spread in major organs and in lymph nodes at several time frames, mice were culled between week 3 and 10. Lymph nodes, kidney, lung, liver, spleen and the heart were removed and processed for *ex vivo* BLI (bioluminescence imaging) and histopathological examination. The rate of tumor engraftment in the stomach was 100%. On the opposite, metastases were observed only in a few cases and the Authors concluded that unsuccessful metastatic spread could be referred to the well differentiated characterization of

NCI N87 cell line.

Model validity

The model validity tool formerly described by Collins et al., [33] was modified to include further advices specifically for the PDOX models (Table 3a and 3b). Not one single study reported that the ARRIVE guidelines or SYRCL's risk of bias tool had been followed [22].

Discussion

The failure of actual animal models to definitely predict anticancer activity of investigated therapies also in the clinic represents one of the most serious obstacles confronting investigators involved in drug development. On the contrary, PDOX models are thought to be useful to assess the efficacy of single drugs (or their combination) targeting molecular lesions recognized in the engrafted tumors. As a matter of fact, orthotopic implantation of human tumor better mimics the original microenvironment of the tumor itself and thus the therapeutic responses to therapies observed in patients can be more easily reproduced. The strain, sex, and age of mice employed, site and type of tumour engraftment (cell line or tissue fragment), timing of donor autopsy, technique of *in-vivo* or *ex-vivo* imaging to detect tumor growth and metastases, and rate of engraftment and metastatic spread were investigated in this review. The quality of the studies was analyzed according to a modified validity tool proposed by Collins et al., [22], and to the guidelines of animal care and use. The provision of the approval of the Ethical Committee was also enquired. An important issue in the generation of PDXs and PDOXs is the choice of the mouse strain. In fact, it has been shown that the degree of immunodeficiency can affect the engraftment rate, as the most immunodeficient strains usually show the highest take rate; however, they are also more frequently affected by immunoproliferative disease and much more expensive. The majority of Authors (6 of 10) used Balb/C nu-nu mice, while more severely immunodeficient mice strains like the NMRI nude mice, Bl6/Rag2/Gamma C double knockout, or CD-1 mice were employed as tumor hosts in other reports to improve

Table 5a: Animal features as reported in the included studies.

ID Study	Animal features				
	Animal/tumour specimen	Animal/ Age (weeks)/ Sex/ number	Weight	Animal sacrifice time and criteria	Subcutaneous passages (N)
Furukawa [26]	BALB/Ca nu/nu mice, Fresh surgical from advanced gastric cancer and cell line	5 w/M/not specified	not specified	12 and 10 to 24 weeks after implantations of intact tissue and cell suspension respectively	0
Cui [27]	Athymic naval medical research institute NMRI nude mice, tumour specimens from gastric cancer (fresh or frozen)	8-12 w/ M-F/8	not specified	7 th to 21 st week after implantation	each mouse receives simultaneous orthotopic and subcutaneous implantation
Illert [28]	BALB/Ca nu/nu mice; gastric cancer cell line	6-10 w/ F /10	13-16 g	Tumour volume >10 mm or declined general conditions	4 before orthotopic transplantation (group I), direct subcutaneous implantation (group II)
Illert [29]	BALB/Ca nu/nu mice; Tumour specimen and gastric cancer cell line	6-10 w/ F/18	13-16 g	Tumour volume >10 mm or declined general conditions	4 subcutaneous passages for cellular line, direct implantation for fresh specimen
Jones-Bolin [30]	Nude mice athymic nu/nu, gastric cancer cell line	6-8 w, F/not specified	20-25 g	declined general conditions/severe pain/bleeding or infected wound or tumour	1 subcutaneous passage
Bhargava [18]	CD-1 nude mice, Three gastric cancer cellular lines	4 w/M/180	20-30 g	Four, eight and twelve weeks after transplantation	1 subcutaneous passage
Li [31]	Balb/c nu-nu mice , gastric cancer cell line	5-6 w/M/36	18-20 g	Groups of animals were sacrificed every two weeks	1 subcutaneous passage
Li [32]	Balb/c nu-nu mice, gastric cancer cell line	5-6 w/M/24	18-20 g	Not sacrificed	1 subcutaneous passage
Busuttill [33]	BI6/Rag2/Gamma C double knockout mice, here gastric cancer cell lines	age not specified, M/F/63	Not specified	1,2,4 and 6 weeks after injection	0
Feng [34]	BALB/c nude mice, luciferase-expressing human gastric cancer cell line, luciferase-expressing human gastric cancer cell line	4-5 w, F/100	20 g	3 rd -10th week after implantation	0

the engraftment and metastatic spread rates. Nevertheless, despite the use of NMRI athymic nude mice (a specific strain of mice with reduced natural killer cell activity), the reported tumour take rate was very low (7%) and metastases never occurred Cui et al., [24]. The age and sex of mice were different among the studies, but they didn't affect post-operative complications or mortality. These results do not reflect data from literature that identify the adult and male mice as stronger. Most models were derived from the engraftment of established human gastric cancer cell lines (70%), rather than tissue fragments; in 2 papers the authors performed both orthotopic tumour tissue pieces and cell suspension implantations. The use of primary gastric cancer cell lines rather than established ones could be more interesting as it is known that long term culture can allow the onset of many genetic alterations that can affect tumor behavior and metastatic ability. Animals were sacrificed following different timing criteria; in 3 studies they were euthanized when they developed distress signs or when cancer size reached more than 10 mm; in the other articles, they were sacrificed systematically to evidence progressive tumor growth and metastases appearance. Finally, in Li's study (Li et al., 2012), mice were submitted to autopsy soon after their natural death. In the IVIS technology was employed after D luciferin injection to obtain *in vivo* and *ex vivo* bioluminescence imaging. No other *in vivo* or *ex vivo* imaging procedures were performed in the examined articles. In 90% of studies, tumour tissue fragments or cell suspensions were respectively fixed or injected into the sub serosal layer. In only one study, tumour fragments deriving from a cell line were implanted into the submucosal layer. Considering that human gastric cancer originates from glandular cells located in the mucosal layer, theoretically an adequate PDOX model with implantation of tissue/cells in the proper layer still does not exist; only 1 out of 10 studies examined reported a model close to the optimal one. In practice, no significant difference of tumor engraftment and metastatic spread rates were observed by authors reporting models with either submucosal or sub serosal implantation of tumor tissue/

cells. There was ambiguity in the author's definition of 'successful' primary tumor growth; success was based sometimes on a specific tumor size and sometimes on tumor growth after a specific time interval. Although PDOXs are claimed to better mimic donor tumors, as they are also able to develop metastases, and could be used to validate new molecular targeting therapies also for patients with stage IV cancer, their metastatic spread rate was not homogeneous in the examined studies. While it was not observed in one study (implantation of original tumor tissue onto the serosal surface), it was, however, observed at high rates in 40% of PDOX models employing either cell suspension injection or cell-line derived tissue fragments (1 passage sc.), both into the sub serosal layer [22,24]. More than half of the studies (60%) provided ethical statements and followed guidelines for the use of animal and human tissue. It was not the proper goal of this systematic review to strictly evaluate whether authors of included papers reported data in accordance with the guidelines of animal care and use, but it is remarkable that an ethical statement was not provided in 40% of selected studies, and most of them did not even report a clear description of the routine maintenance of animals before and/or after procedure. In accordance with our modified model validity tool, half of the studies were classified as unclear because at least one validation condition was not reported, or researchers did not provide proper data for a part of their models (Table 3b). The most frequent missing data were the details of perioperative management of mice and the accurate description of all steps of the surgical technique. Such information is absolutely necessary to enable other investigators to reproduce models and researches and verify formerly reported findings. Another important point is that authors validated their models with a very small sample. The number of mice employed is not reported in 2 studies [34,35]. The model validity tool described here provides an 'ideal set of validation criteria' for PDOX animal models and can be adjusted and applied to other models or studies (Table 3b) Collins & Lang 2018. Providing evidence to respect all these criteria should be reasonable for a research group. The majority

Table 5b: Surgical technique and results described in the included studies.

ID Study	Surgical technique					Results		
	Anaesthesia	Abdominal incision	Implantation site	Tumour size implanted	Laparotomy closure	Histological assay	Local growth (N)	Metastasis/site
Furukawa [26]	2.5% Avertin	Left upper abdominal pararectal line and peritoneum	Serosa surface, greater curvature of the antrum	A tumour piece of 150 mg -Multiple tumour pieces-0.1 ml of tumour cell suspension	Dexon 6-0 suture	Straight correlation between behaviour of tumour in transplanted mice and patients	26/26 intact tissue 15/30 cell suspension	18/26 intact tissue 0/15 cell suspension
Cui [27]	1.2% Ketamine and 0.16% xylasin solution	Midline of the abdomen	Serosa surface, greater curvature of the antrum	2 mm ³	6-0 absorbable suture	Resemble the original tumours morphologically and biologically	1/8 12,5	0/8
Illert [28]	Isoflurane inhalation	Left-sided upper abdominal incision	Fixed to subserosa with 9-0 non-absorbable suture	10-20 mm ³	2-layers of 6-0 non-absorbable suture	Histological examination revealed: -infiltrating growth to adjacent structures. -lung and liver showed the typical structure of metastatic adenocarcinoma. Positivity for immunostaining with the human CK-8-specific monoclonal antibody CAM 5.2 Infiltration of blood vessels was also observed as a sign of haematogenous metastases	9/10 orthotopic	7/10 orthotopic/ liver 1/10 orthotopic/lung 1/10 orthotopic/ lymph node
Illert [29]	Isoflurane inhalation	Left-sided upper abdominal incision	Fixed to subserosa with 9-0 non-absorbable suture	2-3 mm in length	2-layers of 6-0 non-absorbable suture	Tumour specimens: low local invasivity and distant spreading. -Cellular lines: infiltrating growth to adjacent structures. Histology of the liver and lung showed the typical structure of metastatic adenocarcinoma. Immunostaining positive for the human CK-8-specific monoclonal antibody CAM 5.2. Blood-vessel infiltration as a sign of haematogenous metastasis was observed as well.	2/9 fresh specimens 9/9 cellular lines	1/9 fresh specimens 8/9 cellular lines
Jones-Bolin [30]	intramuscular injection of 100 µl ketamine/xylazine mixture, and isoflurane inhalation	0.5-cm horizontal incision just to the left of midline and under the rib cage	Serosal surface	2 × 2 mm ³	two to four surgical knots of 6.0 Vicryl suture, using. Close the skin with 2 or 3 skin wound clips	Not reported	primary tumour growth in >90%	liver or lymph nodes (40%), and peritoneal surface (60%) involving other organs
Bhargava [18]	Isoflurane inhalation for subcutaneous implantation; intraperitoneal-xylazihydrochloride and Esketaminhydrochloride	Midline of the abdomen	Into submucosa layer of the distal stomach and gastric cardia	1 mm ³	2-layers of 4-0 absorbable suture	Implantation of intact tumour fragments yielded in a complete tumour take rate. Cardia site seems more aggressive behaviour	180/180	60/180 (liver, lung, pancreas, retroperitoneum, kidney, bowel)
Li [31]	Sumianxin II (0.02 mL per animal)	Left-side upper abdominal	Under serosal coat	1 mm ³	4-0 absorbable suture	Glandular differentiation and rich vascularity were present in tumour areas. The stomach tumour invaded the gastric wall following the disruption of the integrity of the mucous layer or muscularis mucosae. Smear of cast-off cells from ascites confirmed the malignant cells from the primary adenocarcinoma	36/36	lymph nodes 58%, liver 78%, kidney 39%, and peritoneum, diaphragm 81%
Li [32]	with Sumi-anxin II (0.02 mL per animal)	Left-side upper abdominal	Under serosal coat	1 mm ³	4-0 absorbable suture	The stomach cancer of the two models infiltrated the various layers of gastric wall with disruption of the integrity of the mucous layer or muscularis mucosae	24/24	Lymph node 19/24; liver 22/24; kidney 15/24; lung 6/24; spleen 7/24; testicle 5/24; peritoneum 22/24
Busuttill [33]	Intreaperitoneal Ketamine and Xylazine	Midline of the abdomen	Into subserose layer of the antral region	0.5 × 10 ⁶ cells were resuspended in 50 ulmatrigel	4-0 and 3-0 Vicryl sutures	Not reported	Ranged from 72.4% to 82% based on cell line malignancy	80% thoracic or abdominal
Feng [34]	Not specified	Midline of abdomen	subserosal layer	40 µl DMEM containing 5 × 10 ⁶ NCI-N87-Luc cells	Not specified	Not reported	100/100	Liver, spleen, lung (20%)

of the included studies described the use of PDOX models for gastric cancer preclinical research or drug development, emphasizing the importance of meticulous validation of these preclinical models.

Conclusion

Gastric cancer PDOX models so far available in literature are not properly adequate according to the model validity tool derived from Collins' former proposal and were mostly validated with low samples. So far, there is no demonstration that the submucosal (or mucosal) site is more effective than the serosal surface or the sub serosal layer for tissue implantation or cell suspension injection, and that tissue fragment implantation is better than cell suspension injection. Importantly, there is only one report of successful orthotopic implantation of primary human tumour tissue. Further studies on gastric cancer PDOX should strictly employ model validity tools and larger samples with orthotopic implantation sites mirroring as much as possible the donor tumour characteristics and microenvironment.

References

- Bray F, Ferlay J, Soerjomataram I, Siegel RL, Torre LA, Jemal A. Global cancer statistics 2018: GLOBOCAN estimates of incidence and mortality worldwide for 36 cancers in 185 countries. *CA Cancer J Clin*. 2018;68(6):394-424.
- Bang YJ, Van Cutsem E, Feyereislova A, Chung HC, Shen L, Sawaki A, et al. Trastuzumab in combination with chemotherapy versus chemotherapy alone for treatment of HER2-positive advanced gastric or gastro-oesophageal junction cancer (ToGA): a phase 3, open-label, randomised controlled trial. *Lancet*. 2010;376(9742):687-97.
- Fuchs CS, Tomasek J, Yong CJ, Dumitru F, Passalacqua R, Goswami C, et al. Ramucirumab monotherapy for previously treated advanced gastric or gastro-oesophageal junction adenocarcinoma (REGARD): an international, randomised, multicentre, placebo-controlled, phase 3 trial. *Lancet*. 2014;383(9911):31-9.
- Bertotti A, Bracco C, Girolami F, Torti D, Gastaldi S, Galimi F, et al. Inhibition of Src impairs the growth of met-addicted gastric tumors. *Clin Cancer Res*. 2010;16(15):3933-43.
- Kamath SD, Kalyan A, Benson AB. Pembrolizumab for the treatment of gastric cancer. *Expert Rev Anticancer Ther*. 2018;18(12):1177-87.
- Giovannella BC, Yim SO, Stehlin JS, Williams LJ Jr. Development of invasive tumors in the "nude" mouse after injection of cultured human melanoma cells. *J Natl Cancer Inst*. 1972;48(5):1531-3.
- Sharkey FE, Fogh J. Metastasis of human tumors in athymic nude mice. *Int J Cancer*. 1979;24(6):733-8.
- Sharkey FE, Fogh J. Considerations in the use of nude mice for cancer research. *Cancer Metastasis Rev*. 1984;3(4):341-60.
- Kyriazis AP, DiPersio L, Michael GJ, Pesce AJ, Stinnett JD. Growth patterns and metastatic behavior of human tumors growing in athymic mice. *Cancer Res*. 1978;38(10):3186-90.
- Fidler IJ. Rationale and methods for the use of nude mice to study the biology and therapy of human cancer metastasis. *Cancer Metastasis Rev*. 1986;5(1):29-49.
- Fu X, Hoffman RM. Human RT-4 bladder carcinoma is highly metastatic in nude mice and comparable to RAS-H-transformed RT-4 when orthotopically onplanted as histologically intact tissue. *Int J Cancer*. 1992;51(6):989-91.
- Gutman M, Fidler IJ. Biology of human colon cancer metastasis. *World J Surg*. 1995;19(2):226-34.
- Killion JJ, Radinsky R, Fidler IJ. Orthotopic models are necessary to predict therapy of transplantable tumors in mice. *Cancer Metastasis Rev*. 1998;17(3):279-84.
- Capellá G, Farré L, Villanueva A, Reyes G, García C, Tarafa G, et al. Orthotopic models of human pancreatic cancer. *Ann N Y Acad Sci*. 1999;880:103-9.
- Fujihara T, Sawada T, Hirakawa K, Chung YS, Yashiro M, Inoue T, et al. Establishment of lymph node metastatic model for human gastric cancer in nude mice and analysis of factors associated with metastasis. *Clin Exp Metastasis*. 1998;16(4):389-98.
- Chen YL, Wei PK, Xu L, Su XM. Nude mouse model of human gastric carcinoma metastasis constructed by orthotopic transplantation using organism glue paste technique. *Ai Zheng*. 2005;24(2):246-8.
- Conte N, Mason JC, Halmagyi C, Neuhauser S, Mosaku A, Yordanova G, et al. PDX Finder: A portal for patient-derived tumor xenograft model discovery. *Nucleic Acids Res*. 2019;47(D1):D1073-D9.
- Moher D, Liberati A, Tetzlaff J, Altman DG; PRISMA Group. Preferred Reporting Items for Systematic Reviews and Meta-Analyses: The PRISMA Statement. *PLoS Med*. 2009;6(7):e1000097.
- Hooijmans CR, Rovers MM, de Vries RBM, Leenaars M, Ritskes-Hoitinga M, Langendam MW. SYRCLE's risk of bias tool for animal studies. *BMC Med Res Methodol*. 2014;14:43.
- Collins A, Ross J, Lang SH. A systematic review of the asymmetric inheritance of cellular organelles in eukaryotes: A critique of basic science validity and imprecision. *PLoS One*. 2017;12(5):e0178645.
- Kilkenny C, Browne WJ, Cuthill IC, Emerson M, Altman DG. Improving bioscience research reporting: the ARRIVE guidelines for reporting animal research. *PLoS Biol*. 2010;8(6):e1000412.
- Furukawa T, Fu X, Kubota T, Watanabe M, Kitajima M, Hoffman RM. Nude mouse metastatic models of human stomach cancer constructed using orthotopic implantation of histologically intact tissue. *Cancer Res*. 1993;53(5):1204-8.
- Cui JH, Krüger U, Vogel I, Lüttges J, Henne-Bruns D, Kremer B, et al. Intact tissue of gastrointestinal cancer specimen orthotopically transplanted into nude mice. *Hepatogastroenterology*. 1998;45(24):2087-96.
- Illert B, Otto C, Thiede A, Timmermann W. Detection of disseminated tumor cells in nude mice with human gastric cancer. *Clin Exp Metastasis*. 2003;20(6):549-54.
- Illert B, Otto C, Braendlein S, Thiede A, Timmermann W. Optimization of a metastasizing human gastric cancer model in nude mice. *Microsurgery*. 2003;23(5):508-12.
- Jones-Bolin S, Ruggeri B. Orthotopic models of human gastric carcinoma in nude mice: applications for study of tumor growth and progression. *Curr Protoc Pharmacol*. 2007;14:14.
- Bhargava S, Hotz B, Buhr HJ, Hotz HG. An orthotopic nude mouse model for preclinical research of gastric cardia cancer. *Int J Colorectal Dis*. 2009;24(1):31-9.
- Li Y, Li B, Xiang CP, Zhang Y, Li YY, Wu XL. Characterization of gastric cancer models from different cell lines orthotopically constructed using improved implantation techniques. *World J Gastroenterol*. 2012;18(2):136-43.
- Yan Li, Bo Li, Yu Zhang, Chun-Ping Xiang, Yuan-Yuan Li, Xiao-Ling Wu. Serial observations on an orthotopic gastric cancer model constructed using improved implantation technique. *World J Gastroenterol*. 2011;17(11):1442-7.
- Busuttill RA, Liu DS, Di Costanzo N, Schroder J, Mitchell C, Boussioutas A. An orthotopic mouse model of gastric cancer invasion and metastasis. *Scientific Rep*. 2018;8:825.
- Feng HY, Zhang Y, Liu HJ, Dong X, Yang SC, Lu Q, et al. Characterization of an orthotopic gastric cancer mouse model with lymph node and organ

- metastases using bioluminescence imaging. *Oncol Lett.* 2018;16(4):5179-85.
32. Collins AT, Lang SH. A systematic review of the validity of patient derived xenograft (PDX) models: the implications for translational research and personalised medicine. *PeerJ.* 2018;6:e5981.
33. Cochrane. *Cochrane Handbook for Systematic Reviews of Interventions.*
34. Yang B, Tuo S, Tuo CW, Zhang N, Liu QZ. A liver-metastatic model of human primary gastric lymphoma in nude mice orthotopically constructed by using histologically intact patient specimens. *Chin J Cancer.* 2010;29(6):579-84.
35. Kobaek-Larsen M, Thorup I, Diederichsen A, Fenger C, Hoitinga MR. Review of colorectal cancer and its metastases in rodent models: comparative aspects with those in humans. *Comp Med.* 2000;50(1):16-26.