



Patellar Dislocation: Etiopathogenic Diagnosis and Treatment Methods

Burnei G^{1,2*}, Răducan ID^{3,4}, Lală CG⁵, Klinaku I⁶, Marti TD^{3,7} and Burnei C^{8,9}

¹Macta Clinic, Constanța, Romania

²Tinos Clinic, Bucharest, Romania

³"Vasile Goldis" Western University of Arad, Arad, Romania

⁴Medical Center ART, Arad, Romania

⁵National Institute of Research and Development in Mechatronics and Measurement Techniques, Romania

⁶Clinical University Center (Q.K.U.) Prishtina, Kosovo

⁷County University Hospital Arad, Arad, Romania

⁸"Carol Davila" University of Medicine and Pharmacy, Bucharest, Romania

⁹Clinical Emergency Hospital, Bucharest, Romania

Abstract

Background: Patella dislocation in children and adolescent arouses great interest both from the etiopathogenic and therapeutic point of view. The most frequent dislocations are the lateral ones and among them the recurrent dislocations. The etiopathogenic diagnosis is essential and the treatment differentiated, depending on this diagnosis. Often the etiopathogenesis is complex and the treatment must be individualized to each case.

Purpose: The paper mainly exposes the etiopathogenic diagnosis, the important stage in the preoperative plenum and the differentiated treatment for children and adolescents.

Method: The study of the literature highlights multiple surgical interventions used to stabilize the dislocated patella. All these interventions address structural and/or functional changes and are supported by the etiopathogenic diagnosis.

Personal case studies benefited from an active process of stabilizing the patella. Patients were fully reintegrated post-surgically into daily life and school sports.

Conclusion: A correct diagnosis allows the choice of an appropriate treatment. In cases with complex etiopathogenesis or syndromic diseases, two or more surgical interventions are used. All surgical interventions in children and adolescents aim to stabilize the patella without injuring the growth cartilage; periarticular soft tissues are used to induce structural changes that improve the configuration and stability of the knee before the growth of the growth cartilage. Patellar dislocation: Etiopathogenic diagnosis and treatment methods.

Introduction

The dislocation and subluxation of the patella is characterized by the total and, respectively, partial loss of the relations between the patella and the femoral trochlea (Figure 1). The occurrence of dislocation is 43 cases per 100,000 people. The highest frequency occurs in the age group 10 to 14.

The patella becomes unstable when changes in bone configuration and soft tissue lesions occur. Its displacement is most often laterally and, extremely rarely, medially or medially and laterally [1,2]. Lateral dislocation may be, depending on the time of occurrence, congenital, developmental, secondary to dysplastic lesions that occur during growth, and posttraumatic.

The condition occurs predominantly in girls, in 85% of cases, and has a family character; children and adolescents of several generations of the same family had lateral patellar dislocation. Patellar dislocation has several causes; on the one hand bone changes and, on the other hand, multiple capsuloligamentar lesions.

OPEN ACCESS

*Correspondence:

Burnei Gheorghe, Macta Clinic,
Constanța, Romania,
E-mail: mscburnei@yahoo.com

Received Date: 12 May 2020

Accepted Date: 12 Jun 2020

Published Date: 16 Jun 2020

Citation:

Burnei G, Răducan ID, Lală CG, Klinaku I, Marti TD, Burnei C. Patellar Dislocation: Etiopathogenic Diagnosis and Treatment Methods. *Clin Surg.* 2020; 5: 2852.

Copyright © 2020 Burnei G. This is an open access article distributed under the Creative Commons Attribution License, which permits unrestricted use, distribution, and reproduction in any medium, provided the original work is properly cited.

Lateral Dislocation of the Patella

Anatomopathological notions

Bone lesions of the femur, tibia, and patella: Femoral lesions consist of hypoplasia of the external femoral condyle, attenuation of the intercondylar groove and the presence of a variable degree of lateral or medial torsion through the anteversion of the femoral neck.

Tibial lesions may be less obvious and more difficult to spot. Lateral torsion of the tibia may occur during growth, and lateral insertion of the patellar ligament should be assessed based on the lateral rotation of the femur. For this, a topogram of the pelvic limb must specify the anteversion of the femoral neck corroborated with the disposition of the femoral condyles, the tibial condyles, and the position of the ankles.

The patella is hypoplastic and the lateral edge less obvious. The articular face has a thinner or flattened convexity, and sometimes a micropatella is present.

Soft tissue injuries: These lesions affect the retinacula, the joint capsule, and the quadriceps tendon. The retinaculum and medial capsule are loose, elongated and thinned, while the lateral ones are short, thickened and induce the lateral displacement of the patella in recurrent, intermittent dislocations or lock it in chronic, permanent ones. These anatomopathological lesions are more apparent in congenital, permanent dislocations and are less obvious in recurrent dislocations where dislocation occurs as a result of a hypoplastic lateral condyle or partial or total rupture of the medial retinaculum, as a result of trauma. Quadriceps lesions often involve myosclerotic structural changes. In congenital patellar dislocation there is always a retraction of the quadriceps which may affect the entire muscle or only the vastus lateralis.

Classification

Lateral dislocation of the patella comprises several types of dislocation:

- 1. Solitary dislocation:** The patient sustains patellar dislocation for the first time. Usually, the cause is traumatic
- 2. Recurrent dislocation:** It occurs after a previous dislocation or in recurrent episodes. It can be traumatic or non-traumatic.
- 3. Habitual dislocation:** The patella dislocates at each flexion of the knee.
- 4. Chronic dislocation:** It is never reduced to knee movements. It can be congenital or secondary to infections or surgery.

Solitary dislocation

This dislocation is actually the first dislocation and is most often caused by trauma. MRI provides characteristic data: Effusions, rupture of the medial patellofemoral ligament and bone contusions located on the medial face of the patella and on the lateral femoral condyle.

Recurrent dislocation of the patella

Clinical examination: After the first dislocation of the patella, the knee is evaluated to perform the reduction.

Hemarthrosis and severe pain can be caused by fractures and require further investigation. If possible, tests are performed for ligament injuries or meniscus.

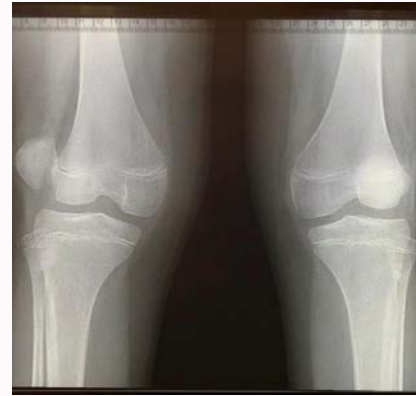

Figure 1: Right patellar dislocation with knee subluxation and left patellar subluxation.

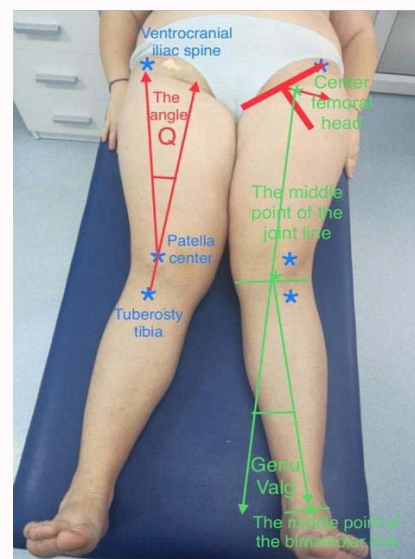


Figure 2: Genu valgum and Q angle with values above the normal limit in a 17-year-old obese woman, with recurrent patellar dislocation.

After the pain and swelling disappear, the risk factors for patella dislocation are analyzed.

The clinical signs that predict and occur in recurrent patella dislocation are:

1. Genu valgum (Figure 2) increases the risk of patellar instability.
2. The associated valgus flat foot increases the degree of deviation in the knee valgus.
3. Walking with the leg rotated inward (in toeing gait) is present in the excessive internal rotation of the femur.
4. Excessive internal rotation of the femur.
5. The "J-patella" defines the sudden lateralization of the patella in the final extension phase of the knee.
6. Patellofemoral crepitations as a result of chondral deterioration.
7. Weakening of the muscular force of the oblique fibers of the vastus medialis.
8. Subcutaneous subfusions may occur after recent recurrent dislocations or traumatic osteochondral lesions.

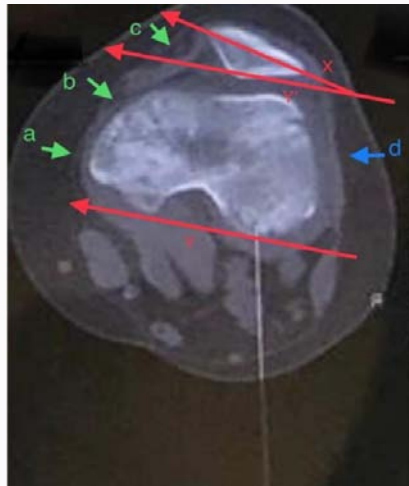


Figure 3: Patellar tilting associated with partial rupture (b) and elongation of the medial patellofemoral ligament thinned (a) and retracted (c); patellofemoral lateral ligament thickened and retracted (d).

9. Patellar tilts. Normally, the patella has a horizontal position. Its tilting occurs due to the retraction and shortening of the lateral retinaculum (Figure 3).

10. The Q angle is formed by the tibial tuberosity-patella center axis and the patella center- ventrocranial iliac spine axis; it has an upper limit of 10 degrees for boys and 15 degrees for girls.

11. Distortion of the femur and tibia to evaluate the anteversion of the femoral neck and external tibial torsion.

12. Ligament laxity: the patient has at least 3 of the 5 Wynn-Davies criteria, or at least 6 of 9 according to the Beighton Scoring System measuring hypermobility.

Investigations: Radiological evaluation is used from the first dislocation. The frontal and lateral radiography confirms that the dislocation was reduced and invalidates the presence of fracture. After the disappearance of the pain and swelling, radiographies are made to detect the position of the patella, its inclination, and the trochlear dysplasia.

The frontal radiography shows the dislocation or subluxation of the patella. Standard radiography of the pelvic limbs identifies genu valgum, a risk factor in recurrent patellar dislocation. Profile radiography shows the position of the patella in relation to the femoral trochlea and helps to establish the diagnosis of patella Alta (high riding patella) after calculating the Insall-Salvatti, Caton-Deschamps and Blackburn-Peel indices or the Blumensaat projection (Figure 4). The calculation of these indices can also be made on CT or MRI sections.

Axial radiography illustrates patellar translation, tilt, trochlear dysplasia, patellofemoral osteochondral avulsions, and fractures. These patellar tangential images are more eloquent in knee flexion, when the patella is located above the trochlea and has a higher degree of instability, and the image clearly highlights the patellofemoral interarticular space. Axial radiography can be done with the knee in flexion at 40 degrees (Mancab technique - in ventral or dorsal position), 45 degrees (Mercant technique), 20 degrees (Laurin technique-dorsal position) and 60 degrees (Hughston technique-ventral position). Each of these positions has advantages and

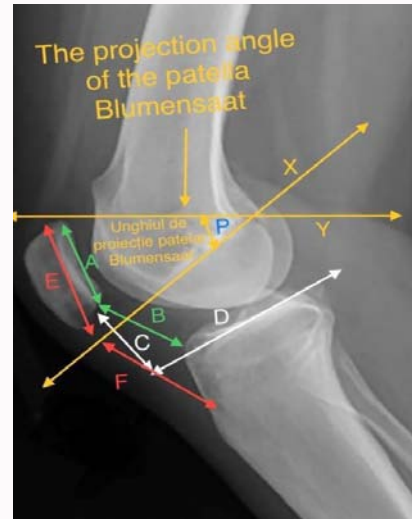


Figure 4: Profile radiography of the knee allows the diagnosis of Patella Alta by the assessment of the following indices: Insall-Salvati Ratio $ISR = F/E$; $N = 0.8 - 1.2$
Caton-Deschamps Index $CDI = B/A$; $N = 0.8 - 1.2$
Blackburne-Peel Ratio $BPR = C/A$; $N = 0.8 - 1$ Blumensaat projection angle = P.

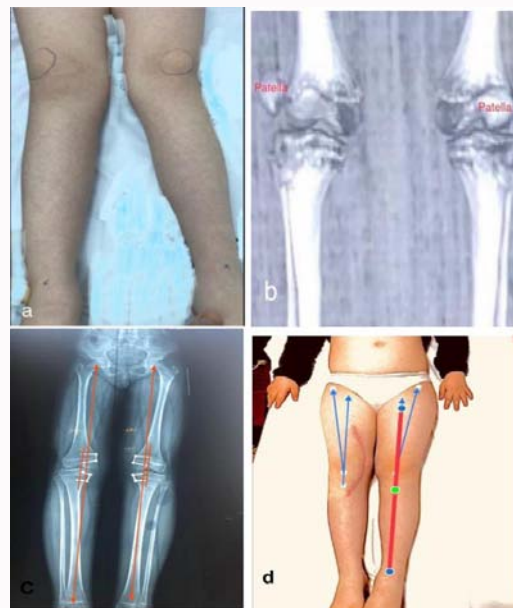

Figure 5: Recurrent dislocation of the right patella and left patellar subluxation in a patient with Down syndrome operated by the Dewar-Galeazzi procedure associated with the Roux-Goldthwait technique (4 interventions during the same surgical intervention); for the bilateral genu valgum, the distal medial hemiepiphyseodesis of the femur and proximal tibia was performed, bilateral. a) Pre-surgery, the clinical examination shows dislocated right patella, subluxated left patella and obvious genu valgum, bilaterally, and CT b) Confirmed the right-side dislocation and left-side subluxation. Post-surgery c) The topogram shows slight hypercorrection in the biomechanical axis, subsequently rectifiable and d) Q angle within normal limits. Left patellar subluxation was corrected by treating genu valgum by hemiepiphyseodesis

disadvantages in interpreting the obtained images.

CT-scan detects fractures. The images can be used for calculating TT-TG (TT: Tibial Tuberosity, TG: Tibial Growth, TT-TG- the distance between the tibial tuberosity and tibial growth), of the indices

for the diagnosis of patella alta, trochlear dysplasia, axial deviations, and distortions.

MRI is practiced in almost all imaging centers. In all cases where the dislocation of the patella occurred secondary to high-intensity traumatic agents and the knee is painful and swollen, an MRI is required. MRI images detect chondral trauma, ruptures of the medial patellofemoral ligament and rule out ruptures of the meniscus or other ligaments.

Risk factors for patellar dislocation are best highlighted by MRI sequences: Trochlear dysplasia, patellar dysplasia, anteversion of the femoral neck, patellar subluxation, lateral patellar tilt, and deficiency of the oblique fibers of the vastus medialis.

In solitary dislocation, also called the primary dislocation, MRI highlights hemarthrosis, bone contusion, osteochondral fractures, lesions of the medial face of the patella, of the lateral femoral condyle, and can detect lesions of the medial patellofemoral ligament that may occur at the first dislocation.

Etiopathogenic nosological entities: The etiopathogenic diagnosis is essential in choosing the therapy method. In complex cases, the main intervention is complemented with other interventions. Sometimes 4 to 8 surgical interventions are needed, at the same time (Figure 5), especially in cases of dislocations due to syndromic diseases.

Femoral trochlear dysplasia affects the ventral portion of the distal femoral epiphysis and may be the cause of patellar dislocation. This entity can be highlighted with the help of CT, CT-3D, and MRI examinations. The evaluation is made by the angle of the trochlear groove; depth of the trochlear groove, ratio of the medial face length/lateral trochlear face length, and trochlear tilting angle (Figure 6).

Dysplasia affects the bone configuration of the trochlea, which ensures bone stability. A dysplastic trochlea results in the loss of stability of the patella and its lateral displacement.

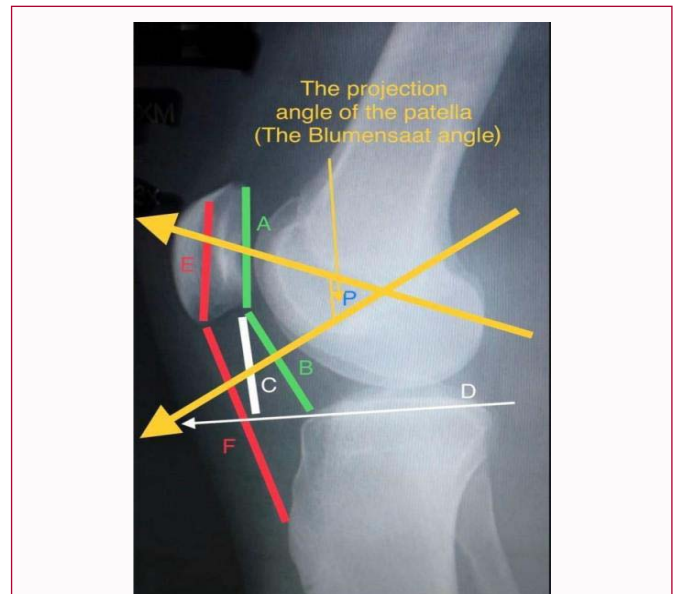


Figure 7: Diagnosis of Patella Alta. All indices are above normal values. The Blumensaat projection angle does not include, or includes partially, the patella.

The stability of the patella in extension is ensured mainly by the tendons and the two retinacula. In maximum knee flexion, the patella has maximum congruence with the intercondylar fossa and stability is ensured mainly by the bones. The patellar stability decreases at a knee flexion of about 30 degrees and in habitual dislocations, when the flexion is around this value, dislocation occurs.

Patella Alta corresponds to its high position (Figure 7). In this position the anatomical ratios change, and the instability of the patella appears in many cases as a result of the loss of the supporting elements. The action mode of the quadriceps in patella Alta is yet unknown. In this position, the patella no longer has a proper, concave bone surface to adapt to its convex surface, and its instability increases during flexion. Its movement is either medial or lateral.

Distortion of the femur and tibia or valgus axial deviations.

These disruptions, whether stand-alone or in combination, cause a resulting lateral vector that moves the patella in this direction. The quantification of these deformities can be done by determining the angle between the quadriceps tendon axis and the extension of the axis corresponding to the patellar tendon. This angle is not edifying, but it can be indicative.

Quadriceps muscle imbalance it is a disruption of the dynamic balance of the quadriceps.

The role of this muscle in the lateral movement of the patella is not well known. There are contradictory opinions regarding the role of each muscular component of the quadriceps in the movement of the patella. Each component participates to varying degrees in the extension of the knee, which is transmitted to the tibia through the patella: The vastus lateralis participates in a proportion of 40%, the vastus medialis 25%, and the rectus femoris and the vastus intermedius 25%. The vastus medialis is most active during knee extension from 30 to 0 degrees. Farahmand F showed that, in the isometric test, the electrical activity of the vastus medialis is twice as high as that of the other components. Mariani and Caruso, after a study in which they analyzed the electromyography activity of the vastus medialis, showed that in a patient with recurrent patellar dislocation, the activity of the vastus medialis was reduced

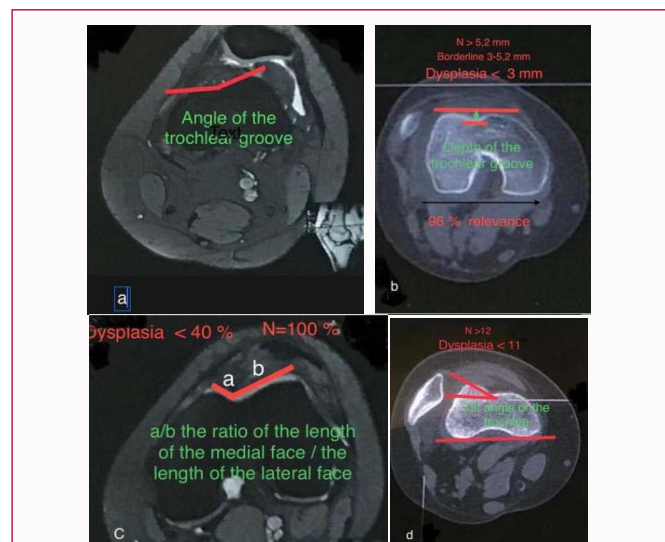


Figure 6: Diagnosis of trochlear dysplasia. CT evaluation, preferably MRI.
 a) Trochlear groove angle.
 b) Depth of the trochlear groove
 c) The ratio between the length of the medial face/the length of the lateral face
 d) Tilt angle of the trochlea.

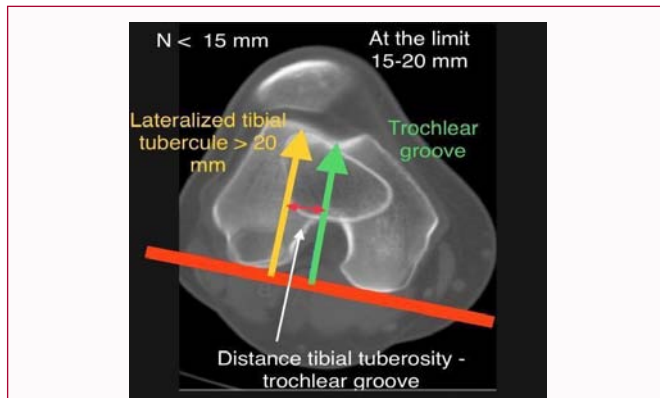


Figure 8: Diagnosis of TT-TG discrepancy and indication for tibial tuberosity medialization.

after the patient was subjected to surgery and the patella was secured in a normal position.

Rupture of the medial femoropatellar ligament. Although the medial retinaculum is larger, it ruptures more frequently and causes posttraumatic lateral dislocation of the patella. The rupturing of the retinaculum occurs most often due to the femorotibial angle opened outwards. The exact dimensions of this angle can be measured by evaluating the Q angle, which has normal values between 10 and 30 degrees (Figure 2). These values correspond to an angle of 170 degrees for boys and 150 degrees for girls.

Laxity of the medial femoropatellar ligament. An important role in the stabilization of the patella is played by the femoropatellar ligaments, placed in extracapsular position; they secure the patella as in a hammock, tracking the patellar face of the femur in the flexion and extension movements of the knee. According to Riga, these ligaments are a parapatellar expansion of the quadriceps tendon that encloses the patella and continues with the patellar tendon. This expansion forms the retinacula of the patella, medially and laterally, which have 3 sections; their longitudinal section attaches to the respective condyles of the tibia, the transverse section to the femoral condyles, and the oblique section, the flabelliform ligaments, to the muscular fibers of the vastus muscles.

This ligament is known as the medial retinaculum or the medial patellar flap, arises from the medial face of the patella and is more distinct and longer. It extends on the medial condyle of the femur and attaches to the tubercle of the adductor magnus, to the condyle tuberosity and to the lateral collateral ligament. Hautamma showed, after conducting a study, that the release of the medial femoropatellar ligament leads to lateral displacement of the patella. Reconstruction of the transverse and oblique portion of the femoropatellar ligament restores the normal position of the patella. If the longitudinal portion, the patellotibial ligament, is restored, the stability does not increase.

Cadaver studies and numerous results obtained on MRI examination show that laxity of the medial ligament leads to the lateral dislocation of the patella.

Retraction of the lateral femoropatellar ligament is also accompanied by the retraction and contracture of the vastus lateralis and occurs post-traumatically or may have an iatrogenic cause in quadriceps stiffness. This ligament has the same components as the medial one and is known as the lateral retinaculum or lateral flap of the patella.

It is shorter and stronger and is strengthened by fibrous bundles coming from the tensor fascia lata and the iliotibial tract. The retraction is much stronger, and the patellar subluxation can sometimes be followed, at variable intervals, by dislocation.

Retraction and shortening of the patellar bundles of the iliotibial band. The pathology of the iliotibial tract is less known. This tract is a fibrous and strong formation stretching all the way to the Gerdy tubercle. It passes over the hip and knee joint and has the role of strengthening them during standing and gait. At the level of the patella, it sends superficial and deep bundles. The retraction of these bundles can be idiopathic, traumatic, or iatrogenic in quadriceps stiffness caused by intramuscular injections and causes patellar subluxation or dislocation.

Laxity of the medial femoropatellar ligament in some syndromes. A series of syndromic conditions can be associated with patellar dislocation: Down syndrome, Turner, Rubinstein Taiby, Kabuky, etc. In Down syndrome, laxity can sometimes be very severe. In syndromic disorders, lateral dislocation of the patella is induced by several causes; frequently, dysplasia of the femoral trochlea associates with angular and torsional deformities, or ligament laxity. In 5 cases of lateral patellar dislocation in children with Down syndrome, I have found the following etiopathogenic entities: Trochlear dysplasia, femoral distortion and walking with the leg turning inward, tibial torsion with lateral insertion of the patellar tendon and laxity of the medial retinaculum.

The diagnosis of these entities is made both on the basis of anamnesic and clinical data but, in particular, by radiological and imaging explorations. Depending on the finding of one or more disorders associated with the same patient, certain surgical interventions will be chosen to correct the defects of conformation, or to attenuate the action of some muscular or capsuloligamentar components that are responsible for the patellar dislocation.

Cerebral palsy: In spastic persons, patellar dislocation occurs more frequently in the form of patella Alta, or recurrent lateral dislocation. In cerebral palsies, the most common etiopathogenic entities are represented by dysplasia of the intercondylar fossa of femur, femoral and tibial disruptions, and disturbance of the disharmonious balance of the quadriceps components.

Treatment

Treatment by orthotics and physical therapy: The first dislocation of the patella must be treated by immobilization in a knee orthosis, in order to rest the knee and give the patient a state of comfort. It may associate with hemarthrosis and, when present, rarely requires an evacuation puncture. From the first days, contractions are started, to strengthen its stabilizing effect; exercises are performed to strengthen, especially the contraction force of the vastus medialis. At the second dislocation, in fact an initial recurrent dislocation, the orthotic and kinetotherapeutic treatment is resumed, although the effectiveness of these methods is not elucidated. For these reasons, some physicians do not recommend this method. They prefer to prescribe a knee brace and the avoidance of exertion that may induce a dislocation. Exercises for muscle strengthening facilitate chondral lesions, at a high threshold, in the form of chondrolysis, or even patellar osteochondral fractures, or femoral trochlea.

Surgical treatment: When the third dislocation of the patella occurs, surgical treatment is considered. Rigorous investigations are made to establish the etiopathogenic diagnosis, in order to choose the

surgical intervention.

The surgical treatment has the role of stabilizing the femuropatellar joint. Recurrent patellar dislocation is treated differently, according to age and according to criteria that take into account risk factors:

- **Static:** dysplasia of the trochlea and patella, genu valgum, distortion of the tibia and femur consisting of the internal and external torsion of the tibia, increased Q angle and patella Alta.

- **Passive:** rupture or stretching of the medial femoropatellar ligament, resection of the lateral retinaculum and retraction of the iliotibial tract.

- **Dynamic:** disruption of the dynamic balance ensuring the stability of the patella.

In children: The use of procedures that do not damage the growth cartilage is always considered. Their protection is done using hemiepiphyodesis, osteotomies or methods that make use of periarticular soft tissues: tendons, muscles, or capsule. All surgical interventions used for children, in the case of trochlear dysplasia, induce changes in the sense of improving morphology before the closure of the growth cartilage [3].

1. Growth guidance by hemiepiphyodesis: Clinical evaluation may determine whether the dislocation is associated with genu valgum. The degree of deviation of the pelvic limbs is checked by the topogram and, if it is found that the genu valgum exceeds 12 degrees, hemiepiphyodesis is used. The biomechanical axis of the pelvic limb will determine whether hemiepiphyodesis will only be performed in the femur, or in the tibia also.

2. Femoral derotational osteotomy. The disposition of the femoral neck in relation to the femoral condyles is studied, and the degree of anteversion of the femoral neck is established. The excessive value of the anteversion is corrected by a femoral derotational osteotomy. The anteversion of the femoral neck is an important risk factor for patellar dislocation [4]. Failure to recognize a severe anteversion may be the cause of a recurrent dislocation after reconstruction of the medial patellofemoral ligament, even if the technique was performed accurately [5].

3. Tibial derotational osteotomy. If the disposition of the tibial condyles in relation to the medial and lateral malleolus highlights the external rotation of the tibia, there is an indication to correct the excess of tibial derotation, by a tibial osteotomy. The distance between the tibial tuberosity and the trochlear groove greater than 20 mm is significant for tuberosity lateralization.

4. Reconstruction of the medial patellofemoral ligament. When the imaging investigations reveal the rupture of the medial patellofemoral ligament or, in the case of a hyperlaxity, the stabilization of the joint is achieved by means of the Dewar-Galeazzi procedure, complemented by the Roux-Goldthwait procedure (Figure 5) [6,7].

The Dewar-Galeazzi procedure consists in performing three surgical interventions, at the same time. This procedure includes

- a) lateral release, by the sectioning of the lateral retinaculum,
- b) transposition of the vastus medialis, by advancing towards the side and an original component,
- c) transfer of the semitendinosus on the patella. The semitendinosus tendon translates the patella laterally and realigns

the quadriceps tendon in the patella- ventrocranial iliac spine axis, ensuring femuropatellar stability.

Sometimes the patella remains rotated, after being stabilized with the semitendinosus tendon. In this case, its positioning is performed by means of the Roux-Goldthwait procedure; the lateral section of the patellar tendon is detached and placed on the medial edge of the patellar tendon. After this stabilization technique, complications occur in 10% of cases, either as lateral patellar dislocation, or as medial patellar dislocation.

To ensure the stability of the femuropatellar joint, and to decrease the recurrence rate, especially in cases with complex etiopathogenesis, most authors associate several interventions. The Green procedure uses quadricepsplasty. This process comprises 3 components; lateral relaxation of the retinaculum, advancement of the tendon margin of the vastus medialis on the lateral edge of the patella and folding of the capsule [8].

The Bakshi procedure ensures the medial repositioning of the patella by using pes anserinus transposition on the patella. Following a clinical study, 21 operated patients are presented, who showed no recurrent dislocations [9].

We preferred only the transposition of the semitendinosus, reinserting the distal extremity of the tendon on the patella, in 18 cases, in patients who showed, in the axial radiological examination, an anatomical position of the patella, a normal Q angle and a normal TT-TG distance; after a follow-up period with an interval between 4 to 18 years, no complications occurred.

Matthews and Schranz provided stability with either the gracilis tendon or the semitendinosus tendon and did not report any recurrence. After 25 interventions, in 21 patients, they found good patellofemoral stability [10].

Lateral release

The relaxation of the lateral band is done when the clinical evaluation and the imaging data reveal the retraction and shortening of the lateral tendon- capsule-ligament component. This release can be done either openly, or arthroscopically. This is indicated in cases where the patient has subluxation, or when the patella is tilted. In the treatment of recurrent dislocation, relaxation alone is not enough, as it is often followed by recurrence or subluxation [11]. It is associated with other interventions: Folding of the medial retinaculum, tendon, or fascial grafts for strengthening the medial retinaculum, reconstruction of the medial patellofemoral ligament, etc. Recurrence after medial relaxation is 30% to 40% and only 4%, when associated with other interventions. In 15% of cases, pain and swelling persist and, in 30% of the cases, crepitations and crackles are perceived.

In adolescents

Tibial tuberosity medialization:

To perform this intervention, the TT axis, and the Trochlear Groove (TG) axis are determined. The two axes are drawn on TG or MRI cross sequences. The transverse reference plane for the trochlea is located approximately 3 cm proximal to the femur-tibia joint line, in the place where the groove of the trochlea is deeper. The section of the tibia overlaps the section of the femur, corresponding to the apex of the tibial tuberosity (Figure 8). The distance between the two axes, TT-TG less than 15 mm is regarded as normal, between 15 mm and 20 mm, at the limit, and even higher than 20 mm, shows

a significant external tibial rotation, and the medialization of the tuberosity is required. The medialization of tuberosity can be done according to the Elmslie-Trillat technique, by horizontal osteotomy, or Fulkerson, by oblique osteotomy. After tuberosity osteotomy, osteosynthesis should be done by using 2 screws.

Tibial tuberosity distalization:

This intervention is applied for patients diagnosed with patella Alta. The patella located in a high position is a risk factor for patellar instability. The diagnosis is established by measurements that show its disposition (Figure 4 and Figure 7).

a) Insall-Salvatti Ratio (ISR) is calculated by dividing the length of the tendon by the length of the patella. Normal values are 0.8-1.2, patella Alta >1.2 and patella baja <0.8.

b) Caton-Deschamps Index (CDI = distance from the lower pole of the articular surface of the patella/length of the articular surface of the patella). It has normal values between 0.8 to 1.2, patella Alta >1.2, patella baja <0.8.

c) Blackburne-Peel Ratio (BPR = length of the perpendicular from the lower edge of the articular cartilage of the patella on the tibial plateau line/length of the articular surface of the patella). Normal values are 0.8 to 1, patella Alta >1.

d) Blumensaat described the normal anterior projection of the patella on profile radiography of a knee bent at 30 degrees. This position can also be detected on a similar CT or MRI image. In this position, the patella is arranged in the anterior angle formed by a line passing through the intercondylar fossa and another passing through the central section of the distal growth cartilage of the femur.

3. Reconstruction of the medial patellofemoral ligament aims to restore the medial ligament ruptured due to posttraumatic factors, or hyperlax.

4. Lateral relaxation when the patella is tilted over 20 degrees.

It can be performed as a single operation, but the results are better if combined with other interventions.

5. Osteotomies of the femur and tibia in the anteversion of the femoral neck, respectively the excessive external rotation of the tibia.

6. Trochleoplasty. Most patients with recurrent patellar dislocation have trochlear dysplasia. In children and adolescents, trochleoplasty is applied less frequently, and the technique of metaphyseal segment stripping must be applied, to avoid damaging the growth cartilage. Trochleoplasty is indicated in recurrent dislocation with concave or flat trochlea [12].

Interventions more common in children, such as reconstruction of the medial femoral ligament, or femoral and tibial osteotomies, cannot reconstruct the normal configuration of dysplastic trochlea, the essential factor of patellar instability. This is the main cause of relapse. Trochleoplasty, as the only method of treatment, provides the possibility for treatment of the most important factor for instability.

The diagnosis takes into account Dejour's classification, which describes 4 types of trochlear dysplasia A, B, C, D [13] depending on the depth of the trochlea, the crossing sign on the profile image and the presence of the supratrochlear spur.

Currently, the diagnosis is established after:

- The depth of the groove or trochlear groove, which must have

a value greater than 5.2 mm; when it is less than 3 mm it indicates dysplasia and has a specificity of 96% for diagnosis [14].

- the ratio between the length of the medial facet and the lateral one of the trochlea on a section at 3 cm of the articular interline; in a ratio of less than 40% is indicative of dysplasia.

- the lateral tilting of the trochlea is given by the angle formed by the line corresponding to the lateral face of the trochlea and the line parallel to the line drawn along the posterior femoral condyles; when this angle is less than 11 degrees, trochlear dysplasia is present.

Technical Principles: The femoral trochlea is highlighted by the lateral approaching of the knee.

An osteochondral flap is created up to the level of the intercondylar fossa. On the place of the trochlear groove, a subchondral bone block is delimited, in order to reconstruct an area corresponding to the new groove. For securing, holes are made with a high-speed drill and then securing is made using Vicryl 2 wires. The bone block is used to expand the lateral condyle, by placing it under the osteochondral flap to the proximal extension of the lateral femoral condyle by one cm.

Habitual dislocation

Habitual dislocation occurs at each flexion of the knee and is treated surgically similar to recurrent dislocation. The habitual patellar dislocation, as well as the congenital one, presents complex clinical modifications and a surgical challenge [15]. Warning! There is an important differentiation that requires a certain surgical approach. The quadriceps muscle is retracted and shortened, which is why it is necessary to lengthen the quadriceps tendon, so that the patella remains in contact with the trochlea and does not limit flexion, or cause recurrence, as a result of excessive tension in the quadriceps. The Payr technique is efficient and ensures the elongation of the Achilles tendon. Post-surgical complications that may occur consist of recurrent dislocation that occurs in 5% of cases and extension limitation in 2.5% of patients.

Chronic dislocation

The most common form of chronic dislocation is congenital patellar dislocation. In chronic dislocation, the retraction and shortening of the quadriceps is severe, the patella is placed on the lateral face of the femoral condyle and is never reduced. The treatment is exclusively surgical and, in order to ensure the reduction and stabilization of the patella, it is necessary to lengthen the quadriceps tendon or to lower the quadriceps, according to the Judet or Socolescu method. The Stanisavljevic method applied by some authors consists in the extensive release of the quadriceps, the folding of the medial parapatellar soft tissues, followed by the division of the patellar tendon and its realignment in the quadriceps and patella axis [15].

In chronic dislocation, after the realignment of the patella, the trochlea is remodeled. The angle of the trochlea and the angle of congruence tend towards normal values and avoid recurrence or subluxation of the patella [16].

Medial Patellar Dislocation

Medial patellar dislocation is a rare entity that occurs after recurrent subluxation of the operated patella, in which the relaxation of the lateral retinaculum has been applied. Miller reported 3 cases of medial dislocation after recurrent patellar subluxation diagnosed by CT images [17]. More common than medial dislocations are medial patellar subluxations. There are few reported cases of medial congenital

patellar dislocation. It is associated with multiple congenital defects [1]. I have encountered 3 cases of recurrent medial dislocations. Two children, in a boy suffering from rachitic dwarfism and a girl with dwarfism, in Larsen syndrome, who also had dislocated knees. The third case was a teenage girl with a solitary medial dislocation, followed by two episodes of recurrent medial dislocation.

The surgical intervention aims at the reconstruction of the lateral retinaculum, either through a patellar tendon graft reinserted on the Gerdy tubercles, or through a graft taken from the iliotibial tract and inserted on the lateral edge of the patella.

Alternating Lateral-Medial Patellar Dislocation

This dislocation is extremely rare. The patella deviates laterally in full extension and medially at knee flexion. This transposition occurs at each extension and flexion of the knee. The manual lateral and medial translation of the patella reveals the instability of the patella in both directions. Lateral dislocation in extension and medial in flexion is illustrated by recording the kinematics of extension and flexion on computerized 3D or MRI images. K. Masashi [2] describes a case of alternating lateral and medial dislocation, which they called recurrent lateral patellar dislocation and medial patellofemoral instability. The treatment consists in the simultaneous reconstruction of both medial patellofemoral ligaments.

References

1. Yazdi H, Monshizadeh S, Bozargi Z. Congenital medial dislocation of the patella with multiple congenital anomalies; case report and method of treatment. *J Pediatr Orthop B*. 2014;23(2):126-9.
2. Masashi K, Yoshinari T, Yasukazu Y, Kanamoto T, Shiozaki Y, Yamada Y. Simultaneous MPFL and LPFL reconstruction for recurrent patellar dislocation with medial patellofemoral instability. *Asia-Pacific J Sports*. 2014;1(1):42-46.
3. Fu K, Suan G, Liu C, Niu J, Wang F. Changes in femoral trochlear morphology following surgical correction of recurrent patellar dislocation associated with trochlear dysplasia in children. *Bone Joint J*. 2018;B(6):811-21.
4. Nelitz M, Dreyhaupc J, Williams SRM, Dormacher D. Combined supracondylar femoral derotation osteotomy and patellofemoral ligament reconstruction FOR recurrent patellar dislocation and severe femoral anteversion syndrome: Surgical technique and clinical outcome. *Int Orthop*. 2015;39(12):2355-62.
5. Kaise P, Schmoclz W, Schottle PB, Heinrichs C, Zwicrrina M, Attal R. Isolated medial patellofemoral ligament reconstruction for patella instability is insufficient for higher degrees of internal femoral torsion. *Knee Surg Sports Traumatol Arthrosc*. 2019;27:758-65.
6. Dewar RP, Hall JE. Recurrent dislocation of the patella. *J Bone Joint Surg Br*. 1957;39:798-802.
7. Marziani R. Sulla iussazione della rotula e sul suo trattamento operativo. *Arch orthop*. 1930;46:797-801.
8. Green WT: Recurrent dislocation of the patella: Its surgical correction in the Groningen child. *J Bone Joint Surg Am* 1965;47:1670-676.
9. Baksi DP. Pes anserinus transposition for patellar dislocations: Long-term follow-up results. *J Bone Joint Surg Br*. 1993;75(2):305-401.
10. Matthews J, Schranz P. Reconstruction of the medial patellofemoral ligament using a longitudinal patellar tunnel technique-a review of twenty-five cases. *J Bone Joint Surg*. 2011;93:47-52.
11. Herring JA. Tachdjian's Pediatric Orthopaedics. Fourth Edition. 2008.
12. Hoiat Z, Case JL. Patella dislocation. In: StatPearls TreasureIsland (FL): Stat Pearls Publishing. 2020. [Internet]
13. Kazley J, Banerjee S. Classifications in brief: The Dejour classification of trochlear dysplasia. *CI Orthop and Relat Research*. 2019;477(10):2380-386.
14. Ballehr OL. Transient lateral patellar dislocation. *MRI Web Clinic*. 2013.
15. Sever R, Fishkin M, Hemo Y, Wientroub S, Yaniv M. Surgical treatment of congenital and obligatory dislocation of the patella in children. *J of Pediatr Orthop*. 2019;39(8):436-40.
16. Sugimoto D, Cristina M, Micheli L. Effects of surgical intervention on trochlear remodeling in pediatric patients with recurrent patella dislocation cases. *J of Pediatr Orthop B*. 2016;25(4):349-53.
17. Miller PR, Klein RM, Teitge RA. Medial dislocation of the patella. *Skeletal radiology*. 1991;20(6):429-31.