



## Partial Splenectomy for a Large Cavernous Hemangioma: Case Report and Literature Review

Hatim Lazaar\*, Yosra Malki, Abderrahman Atmani, Tariq Bouhout, Badr Serji and Tijani El Harroudi

Department of Surgical Oncology, Regional Oncology Center, Mohammed VI University Hospital, Morocco

### Abstract

The recent awareness of the spleen's important role, especially its immune function, has fundamentally changed the management of splenic diseases, promoting the splenic preserving surgery, and protecting from the significant risk of total splenectomy: Overwhelming post-splenectomy sepsis. The Partial splenectomy is a safe and feasible technique that offers, according to the literature, the same results of a total approach, either in achieving hematological benefits in congenital hemolytic anemia, or treating the focal splenic lesion such as hemangioma, while preserving the immune function.

**Keywords:** Partial splenectomy; Cavernous splenic hemangioma; Hereditary spherocytosis; Overwhelming post-splenectomy sepsis; Crush-clamp

### Introduction

The spleen is the largest secondary lymphoid organ; it has numerous immune response roles, including the clearance of affected or damaged cells from the bloodstream and host resistance to infection [1].

With this recent awareness of its importance and to prevent the overwhelming post-splenectomy infection, the therapeutic strategy of the splenic affections has fundamentally changed. It has led to preserve the spleen, either with the nonoperative management of the splenic trauma or the partial splenectomy.

Here we describe a partial splenectomy by laparotomy to a 70 years old woman with cavernous splenic hemangioma.

### Case Presentation and Method

A 70 years old female without a past medical story was admitted with chronic pain in the left upper quadrant, the clinical examination was poor, and blood tests were normal. Computed Tomography (CT) scan revealed typical imaging features of a splenic hemangioma (Figure 1). We did not administer a vaccine before surgery, and the patient underwent an open partial splenectomy after the ligation of segmental vessels at the hilum.

#### The surgical procedure:

The patient was admitted to the operating room in a supine position; a left subcostal incision of about 15 cm was performed, the first step was transection of the ligamentous attachments, including the splenocolic and splenorenal ligaments at the inferior pole, the gastrosplenic omentum was opened, and short vessels were severed between ligatures, the tail of the pancreas was embedded in the splenic hilum, we decided to make a lateral-posterior approach in order to mobilize the spleen and avoid wounds or lacerations of the pancreatic tail, then ligation of the inferior lobar artery and vein intended for the inferior pole of the spleen.

The ischemic area was created (Figure 2), and we started the dissection of the splenic parenchyma using the crush-clamp technique with Kelly to fracture the parenchyma and expose the vessels, along the demarcation line, with bipolar coagulation (Figure 3A and 3B).

The peritoneal cavity was washed abundantly with warm saline serum, and short drainage of 48 h was done.

The patient was put on analgesics and antibiotic therapy for five days, with discharge on the 5<sup>th</sup>

### OPEN ACCESS

#### \*Correspondence:

Hatim Lazaar, Department of Surgical Oncology, Regional Oncology Center, Mohammed VI University Hospital, Oujda, Morocco, E-mail: hatimrwn09@gmail.com

Received Date: 11 Jan 2021

Accepted Date: 03 Feb 2021

Published Date: 12 Feb 2021

#### Citation:

Lazaar H, Malki Y, Atmani A, Bouhout T, Serji B, El Harroudi T. Partial Splenectomy for a Large Cavernous Hemangioma: Case Report and Literature Review. *Clin Surg.* 2021; 6: 3074.

**Copyright** © 2021 Hatim Lazaar. This is an open access article distributed under the Creative Commons Attribution License, which permits unrestricted use, distribution, and reproduction in any medium, provided the original work is properly cited.

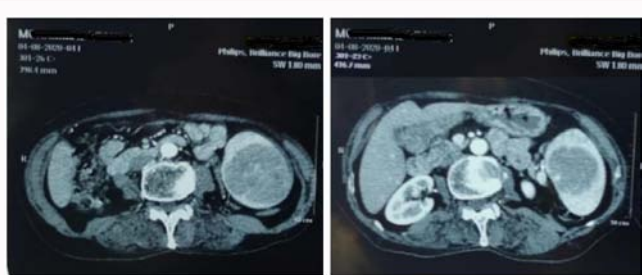


Figure 1: CT scan imaging revealing an inferior splenic hemangioma.

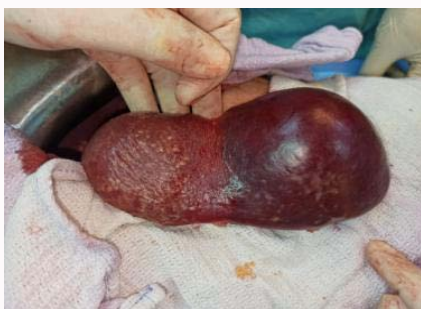

Figure 2: The ischemic area created after the ligation of the inferior splenic vessels.

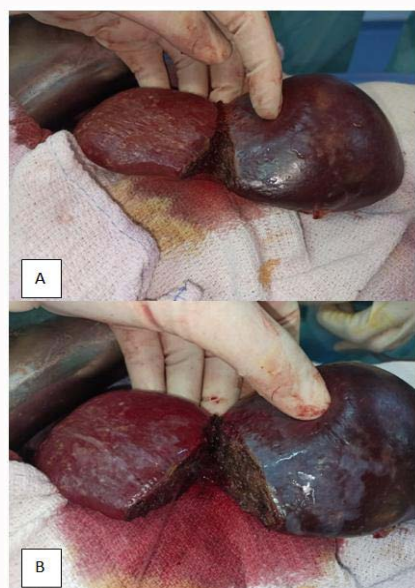


Figure 3A and 3B: dissection of the splenic parenchyma using the crush-clamp technique.

day.

Two weeks after surgery, a vaccination was administered with prophylactic antibiotics for at least two years.

The anatomopathological examination confirmed the splenic hemangioma showing anon-encapsulated non-neoplastic vascular channels, with vessels lined with a single layer endothelium (Figure 4A and 4B).

### Discussion

The spleen is the largest secondary lymphoid organ, and because of its anatomical, histological architecture and its direct connection

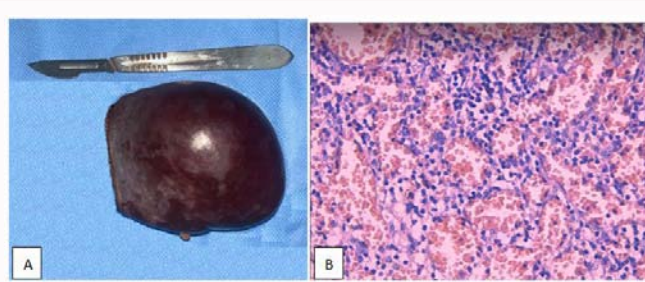


Figure 4: 4A: Partial splenectomy with the resected splenic cavernous hemangioma. 4B: Anatomopathology examination: Non-encapsulated non-neoplastic vascular channels, with vessels lined with a single layer endothelium.

to the bloodstream, that confers a dual capacity to trap antigen and activate a rapid humoral immune response to provide the necessary opsonizing antibody for optimal bacterial clearance [1]. The discovery of the spleen's essential immunologic functions considerably changed the surgical strategy in splenic surgery; total splenectomy leaved room for the development of spleen sparing techniques and promote splenic-preserving surgery, To prevent overwhelming post-splenectomy sepsis and severe infections [2].

Splenic Hemangioma (SH) is the second commonest focal lesion involving the spleen after simple splenic cysts and the most common benign primary neoplasm of the spleen; it is described as a splenic slow flow venous malformations. Most SH is discovered incidentally and commonly in the second and third decade of life. The potential of malignant degeneration to an angiosarcoma is unknown; the reason why only symptomatic SH or large ones are treated due to increased risk of rupture. Many therapeutic options are possible; splenectomy either by laparotomy or laparoscopy remains the best one [3].

The first successful partial splenectomy *via* the open approach was reported in 1980 by Morgenstern and Shapiro. The same procedure was performed *via* laparoscopy in 1995 by Uranues [4,5].

Partial splenectomy is a therapeutic option that is gaining more and more place in the approach of focal splenic tumors or benign primary lesions such as cysts and hamartomas and hematological disease such as hereditary spherocytosis [6]. Besides, thanks to technological advances of instruments and laparoscopic surgery techniques, the laparoscopic approach in splenectomy has proven the superiority upon the open approach, considering it as a gold standard, especially with the advantages in postoperative pain control and decreased length of stay [4,5,7]. Moreover, as indicated in a systematic review of 2130 cases of Renato Costi, the number of laparoscopic approaches had considerably increased since 2006, which was translated in the notable rise in published papers [4].

However, many studies report that laparoscopic partial splenectomy benefits may not be as apparent as total splenectomy. Resulting in longer operative time, extended hospitalization, and more postoperative pain [4], which is a consequence of increased remaining blood in the peritoneal cavity.

Many surgical indications were suggested by Uranues in his paper, either for a therapeutic purpose such as benign tumors or splenic cyst, or diagnostic one such as splenomegaly for unknown origin or a non-traumatic accidental laceration is made [8].

Furthermore, recent papers suggest that partial splenectomy,

and especially with the laparoscopic approach, is a safe and feasible technique for children with hematologic splenic diseases such as hereditary spherocytosis, and achieve hematologic benefits with less postoperative pain and length of stay as shown previously [4,7,9]. Preoperative preparation for a partial splenectomy is the same as for a total splenectomy, consisting of a presurgical immunization usually with polyvalent pneumococcal vaccine, meningococcal vaccine, *H. influenzae* type b vaccine, and also antibiotic prophylaxis is recommended at least one week before surgery, and if not they can be given 1 or 2 weeks after.

The technique is based on the ligation of segmental vessels at the hilum, leading to a selective devascularization of splenic parenchyma, as shown in the figure. This ischemic area is transected along the demarcation line [4], ensuring that leaving at least 25% of the spleen with sufficient perfusion to preserve its immune function [6].

The conversion risk from laparoscopy to laparotomy is 6.4%, While the conversion from partial to total splenectomy was 3.4% in the systematic review mentioned earlier [4]. According to the literature, this topic's major drawback is the inherent limitations of retrospective studies, small sample sizes, and the lack of consensus. However, most papers confirm that partial splenectomy may be the new alternative to total splenectomy whenever possible.

## Conclusion

Partial splenectomy, and especially with the laparoscopic approach, is the new technique that is gaining more place in the two last decades, with the comprehension of the anatomy and physiology of the spleen on one hand, and the permanent enhancements of laparoscopic instruments and techniques on the other, the preservation of the immune function of the spleen has become mandatory, offering the same hematologic and therapeutic results, with fewer risks of overwhelming post-splenectomy infection.

## References

1. MO Dailey. The immune functions of the spleen, in the complete spleen: Structure, function, and clinical disorders. Bowdler AJ, editor. Totowa, NJ: Humana Press, 2002;51-69.
2. Liu DL, Xia S, Xu W, Ye Q, Gao Y, Qian J. Anatomy of vasculature of 850 spleen specimens and its application in partial splenectomy. *Surgery*. 1996;119(1):27-33.
3. Islam S, Newman EA, Strouse PJ. Antiangiogenic therapy for a large splenic hemangioma. *Ped Surgery Int*. 2005;21:1007-10.
4. Costi R, Castro Ruiz C, Romboli A. Partial splenectomy: Who, when and how. A systematic review of the 2130 published cases. *J Pediatr Surg*. 2019;54(8):1527-38.
5. Lee SH, Lee JS, Yoon YC. Role of laparoscopic partial splenectomy for tumorous lesions of the spleen. *J Gastrointest Surg*. 2015;19:1052-8.
6. Wang X, Wang M, Zhang H. Laparoscopic partial splenectomy is safe and effective in patients with focal benign splenic lesion. *Surg Endosc*. 2014;28(12):3273-8.
7. Englum BR, Rothman J, Leonard S. Hematologic outcomes after total splenectomy and partial splenectomy for congenital hemolytic anemia. *J Pediatr Surg*. 2016;51(1):122-7.
8. Uranues S, Alimoglu O. Laparoscopic surgery of the spleen. *Surg Clin North Am*. 2005;85(1):75-90.
9. Morinis J, Dutta S, Blanchette V. Laparoscopic partial vs. total splenectomy in children with hereditary spherocytosis. *J Pediatr Surg*. 2008;43(9):1649-52.