



Parathyroid Glands - A Sacrosanct During Thyroidectomy

Prazwal Shrestha, Pirabu Sakthivel*, Kuldeep Thakur, Kapil Sikka, Chirom Amit Singh and Rajeev Kumar

Department of Otorhinolaryngology & Head and Neck Surgery, All India Institute of Medical Sciences, India

Abstract

Understanding parathyroid gland anatomy and intraoperative attention to detail facilitates the identification of normal parathyroids during thyroidectomies. Parathyroid glands can be seen as distinct from surrounding neck tissues and thyroid gland through recognition of a number of different characteristics, which are critical for every thyroid surgeon to know. Herein we describe the normal characteristics of parathyroid gland and surrounding anatomical structures to aid in easy identification.

Keywords: Thyroidectomy; Parathyroid gland; Recurrent laryngeal nerve

Introduction

Humans typically have four parathyroid glands. True supernumerary glands occur in only 5% of cases. Knowing the anatomical position and vascular supply of the PGs is essential to avoid hypoparathyroidism after thyroid surgery. Rates of permanent hypoparathyroidism after bilateral thyroid surgery even by experienced surgeons range from 1.2% to 6.5% [1]. It is imperative to know the variable location, size, shape and color of normal parathyroid glands.

Location

The inferior parathyroid gland has a longer and more variable migration path in the neck than the superior gland as it derives from third pharyngeal arch. The normal inferior parathyroid gland typically rests very close (within 1 cm) inferiorly, laterally, or posteriorly to the inferior pole of the thyroid in about 50% of cases and 25% in thyrotoxic horn, which lies directly beneath strap muscles [2].

OPEN ACCESS

*Correspondence:

Pirabu Sakthivel, Department of Otorhinolaryngology & Head-Neck Surgery, All India Institute of Medical Sciences, New Delhi, 110029, India, Tel: 9958744547; E-mail: pirabusakthivel@gmail.com

Received Date: 27 Nov 2019

Accepted Date: 30 Dec 2019

Published Date: 08 Jan 2020

Citation:

Shrestha P, Sakthivel P, Thakur K, Sikka K, Amit Singh C, Kumar R. Parathyroid Glands - A Sacrosanct During Thyroidectomy. Clin Surg. 2020; 5: 2701.

Copyright © 2020 Pirabu Sakthivel.

This is an open access article distributed under the Creative Commons Attribution License, which permits unrestricted use, distribution, and reproduction in any medium, provided the original work is properly cited.

Embryologically, as the inferior parathyroid relates to the thymus, so the superior parathyroid relates to the lateral thyroid anlage/C-cell complex. The migration path of the superior parathyroid is shorter, and as a result the rates of ectopia are lower than for the inferior parathyroid. The characteristic location of the normal superior parathyroid is at the cricothyroid junction. The superior parathyroid occurs here in 80% of cases [2]. At this level in the neck, the superior parathyroid is most commonly closely associated with the posterolateral surface of the upper half of the thyroid. The superior parathyroid is often associated with a lobule of fat and may be hidden by a layer of perithyroidal fascia, binding it to the posterolateral aspect of the thyroid. These fascial layers, which blend the lateral aspect of the thyroid to the adjacent inferior constrictor musculature, need to be meticulously dissected away from the thyroid capsule to reveal the superior parathyroid. In this location the superior parathyroid is deep (i.e. dorsal) to the plane of the RLN, but it may be directly adjacent to the nerve's entry point into the larynx. As the ligament of Berry is dissected in the distal most course of the RLN, the superior parathyroid may be revealed. In this region, the superior parathyroid may be initially obscured by a variably present nubbin of thyroid tissue, termed the Zuckerkandl tubercle (Figure 1).

The color of the parathyroid gland is typically light brown to reddish tan and is often described as mahogany. This color relates to the fat content, vascularity, and percent of oxyphil cells.

In infants younger than 3 months of age, the normal parathyroid gland looks grayish and semi-translucent. In children the normal parathyroid gland, which has scant fat, is darker (a pinkish brown) compared with that of adults. As a result, they assume a more yellowish color, which is only slightly different from surrounding fat. In obese persons, the fat content of parathyroid glands is higher. As a result, they assume a more yellowish color, which is only slightly different from surrounding fat. Fat, in contrast, is usually bright yellow (Figure 1). This creates problem in identification in adults and in obese patients based on appearance only. Intraoperative tests based on differential tissue density have been used in the past. Fat floats in saline solution, and parathyroid

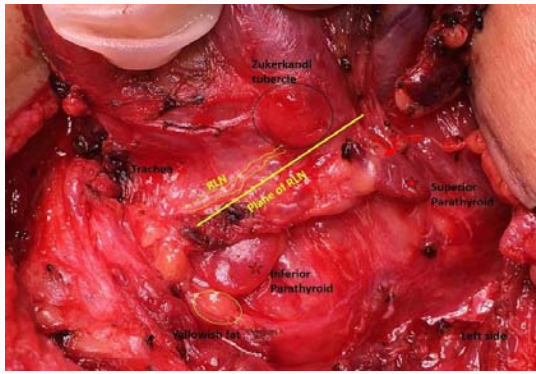


Figure 1: Surgical image after lateral rotation of left thyroid lobe depicting Zukerkandl tubercle (black circle), both superior and inferior parathyroid (red star), vascular hilum (red arrow), yellowish fat (yellow circle), recurrent laryngeal nerve and its plane (yellow line).

tissue usually sinks [2].

The thyroid is firmer and mottled reddish brown and can be easily distinguished from parathyroids. However, the Zukerkandl tubercle can create confusion because of its location close to superior parathyroid and lateral projection. Especially during surgery slight bleeding makes the surgical field distorted resulting in difficulties on relying on color of parathyroids.

Small metastatic lymph node mimics parathyroid gland. Nodes vary from gray to tan to red and are generally firmer than parathyroid glands. However, even in experienced hands a frozen section analysis is required to solve the dilemma.

Parathyroid glands also have a distinct hilar vessel (a “vascular strip”, red arrow Figure 1) that can be seen if surrounding fat does not obscure its hilum. The parathyroid gland has a discrete, encapsulated, smooth surface as opposed to the more lobular surface of the thyroid and the more mottled, pitted surface of lymph nodes. The parathyroid gland is softer to palpation than thyroid or nodal tissue.

Parathyroid shape is also unique and most often leaf-like or beanlike whereas a lymph node will be oval or circular. Normal parathyroid glands are usually 5 mm to 6 mm in diameter whereas lymph nodes vary in size. The dissection of a small nodule on the surface of the thyroid gland mistaken for a parathyroid gland results in hemorrhage, whereas the dissection of a parathyroid gland closely related to the thyroid capsule does not result in significant hemorrhage especially when performed with meticulous loupe-assisted dissection.

The most important distinguishing feature is that the parathyroid, being a discrete, encapsulated organ, has a characteristic motion when surrounding fat is gently manipulated which is known as “gliding sign”, which helps in easy identification.

Parathyroids and recurrent laryngeal nerve [RLN]

A very important clue in finding parathyroid glands and in differentiating upper from lower glands is the position of the

parathyroid gland relative to the RLN. If the RLN’s path in the neck is taken as a coronal plane, the upper parathyroid glands are dorsal (i.e., deeper in the neck) and the lower parathyroid glands are ventral (i.e. more superficial in the neck) to this plane (Figure 1). The relationship of the parathyroid gland to the RLN appears to be more constant than the relationship between the gland and the position of the inferior thyroid artery [2]. Hence it is prudent to identify RLN in its course to preserve parathyroids.

Blood supply

The superior parathyroid gland is usually vascularized by the inferior thyroid artery or by an anastomotic branch between the inferior thyroid and the superior thyroid artery or by the posterior branch of the superior thyroid artery. The inferior parathyroid gland is vascularized by inferior thyroid artery. It is of paramount importance to preserve the vascular supply and hilum of parathyroid gland to prevent vascular compromise which is indicated by change in color of parathyroid (note color change in superior compared to inferior parathyroid Figure 1).

Technical notes to preserve parathyroid glands

Consider loupe assisted bloodless dissection to discern subtle clues for parathyroid and neural identification. The surgeon should have a low threshold to identify the RLN. Identifying the nerve helps in avoiding injury to the nerve and in differentiating inferior from superior parathyroid glands.

Conclusion

To preserve parathyroid glands, surgeons have to know well about their embryology and anatomy. The parathyroid glands vary in number, size, shape, and color. The upper parathyroid glands are dorsal and the lower parathyroid glands are ventral to the coronal plane of recurrent laryngeal nerve. Both the superior and inferior parathyroid glands most frequently receive blood supply from the inferior thyroid artery. Parathyroid exploration requires a meticulous and bloodless dissection with help of surgical loupes. If the parathyroid gland is clearly devascularized or turns deep black, it should be biopsied, confirmed as normal parathyroid tissue, and reimplanted.

References

1. Schroder DM, Chambors A, France CJ. Operative strategy for thyroid cancer. Is total thyroidectomy worth the price? *Cancer*. 1986;58(10):2320–8.
2. Randolph GW, editor. *Surgery of the Thyroid and Parathyroid Glands*. 2nd ed. Philadelphia, PA: Elsevier Saunders; 2012.