



# Paranasal *Aspergillus* Fungal Infection in Immune Compromised and Uncontrolled Diabetic Patients: A Report of 5 Cases along with Review of Literature

Harish Saluja<sup>1\*</sup>, B M Rudagi<sup>1</sup>, Shivani Sachdeva<sup>2</sup>, Semmit Shah<sup>1</sup>, Anuj Dadhich<sup>1</sup>, Parul Tandon<sup>1</sup> and Vinayak More<sup>1</sup>

<sup>1</sup>Department of Oral & Maxillofacial Surgery, Rural Dental College, India

<sup>2</sup>Department of Periodontics, Rural Dental College, India

## Abstract

*Aspergillus* is the most common fungal pathogen in sinus disease, with the maxillary sinus being predominantly involved. Fungal infections are common in several conditions that lower the immunity of the patient like uncontrolled diabetes, long term antibiotic & steroid therapy, radio, chemotherapy, immunosuppressive treatment & immunodeficient diseases. Among these diabetes is the condition which is increasing day by day in India and is one of the predisposing factor for head & neck fungal infection especially *aspergillus* fungal infection. Diabetes has emerged as a major healthcare problem in India. According to Diabetes Atlas published by the International Diabetes Federation (IDF), there were an estimated 40 million persons with diabetes in India in 2007 and this number is predicted to rise to almost 70 million people by 2025. The countries with the largest number of diabetic people will be India, China and USA by 2030. Here we present 5 cases of invasive *aspergillus* fungal infection of paranasal sinus region in uncontrolled diabetic patients, along with review of literature emphasizing much more incidence of *aspergillus* infection in facial region in patients suffering from uncontrolled diabetes. This review will help us in better understanding of maxillary sinus fungal infections.

## OPEN ACCESS

### \*Correspondence:

Harish Saluja, Department of Oral & Maxillofacial Surgery, Rural Dental College, Loni Tal, Rahata, Ahmednagar, Maharashtra – 413736, India, Tel: 09766921178;

E-mail: harry\_saluja@yahoo.co.in

Received Date: 11 Oct 2017

Accepted Date: 30 Nov 2017

Published Date: 06 Dec 2017

### Citation:

Saluja H, Rudagi BM, Sachdeva S, Shah S, Dadhich A, Tandon P, et al. Paranasal *Aspergillus* Fungal Infection in Immune Compromised and Uncontrolled Diabetic Patients: A Report of 5 Cases along with Review of Literature. Clin Surg. 2017; 2: 1805.

Copyright © 2017 Harish Saluja. This is an open access article distributed under the Creative Commons Attribution License, which permits unrestricted use, distribution, and reproduction in any medium, provided the original work is properly cited.

Keywords: Diabetes; Fungal infection; Aspergillosis; Paranasal; Maxillary sinus

## Introduction

Head & Neck aspergillosis, particularly of the maxillary antrum, has been reported as occurring in both healthy and immunologically compromised individuals. It is one of the most rapidly progressing and lethal form of infection. Aspergillosis occur in both invasive and noninvasive forms, the former is more likely to occur in patients with debilitating illnesses and is a major cause of morbidity & mortality in immunocompromised patients [1,2]. In the immunocompromised patient, infection mortality has risen to 50% in many institutions [3]. Fungal infections are common in several conditions that lower the immunity of the patient like uncontrolled diabetes, long term antibiotic & steroid therapy, radio, chemotherapy, immunosuppressive treatment & immunodeficient diseases [4]. Among these diabetes is the condition which is increasing day by day in India and is one of the predisposing factor for head & neck fungal infection especially *aspergillus* fungal infection. Diabetes has emerged as a major healthcare problem in India. According to Diabetes Atlas published by the International Diabetes Federation (IDF), there were an estimated 40 million persons with diabetes in India in 2007 and this number is predicted to rise to almost 70 million people by 2025. The countries with the largest number of diabetic people will be India, China and USA by 2030 [5,6]. Here we present 5 cases of *aspergillus* fungal infection of paranasal sinus region in diabetic patients, along with review of literature emphasizing much more incidence of *aspergillus* infection in facial region in diabetic patients.

## Case Presentations

**Case 1:** A of 70 year-old male known case of diabetes, reported with chief complaint of pain in left maxillary posterior region since last 6 months, nasal congestion, headache & numbness on upper lip region since last 2 months. Intraoral examination showed edentulous necrotic bone involving hard palate & upper alveolus completely on left side & up to premolar region of right side measuring approximately 8 cm in length. Even some perforations were also present in palate (Figure 1).

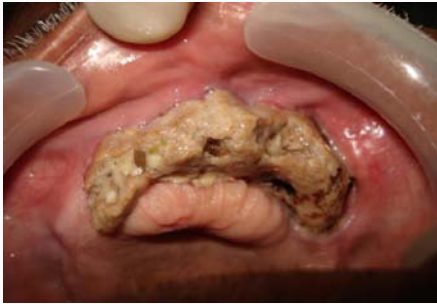

Figure 1: Preoperative intraoral photograph of case 1.

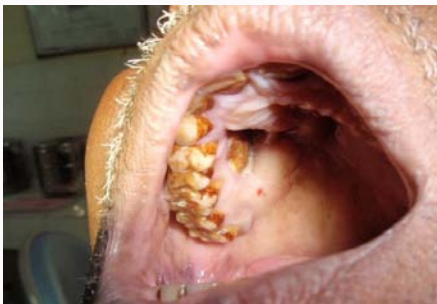

Figure 2: Preoperative intraoral photograph of case 2.

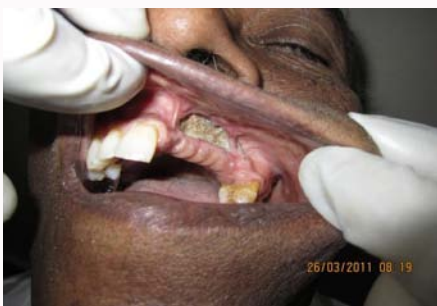

Figure 3: Preoperative intraoral photograph of case 3.

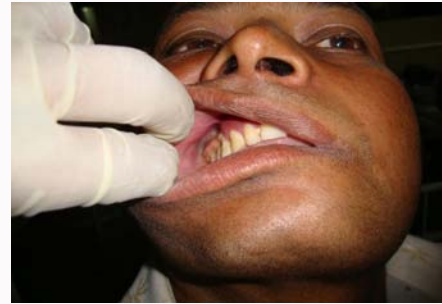

Figure 4: Preoperative intraoral photograph of case 4.

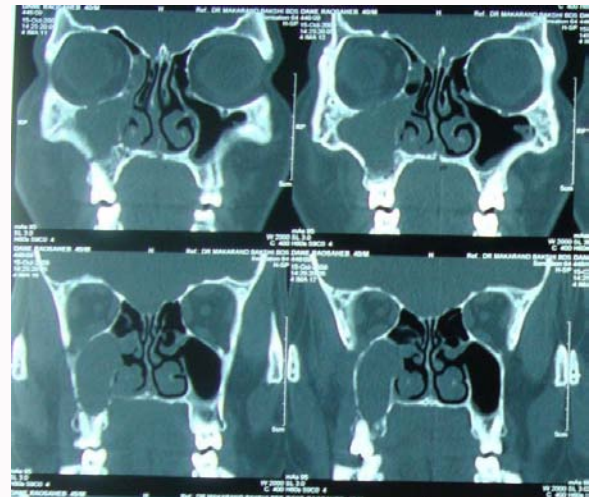


Figure 5: CT scan showing involvement of right maxillary sinus & right upper alveolus of case 4.

Radiologic examination revealed obliteration of left maxillary sinus showing involvement of left pre-maxilla region with extension into left maxillary sinus & left Zygomatic region. Lateral wall of left side maxillary sinus was completely eroded. The radiologic appearance of the paranasal sinus is a focal radio dense shadow in the sinus. The clinical & radiological diagnosis was invasive fungal infection & same was confirmed as *Aspergillus* in histology. Patient sugar levels were controlled & the patient was operated for surgical debridement & curettage of necrotic bone. Whole of the necrotic palate was detached from surrounding attachments & removed. Curettage was done up to left Zygomatic arch region, lining of the sinus was removed completely, even some part of Zygomatic bone was curetted out. The operated area was irrigated with combination of Amphotericin powder & normal saline. Patient was kept on injection Amphotericin B 25 mg in 500 cc of saline twice along with antibiotics for next 5 days & the blood urea & creatinine levels were monitored regularly. From 6<sup>th</sup> post operative day patient was shifted to tablet Fluconazole 150 mg OD. At the same time operated site was irrigated twice daily with normal saline mixed with Amphotericin powder. After 6 months oral rehabilitation was done with obturator cum complete denture prosthesis to improve quality of patient's life.

**Case 2:** This case was of 40 year male patient reporting with complaint of swelling on right side of face & upper posterior mobile teeth since last 4 months. On intraoral examination exposed alveolar bone was there in right maxillary posterior region with pus discharge from the same site (Figure 2). Patient was a known case of uncontrolled diabetes since last 3 years & was not taking any medication. Histopathological diagnosis for the lesion was aspergillosis & lesion was also involving maxillary sinus. After sugar control complete lesion was curetted from maxillary sinus along with necrotic alveolar part, under general anesthesia. Postoperatively patient was managed by systemic antifungal drugs.

**Cases 3-5:** They were also diabetic patients & suffered from *aspergillus* fungal infection of paranasal sinus region (Figures 3-7). These three patients were suspected of odontogenic origin. All 3 patients were managed surgically along with postoperative systemic antifungal therapy and treatment for the odontogenic infection was also given.

## Discussion

Mycosis of paranasal sinus has become a more common disease [7]. Of all the fungal infections aspergillosis is third commonest fungal disease in human beings. *Aspergillus* is the most common fungal pathogen in sinus disease, with the maxillary sinus being predominantly involved. The recent rise in mycotic nasal & paranasal infections is due to both improved diagnostic research and an increase of the conditions that favour fungal infections, which increase in immunocompromised patients because of changing life

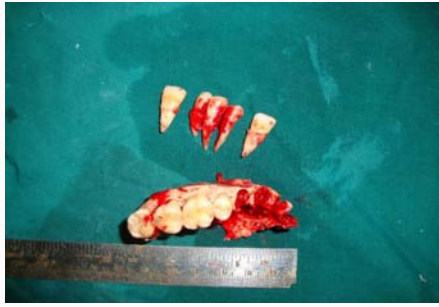

Figure 6: Resected specimen of case 4.

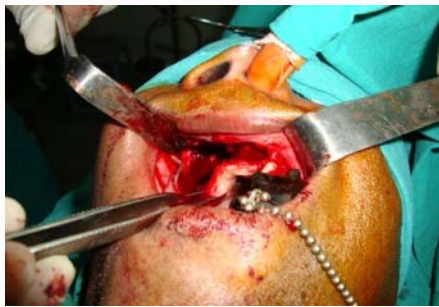

Figure 7: Intraoral view after resection of specimen.

styles etc [8,9]. The priest Botanist Micheli first described *Aspergillois* (1729) [10]. In 1847 Sluyter first identified *Aspergillus* in a woman dying of pulmonary infection [11]. First report of involvement of maxilla was by Morrel Mackenzie (1893) while Zorinko (1893) [12] described maxillary sinus infection. The causative organism is mainly spore forming filamentous fungus which occurs as a saprophyte in soil, mud on seeds, fruit, grain seeds & plants. These colonies grow in a wide range and can grow in temperature up to 50°C [13]. There are several species of *aspergillus* which are associated with human diseases but *Aspergillus fumigates* & *Aspergillus flavus* being most dominant. *A. flavus* is most destructive one because of potent toxins [13]. Other reason for its growth was hypoxia & anaerobic conditions because of sinus obstruction. The fungus itself does not contain any chlorophyll & therefore does not require any light for growth but it needs host supplying it with nutrient in the form of glucose, nitrogen, sulphur, phosphorous, potassium, calcium, magnesium and iron [14]. *Aspergillus* in sinus appears as a Ball shaped mass which contains Ca & P salts & therefore may sometimes mimics foreign body on radiographs [14]. The etiopathogenesis of paranasal fungal infection is a debatable topic, but there are three main accepted theories including odontogenic, aerogenic, and mixed origins. The odontogenic school of thought maintains that the pathogenesis is based on an initial colonization of the maxillary sinus by means of iatrogenic oral-antral communication. This theory holds that the Zinc Oxide which can be found in endodontic sealers paralyzes the epithelial cilia or causes edema and hyperemia of soft tissue, affecting Schneiderian membrane epithelial function [15]. *Aspergillus* of paranasal sinus occurs in 2 forms, noninvasive and invasive [4]. The first or noninvasive, type reassembles chronic bacterial sinusitis with symptoms of unilateral nasal obstruction, pressure feelings and drainage of foul, gelatinous substance. Radio graphically usually documents only a single cloudy sinus. The invasive type is more aggressive with signs of malignancy. This type might extend to the orbit, cheek or adjacent sinus & may cause displacement or

bony erosion [4]. The invasive type is mostly associated with some immunocompromised condition. Hora differentiated *Aspergillus* as infiltrating and non-infiltrating with incidence of bone invasion as the primary difference [16]. At our institute during a period of 3 years from 2008-2011 we encounter 5 *aspergillus* patients involving paranasal area & all the patients were suffering from long standing diabetes. Literature also shows patients suffering from diabetes are the main victims.

Involvement of paranasal sinuses may result in mucoid or purulent nasal discharge, facial swelling, pain, tenderness, and fever, proptosis of eye, sensory nerve disturbances, and epistaxis. In some cases even sphenoid sinus also got involved and sometimes fungus invade the orbit and optic nerve from the sphenoid sinus. A fatality rate of 16% has been reported in medical literature for uncontrolled fungal infections [3]. Schubert et al. reported fatal hemorrhage in paranasal *aspergillus* patient [17]. This fungus invades the arteries, form thrombi with in blood vessel and cause necrosis of hard & soft tissues. Thrombosis of the internal maxillary artery or descending palatine artery from a fungal infection could result in necrosis of a portion of the maxilla. After entering the vessels; fungus can sometimes involve sinuses & orbit [18]. Uncontrolled diabetes mellitus can alter the normal immunologic response of patient to infections. In these types of patients because of decreased granulocytic count phagocytic ability becomes low with altered polymorph nuclear response [18]. Diabetes mellitus is a chronic disorder that affects a large segment of human population & is a major health problem. Immunologic research demonstrated several defects in host immune defense mechanism in diabetic subjects. Phagocytic capabilities of PMN are adversely affected by hyperglycemia in rat module. Several PMN defects occur in diabetic subjects, including impaired migration, phagocytosis, intracellular killing & chemotaxis, which may be due to decreased PMN membrane fluidity. Generalised immunologic defects such as those raise the suspicion that diabetic patients may be at an overall increased risk of infection [19]. Invasive mycotic infections present a problem in therapy but have a fairly good prognosis if treated with radical local surgery along with control of underlying disease. In our all 5 cases surgical debridement was done and along with this patient was on systemic antifungal therapy and even in one case antifungal was used for local delivery to operating area.

## Conclusion

Diabetic patients are more prone to paranasal fungal sinus infections, in which one of the main etiology can be of odontogenic origin, so dental problems should be considered seriously in diabetic patients as these can turn up into these types of sequels. Diabetic or any immunocompromised patient having necrosed and exposed maxillary bone with tooth extraction history in the same region should alert a clinician possibility of some fungal infection.

Three principles should be followed to treat diabetic patients having paranasal fungal infections.

Firstly, control the underlying diabetes by suitable measures. Secondly, remove affected bone along with sinus membrane. Lastly Systemic use of antifungal drugs, even some times antifungal drugs can be used for local irrigation to the affected area.

## References

1. Napoli JA, Donegan JO. Aspergillois and necrosis of the maxilla: a case report. J Oral Maxillofac Surg. 1991;49(5):532-4.

2. Meikle D, Yarrington CT Jr, Winterbauer RH. Aspergillosis of the maxillary sinus in otherwise healthy patients. *Laryngoscope*. 1985;95(7):776-9.
3. Shannon MT, Sclaroff A, Colm JS. Invasive aspergillosis of the maxilla in an immunocompromised patient. *Oral Surg Oral Med Oral Pathol*. 1990;70(4):425-7.
4. Sharada DM, Arunkumar G, Vandana KE, Rao PS. Sino-orbital aspergillosis in a diabetic patient. *Indian J Med Microbiol*. 2006;24(2):138-40.
5. Sicree R. Diabetes and impaired glucose tolerance in India. *Diabetes Atlas*. 2006;15-109.
6. Joshi SR. Indian diabetes risk score. *JAPI*. 2005;53:755-7.
7. Singhall SK, Dass A, Singh GB, Punia RPS, Nagarkar NM. Destructive Aspergillosis. *Indian J Otolaryngol Head Neck Surg*. 2005;57(3):244-6.
8. Beck-Manngeta J, Necek D. Radiologic findings in aspergillosis of the maxillary sinus. *Oral Surg Oral Med Oral Pathol*. 1986;62(3):345-9.
9. Krennmair G, Lenglinger F. Maxillary sinus aspergillosis: diagnosis and differentiation of the pathogenesis based on computed tomography densitometry of sinus concretions. *J Oral Maxillofac Surg*. 1995;53(6):657-63.
10. Robb PJ. Aspergillosis of the paranasal sinuses: a case report and historical perspective. *J Laryngol Otol*. 1986;100(9):1071-7.
11. Hinson KFW, Moon AJ, Plummer NS. Brochno pulmonary aspergillosis. *Thorax*. 1952;7(4):317-33.
12. Zarniko C. Aspergillus mycosis of the jaw. *DMW*. 1891;17(44):1222.
13. Romett JL, Newman RK. Aspergillosis of the nose and paranasal sinuses. *Laryngoscope*. 1982;92(7):764-6.
14. Rossouw DP, Swart JG. Aspergillus fumigatus infection of the maxillary sinus. A case report. *S Afr Med J* 1988;73(1):47-8.
15. Costa F, Polini F, Zerman N, Robiony M, Toro C, Politi M. Surgical treatment of Aspergillus mycetomas of the maxillary sinus: review of the literature. *Oral Surg Oral Med Oral Pathol Oral Radiol Endod*. 2007;103(6):e23-9.
16. Titche LL. Aspergillosis of the maxillary sinus. *Ear Nose Throat J*. 1978;57:62-6.
17. Schubert MM, Peterson DE, Meyers JD, Hackman R, Thomas ED. Head and neck aspergillosis in patients undergoing bone marrow transplantation. Report of four cases and review of the literature. *Cancer*. 1986;57(6):1092-6.
18. Pogrel MA, Miller CE. A case of maxillary necrosis. *J Oral Maxillofac Surg*. 2003;61(4):489-93.
19. Auluck A. Maxillary necrosis by mucormycosis. A case report and literature re view. *Med Oral Patol Oral Cir Bucal*. 2007;12(5):e360-4.