



## Oncological Skull Base Reconstruction with Microvascular Tissue Transplantation in Advanced Relapsed Cases

Pereira GN\*, Ribeiro D, Saraiva L and Freitas H

Department of Plastic Surgery, Centro Hospitalar Universitário Lisboa Norte, Portugal

### Abstract

**Introduction:** Tumors involving the skull base are real challenges to reconstructive surgeons. Many articles have been published about these reconstructions, especially in primary cases. In tumor relapses after previous surgeries or irradiation, the surgical options for reconstruction are extremely narrowed and in our opinion that microvascular autologous tissue transplantation is specially indicated in those patients, even though it requires a technically demanding procedure.

**Materials and Methods:** We analyzed retrospectively all patients treated at our institution between March 2014 and December 2018 and that met all the inclusion criteria: 1) oncological surgery for a tumor involving the skull base; 2) previous surgical treatment for that tumor; 3) cranial base bone resection; 4) dural exposure or defect; 5) reconstruction done with a free flap. The patient's age, comorbidities, number of previous surgeries and/or irradiation, oncological excisional procedures, type of defect, type of reconstruction, postoperative complications and mortality were reviewed.

**Results:** Fifteen flaps were used in the 14 patients that met all the inclusion criteria. The used flaps were: Anterolateral Thigh (ALT) perforator or chimeric ALT/Vastus Lateralis (VL) (n=6), profunda artery perforator (n=3), muscular Rectus Abdominis (n=2), Vertical Rectus Abdominis Myocutaneous (VRAM) (n=2), chimeric osteomuscular scapular tip/Latissimus Dorsi (LD) (n=1) and radial forearm (n=1). Dural defects were reconstructed with Pericranial or fascia Lata grafts in 7 patients. No total flap failures or vascular thrombotic events were noted and just one case of partial flap necrosis was registered (treated conservatively). There was one case of cerebrospinal fluid leakage, one diffuse cerebral edema and one donor site wound dehiscence, all successfully treated with conservative measures. The only complication that required a second operation was a cranioplasty prosthetic exposure that required a second free flap. One patient had a tracheostomy bleeding followed by a pneumothorax and died 8 weeks postoperatively with a nosocomial pneumonia. In the follow-up period, one patient died 19 months postoperatively with a local relapse and another with a metastatic disease (at month 15).

**Conclusion:** Secondary or multiple relapsed cases in the skull base require reconstructions that are technically demanding and the defects are often extensive. The surgical options are extremely reduced by previous treatments and if the basic concepts of cranial base reconstruction were strictly respected, the microsurgical free flaps can offer the best chance to avoid severe complications. However, it is not without some postoperative complications and mortality can be significant in the follow-up because of the advanced stage of the oncologic disease.

**Keywords:** Head and neck; Tumor; Microsurgery; Reconstruction

### Introduction

Tumors involving the cranial base, although relatively rare, can bring great challenges to oncologic and reconstructive surgeons. Traditionally, when these tumors require an intracranial approach, we could expect high levels of morbidity and mortality. In the last few decades, new advances in anesthesia, surgical techniques, imageology and oncology allowed the treatment of these tumors in a relatively safe way. The advances in endoscopic surgery allowed the treatment of a vast array of tumors in the skull base with the advantage of a low-morbidity surgery. However, it is not without some limitations that can be outdated by an open surgery with a craniotomy where the exposition, control and oncological margins can be superior [1-5].

Although not frequently reported in the literature, the oncological relapses involving the cranial base are relatively common in our practice. It can be related to the fact that our hospital is a tertiary center and receives patients from all over the country and others from some African countries.

### OPEN ACCESS

**\*Correspondence:**

Gustavo Neves Pereira, Department of Plastic Surgery, Centro Hospitalar Universitário Lisboa Norte, Av. Egas Moniz, Lisboa, Portugal

**Received Date:** 20 Sep 2023

**Accepted Date:** 09 Oct 2023

**Published Date:** 14 Oct 2023

**Citation:**

Pereira GN, Ribeiro D, Saraiva L, Freitas H. Oncological Skull Base Reconstruction with Microvascular Tissue Transplantation in Advanced Relapsed Cases. *Clin Surg*. 2023; 8: 3665.

**Copyright** © 2023 Pereira GN. This is an open access article distributed under the Creative Commons Attribution License, which permits unrestricted use, distribution, and reproduction in any medium, provided the original work is properly cited.

In re-operative cases, oftentimes with previous multiple surgeries and radiation therapy, the locoregional flaps are not a common option for reconstruction. In these types of salvage surgeries, the defects can be composite, extensive and with large volume deficits. Today, we believe that autologous microvascularized tissue transplantation provides great versatility and safety in those types of reconstructions and should be the gold standard of care. That is what we want to demonstrate in this study.

### Materials and Methods

We retrospectively reviewed all skull base reconstructions treated at Hospital Santa Maria between March 2014 and December 2018.

**The inclusion criteria were:**

- 1) Oncological surgery for a tumor involving the cranial base
- 2) Previous surgical treatment for that tumor
- 3) Skull base bone resections
- 4) Dural exposure or defect
- 5) Reconstruction requiring a free flap

**The exclusion criteria were:**

- a) Primary cases
- b) Tumors involving the calvaria and scalp but not the cranial base
- c) Reconstructions with local or locoregional flaps
- d) Tumor-free patients with complications from previous oncological surgeries (e.g., cranioplasty prosthesis exposure)

Age, comorbidities, number of previous surgeries, prior irradiation, follow-up time, type of defects and oncological excisional procedures, type of reconstruction, postoperative complications and mortality were reviewed from medical charts. We classified cranial base defects based on the system of Irish et al. [6]. We also briefly

described if we had a simple dural exposure or a dural defect and the respective type of treatment. Written informed consent was obtained from all the patients included in this article.

### Results

We found 14 patients that met all the inclusion criteria. All these patients were treated by plastic surgery (led by senior author Freitas H.) and a neurosurgical team. In 9 patients we also had the collaboration of the otorhinolaryngologist surgical team.

Patient age, significant comorbidities, number of previous surgeries, prior irradiation and follow-up time were resumed in Table 1. The average age was 57.4 years (39–83) and the average number of previous surgeries was 2.6 (1 to 6). Six patients had previous irradiation. Three patients died in the follow-up period.

The type of tumor, oncological procedures and type of cranial base defect (Irish Classification) were resumed in Table 2.

Region I was the most frequently involved (8 patients) followed by region II (3 patients) and region III (1 patient). Two patients had defects in both regions I and II. Figure 1 exemplifies those types of defects.

Table 3 summarizes the dural involvement and respective management, type of flap used, recipient vessels and postoperative complications.

In the 14 patients treated, we used 15 flaps (4 Chimeric Vastus Lateralis/ALT; 3 Profunda Artery Perforator, 2 perforator ALT, 2 muscular Rectus Abdominis, 2 VRAM, 1 Chimeric Osteomuscular Scapular tip & LD and 1 radial forearm).

We had no total flap failures and just one partial skin flap necrosis. Only one patient had a postoperative complication that required another surgery. That patient (patient 1) developed an exposure of the calvarial prosthesis requiring a second free flap (radial forearm) for coverage, 7 weeks later. Three patients died in the follow-up period (patients 3, 9 and 13), 8 weeks, 19 and 15 months after surgery,

**Table 1:** Patient age, significant comorbidities, number of previous surgeries, prior irradiation and follow-up time.

Patient	Age	Comorbidities	Number previous surgeries	Prior irradiation	Follow-up
1	58	Hypertension Epilepsy	4	Yes	5 years
2	69	Diabetes mellitus type 2 Hypertension	3	Yes	5 years
3	73	Chronic obstructive pulmonary disease Malnutrition	1	No	Died 8 weeks postoperatively
4	43	Active smoker	1	No	3 years
5	41	Epilepsy	4	Yes	4 years
6	49	Alcohol addiction Previous smoker	1	No	3 years
7	78	Hypertension Ischemic Cardiopathy	4	Yes	3 years
8	47	VIH and HCV infections	1	No	3 years
9	39	-	5	Yes	Died 9 months postoperatively
10	66	Peripheral vascular disease, Hypertension, Diabetes mellitus type 2	6	Yes	2 years
11	49	-	1	No	2 years
12	83	Diabetes mellitus type 2 Hypertension	2	No	2 years
13	51	Active smoker	1	No	Died 22 months postoperatively
14	53	Diabetes mellitus type 2	2	No	4 years

**Table 2:** Type of tumor, oncological procedures and type of cranial base defect (Irish Classification).

Patient	Type of Tumor	Oncological Procedures	Cranial Base Defect (Irish Classification)
1	Meningioma	Middle cranial base and infratemporal fossa resection (anterior transmaxillary approach)	Region II
2	Ameloblastic Carcinoma	Resection of posterior reconstructed mandible, parotid gland, facial nerve, and lateral temporal bone resection (lateropterional approach); lateral nasopharynx (endoscopic)	Region II
3	Sebaceous Carcinoma	Frontotemporal calvarium, anterior and middle cranial base osteotomies, Radical Maxillectomy, Posterior Mandibulectomy, Parotidectomy, Wide skin resection	Regions I and II
4	Lacrimal Sac Squamous Cell Carcinoma (SCC)	Frontal sinus and orbital roof osteotomies, Ethmoidectomy, Limited Maxillectomy, Orbital Exenteration	Region I
5	Meningioma	Anterior and Middle cranial base resection (anterior transmaxillary approach), Orbital Exenteration	Region I and II
6	Nasosinus SCC	Frontal sinus and orbital roof resection, Radical Maxillectomy, Parotidectomy	Region I
7	Fibrous Tumor	Frontal sinus and calvarium, orbital roof, basilar region resection, Orbital Exenteration	Region I
8	Conjunctival SCC	Frontal sinus and calvarium, Ethmoidectomy, Orbital Exenteration	Region I
9	Cystic Adenoid Carcinoma	Frontal, ethmoidal and maxillary resection (with wide cutaneous excision)	Region I
10	Meningioma	Bifrontal calvarium, frontal sinus and orbital roof resection	Region I (bilateral)
11	Meningioma	Bifrontal calvarium and frontal sinus, basilar region and unilateral orbital roof resections	Region I (bilateral)
12	External Auditory Canal BCC	Lateral temporal bone resection, Posterior Mandibulectomy, Auriclectomy, Parotidectomy	Region II
13	Melanoma	Lateral temporal bone resection, Temporal and occipital calvarium resection, scalp resection	Region III
14	Cystic Adenoid Carcinoma	Radical Orbito-maxillectomy (with wide skin excision), Frontal sinus and orbital roof resection	Region I

**Table 3:** Summarizes the dural involvement and respective management, type of flap used, recipient vessels and postoperative complications.

Patient	Dural Status and Treatment	Type of Flap	Recipient Vessels	Postoperative Complications
1	Dural exposure; Flap coverage	Muscular <i>Rectus Abdominis</i> flap	Facial vessels	Cranioplasty prosthesis exposure (treated with a second free flap)
2	Dural defect; Pericranial graft repair	Muscular <i>Rectus Abdominis</i> flap	Superior Thyroid artery; External Jugular vein	-
3	Dural defect; Pericranial graft repair	VRAM flap	External Carotid artery; External Jugular vein	Tracheostomy bleeding; Pneumothorax; Nosocomial pneumonia; Death (8 weeks)
4	Dural exposure; Flap coverage	Profunda Artery Perforator flap	Facial vessels	-
5	Dural defect; Fascia lata graft repair	Profunda Artery Perforator flap	Facial vessels	-
6	Dural exposure; Flap coverage	Chimeric osteomuscular flap (Scapular tip & LD)	Facial vessels	-
7	Dural defect; Fascia lata graft repair	ALT flap	Superficial Temporal vessels	-
8	Dural exposure; Flap coverage	Profunda Artery Perforator flap	Superficial Temporal vessels	-
9	Dural defect; Fascia lata graft repair	Chimeric <i>Vastus Lateralis</i> / ALT flap	Arterio-venous (AV) saphenous loop (between superior thyroid artery and external jugular vein)	Cerebral Spine Fluid (CSF) leak, Donor site wound dehiscence
10	Dural defect; Fascia lata graft repair	Chimeric <i>Vastus Lateralis</i> / ALT flap	Superficial Temporal vessels	-
11	Dural defect; Fascia lata graft repair	Chimeric <i>Vastus Lateralis</i> / ALT flap	Superficial Temporal vessels	Diffuse cerebral edema
12	Dural exposure; Flap coverage	Chimeric <i>Vastus Lateralis</i> / ALT flap	Facial vessels	Partial skin flap necrosis
13	Dural exposure; Flap coverage	ALT flap	Superior Thyroid artery, Retromandibular vein	-
14	Dural exposure; Flap coverage	VRAM flap	Facial vessels	-

respectively.

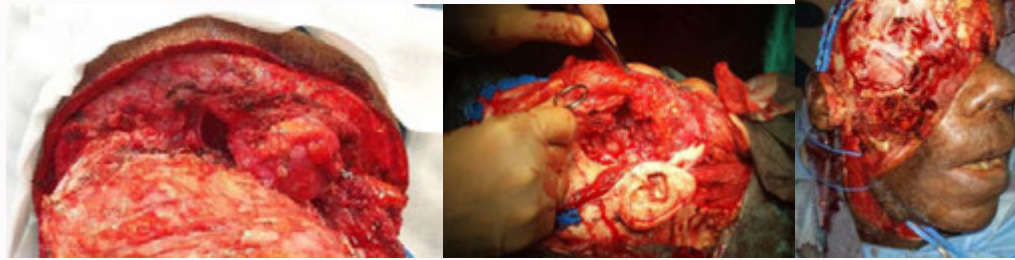
Seven patients had a dural defect, that was patched and repaired in a watertight fashion with a Pericranial or fascial Lata graft and posteriorly covered by the vascularized flap.

All patients received seven days of prophylactic antibiotics (ceftriaxone and metronidazole) and deep vein thrombosis prophylaxis with enoxaparin. Lumbar drains were not used.

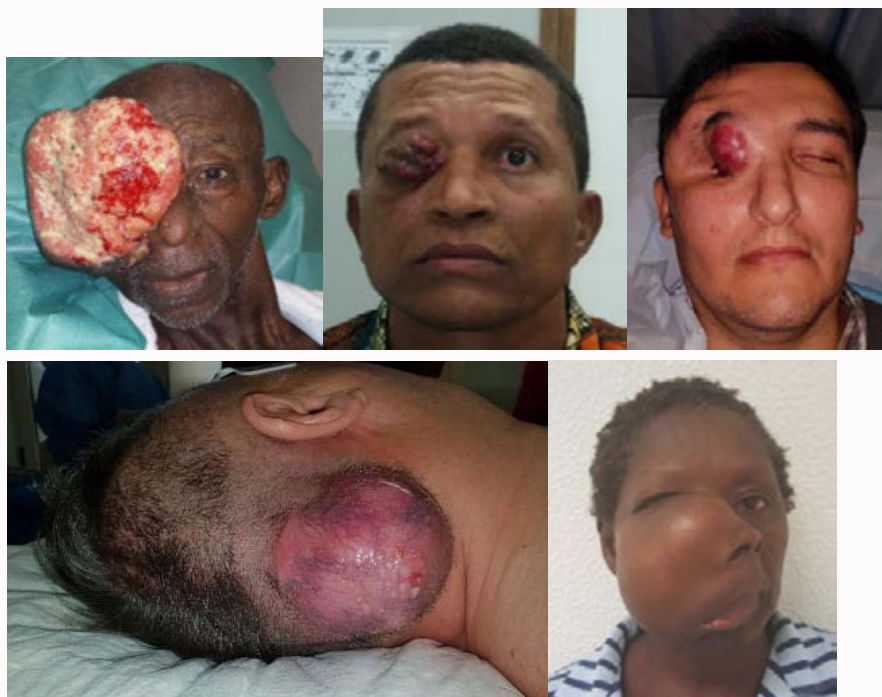Patient 3, rescued from an African country and cachectic, had

a massive sebaceous carcinoma involving the 3 facial floors. The immediate postoperative period was uneventful but 3 weeks later, in the decannulation procedure, he developed a tracheostomy bleeding that required immediate re-cannulation. A pneumothorax followed that required a chest tube. The patient died at week 8 with a nosocomial bilateral pneumonia.

Patient 9 had significant frontotemporal bone, dural and cutaneous coverage defects and large communication between cranial and Nasosinus cavities that was reconstructed with a fascia Lata graft



**Figure 1:** Left: Bilateral region I base defect in patient 11 with a calvarial bifrontal defect and dura already reconstructed with a fascia Lata graft. Centre: Region II defect in patient 2; the forceps are in the nasopharynx. Right: Region I and II defects in patient 3.



**Figure 2:** Pre-operative photographs of patients (from left to right) – Above: Patients 3, 8 and 9. Below: Patients 11 and 14.

(for dura) and chimeric ALT/VL flap (cutaneous paddle for coverage and muscle for cranial base obliteration and separation from nasal cavity). He had 5 previous surgeries and no receptor vessels available in the proximity. We revascularized that flap with an arteriovenous saphenous loop (26,27,28,29) between the ipsilateral superior thyroid artery and the external jugular vein. In the second postoperative week the patient developed a cerebrospinal fluid leak, in the frontal region. He also developed a donor site wound dehiscence in the thigh. Both complications resolved with conservative measures only. However, the patient died 19 months after the surgery with another extensive local relapse.

Patient 11, with a massive bifrontal-orbital meningioma, developed a coma state in the first postoperative day. The imaging studies revealed a diffuse cerebral edema without indication for any surgical procedure. After 6 days in the intensive care unit, the patient eventually recovered and had no sequels beyond the right amaurotic eye (already amaurotic preoperatively from chronic compression).

Patient 12 had a partial skin necrosis of a chimeric Vastus

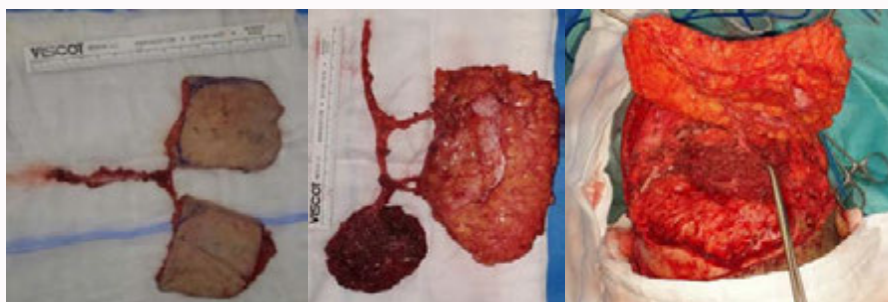
Lateralis/ALT flap, for the region II (temporal) that was treated conservatively.

Finally, patient 13 with a scalp melanoma died 15 months after surgery with a metastatic disease.

**Discussion**

Tumors involving the cranial base are very challenging to treat and normally require a multidisciplinary approach. In 1963, Ketchun et al. reported 89 patients who underwent resection of anterior cranial base tumors with good long-term survival and a mortality of 3% [7]. The recent advances in surgical procedures and technology, imaging and reconstructive microsurgery have become former nonoperative tumors in surgical ones [8-10]. The complex anatomy and vital structures in the area make tumor excision very difficult and place the patient at risk for devastating complications, like cerebrospinal leak, infections, meningitis and osteomyelitis, among many others. Fortunately, with the reconstructive techniques used today, we can minimize such complications to a reasonable number although not





**Figure 3:** Left: Profunda artery perforator flap with 2 skin paddles, in a “Y” type perforator design. Center: Chimeric ALT/Vastus lateralis flap with 2 perforators to the skin paddle and another one to the muscle pad. Right: Inset of the previous flap in the defect of patient 11; the muscle (pointed with the forceps) is obliterating the cranial base and separating the cranial and Nasosinusal cavities; the skin paddle will be used in the coverage of the scalp and calvarial bifrontal defect.

without any risks. The main objectives of cranial base reconstruction are the protection of the dura and prevention of CSF leaks; the creation of a separate intracranial cavity and aerodigestive tract; coverage of nervous tissues, blood vessels and skull base with well-vascularized tissue. Also important are the support of the orbit; restoration of speech, swallowing and facial nerve functions; elimination of dead space and restoration of facial contour [9,11-15].

Many papers have been written about the treatment of these tumors, mainly in primary cases. In this review, we only focus on patients with oncological relapses and advanced staged tumors with previous surgeries and/or radiation therapy (Figure 2). The main treatment principles of primary cases are also useful in patients with previous surgeries. However, the procedures are technically more demanding and the reconstructive options are considerably fewer. Local and regional flaps are used in very rare instances, especially in irradiated patients. Autologous microvascular tissue transplantation assumes a major role in the treatment of these cases and for us is the gold standard of care. Obviously, we need to consider the risks related to a prolonged surgery yet the majority of patients, even with some comorbidities can afford this type of treatment. Even old patients can tolerate microsurgical reconstructions with success but with some medical risks associated.

We strictly sought to achieve the main goals of cranial base reconstruction, previously described. Special attention was paid to the dura status. If it was intact and only exposed, we covered it with the vascularized flap in order to reduce CSF leaks and infections. In all patients with dural defects, we did not hesitate to make a watertight repair with grafts. Initially, we used Pericranial grafts (2 cases: Patients 2 and 3) but later we utilized fascia Lata grafts (5 patients) because of the larger availability and proximity to the surgical field in harvesting flaps in the thigh. The separation between the intracranial cavity and Nasosinusal, orbit and oral cavities was another main priority. We frequently used a muscular flap (rectus abdominis, LD or VRAM) or a de-epithelialized perforator flap to achieve this goal. The main flaps used were based in the descent branch of the lateral circumflex femoral system (perforator ALT or chimeric ALT/VL) [16-22]. We found the chimeric version very useful because we can use the skin paddle for coverage and/or obliteration and the muscle to fill the skull base and separate the cavities. The muscle paddle is well vascularized, easily conformable to the anfractuous structures of the cranial base and easy to inset. Another useful flap was the profunda artery perforator flap [23-25]. Because it has a common perforator anatomy in a “Y” fashion, we could divide it into two skin paddles, used for different purposes (e.g., one paddle for coverage and another

to obliterate or separate spaces) (Figure 3). In all patients with frontal sinus involvement, we carefully resect or cranialize it and obliterate the nasal communication with the flap.

Cerebrospinal leaks are one of the rearrest complications of these procedures. Patient 9 had a large fistula to the Nasosinusal cavity that was separated and obliterated with the muscle paddle of a chimeric VL/ALT flap. Surprisingly, the leakage was developed, not through the skull base, but through de high frontal scalp and calvarial defect. Although there are many articles that address these leaks from the cranial base [26-30], we did not find any literature about this highly located type of leakage. It was resolved successfully with conservative measures only.

This study has some important limitations. It is retrospectively based and the population is also small. The patient population is also very heterogeneous, with different types of tumors, in diverse locations and with different types of reconstructions and prognoses.

However, we can infer some trends for these reconstructions in these relapsed cases. Some of these patients had very advanced relapsed disease, like patients 3, 8, 11 and 14, that were rescued from African countries. Others had been operated many times (like patient 9 with 5 previous surgeries or patient 10 with 6 surgeries) and irradiated. Strictly following the basic surgical principles of cranial base reconstruction (like in primary cases) we can also achieve reasonable results. And to achieve these results microvascular autologous tissue transplantation is a very powerful weapon. However, it is not without potential serious complications and survival is seriously affected by the relapsed or advanced disease stage.

## Conclusion

We believe that autologous microvascularized tissue transplantation provides great versatility and safety in those types of reconstructions and should be the gold standard of care.

## References

1. Moyer JS, Chepeha DB, Teknos TN. Contemporary skull base reconstruction. *Curr Opin Otolaryngol Head Neck Surg.* 2004;12(4):294-9.
2. Prevedello DM, Kassam AB, Snyderman C, Carrau RL, Mintz AH, Thomas A, et al. Endoscopic cranial base surgery: ready for prime time? *Clin Neurosurg.* 2007;54:48-57.
3. Reyes C, Mason E, Solares CA. Panorama of reconstruction of skull base defects: from traditional open to endonasal endoscopic approaches, from free grafts to microvascular flaps. *Int Arch Otorhinolaryngol.* 2014;18(Suppl 2):S179-86.
4. Hadad G, Bassagasteguy L, Carrau RL, Mataza JC, Kassam A, Snyderman

- CH, et al. A novel reconstructive technique after endoscopic expanded endonasal approaches: Vascular pedicle nasoseptal flap. *Laryngoscope*. 2006;116(10):1882-6.
5. Kang SY, Eskander A, Carrau R, Hachem RA, Ozer E, Teknos TN, et al. Salvage skull base reconstruction in the endoscopic era: Vastus lateralis free tissue transfer. *Head Neck*. 2018;40(4):E45-E52.
6. Irish J, Gullane PJ, Gentili F, Freeman J, Boyd JB, Brown D, et al. Tumors of the skull base: Outcome and survival analysis of 77 cases. *Head Neck*. 1994;16:3-10.
7. Ketchum AS, Wilkins RH, VanBuren JM, Smith RR. A Combined intracranial transfacial approach to the paranasal sinuses. *Am J Surg*. 1963;106:698-703.
8. Shah JP, Bilsky MH, Patel SG. Malignant tumors of the skull base. *Neurosurg Focus*. 2002;13:e6.
9. Chiu ES, Shah JP, Cordeiro PG. Anterior and middle cranial fossa skull base reconstruction using microvascular free tissue techniques: surgical complications and functional outcomes. *Ann Plast Surg*. 2008;60(5):514-20.
10. Clayman GL, DeMonte F, Jaffe DM, Schusterman MA, Weber RS, Miller MJ, et al. Outcome and complications of extended cranial-base resection requiring microvascular free-tissue transfer. *Arch Otolaryngol Head Neck Surg*. 1995;121:1253-7.
11. Chang DW, Lanstein HN, Gupta A, De Monte F, Do KA, Wang X, et al. Reconstructive management of cranial base defects after tumor ablation. *Plast Reconstr Surg*. 2001;107:1346-55; discussion 1356-7.
12. Nelligan PC, Mulholland S, Irish J, Gullane PJ, Boyd JB, Gentili F, et al. Flap selection in cranial base reconstruction. *Plast Reconstr Surg*. 1996;98:1159-66; discussion 1167-8.
13. Teknos TN, Smith JC, Day TA, Netterville JL, Burkey BB. Microvascular free tissue transfer in reconstructing skull base defects: Lessons learned. *Laryngoscope*. 2002;112:1871-6.
14. Califano J, Cordeiro PG, Disa JJ, Hidalgo DA, DuMornay W, Bilsky MH, et al. Anterior cranial base reconstruction using free tissue transfer: Changing trends. *Head Neck*. 2003;25:89-96.
15. Hanasono MM, Lee JC, Yang JS, Skoracki RJ, Reece GP, Esmali B. An algorithmic approach to reconstructive surgery and prosthetic rehabilitation after orbital exenteration. *Plast Reconstr Surg*. 2009;123:98-105.
16. Amin A, Rifaat M, Civantos F, Weed D, Abu-Sedira M, Bassiouny M. Free anterolateral thigh flap for reconstruction of major craniofacial defects. *J Reconstr Microsurg*. 2006;22:97-104.
17. Malata CM, Terhani H, Kumiponjera D, Hardy DG, Moffat DA. Use of anterolateral thigh and lateral arm fasciocutaneous free flaps in lateral skull base reconstruction. *Ann Plast Surg*. 2006;57:169-75.
18. Wei FC, Jain V, Celik N. Free anterolateral thigh flap for reconstruction of head and neck defects following cancer ablation. *Plast Reconstr Surg*. 2000;105:2349-60.
19. Simsek T, Engin MS, Yildirim K, Kodalak EA, Demir A. Reconstruction of extensive orbital exenteration defects using an anterolateral thigh/vastus lateralis chimeric flap. *J Craniofac Surg*. 2017;28(3):638-42.
20. Kim SW, Kim KN, Hong JP, Park SW, Park CR, Yoon CS. Use of the chimeric anterolateral thigh free flap in lower extremity reconstruction. *Microsurgery*. 2015;35(8):634-9.
21. Lawson BR, Moreno MA. Head and neck reconstruction with chimeric anterolateral thigh free flap: Indications, outcomes, and technical considerations. *Otolaryngol Head Neck Surg*. 2016;154(1):59-65.
22. Hanasono MM, Sacks JM, Goel N, Ayad M, Skoracki RJ. The anterolateral thigh free flap for skull base reconstruction. *Otolaryngol Head Neck Surg*. 2009;140(6):855-60.
23. Wu CW, Huang JJ, Cheng MH, Tsao CK, Abdelrahman M, Kolios G. Comparison of posteromedial thigh profunda artery perforator flap and anterolateral thigh perforator flap for head and neck reconstruction. *Plast Reconstr Surg*. 2016;137(1):257-66.
24. Mayo JL, Allen RJ, Hilaire H, Canizares O, Torabi R. Expanding the applications of the profunda artery perforator flap. *Plast Reconstr Surg*. 2016;137:663-9.
25. Scaglioni MF, Yang JC, Chen YC. The posteromedial thigh flap for head and neck reconstruction: Anatomical basis, Surgical technique, and clinical applications. *Plast Reconstr Surg*. 2015;136:363-75.
26. Tseng WL, Chang TY, Lee YC, Hung KS, Chen SH, Hsiao JR. Total maxillary reconstruction with a bi-paddle double-barrel osteocutaneous fibular flap and arteriovenous saphenous loop after globe-sparing total maxillectomy due to osteosarcoma. *J Craniofac Surg*. 2017;28(1):193-6.
27. Pusic AL, Chen CM, Patel S, Cordeiro PG, Shah JP. Microvascular reconstruction of the skull base: A clinical approach to surgical defect classification and flap selection. *Skull Base*. 2007;17:5-15.
28. Scholsem M, Scholtes F, Collignon F, Robe P, Dubuisson A, Kaschten B, et al. Surgical management of anterior cranial base fractures with cerebrospinal fluid fistulae: A single-institution experience. *Neurosurgery*. 2008;62:463-9.
29. Zapalac JS, Marple BF, Schwade ND. Skull base cerebrospinal fluid fistulas: A comprehensive diagnostic algorithm. *Otolaryngol Head Neck Surg*. 2002;126:669-76.
30. Inman J, Ducic Y. Intracranial free tissue transfer for massive cerebrospinal fluid leaks of the anterior cranial fossa. *J Oral Maxillofac Surg*. 2012;70:1114-8.