



## Multifocal Central Giant Cell Granuloma of the Mandible in 9 Year Old Boy with One Stage Surgery using Fibula Free Flaps with Virtual Surgical Planning

Łukasz Krakowczyk<sup>1\*</sup>, Krzysztof Dowgierd<sup>2</sup>, Maciej Borowiec<sup>2</sup> and Dominika Smyczek<sup>3</sup>

<sup>1</sup>Department of Oncological and Reconstructive Surgery, Maria Skłodowska-Curie Institute-Oncology Center Gliwice Branch, Poland

<sup>2</sup>Department of Head and Neck Surgery-Maxillofacial Surgery in Olsztyn, Voivoid Children Hospital, Poland

<sup>3</sup>Department of Pediatric Surgery and Urology, Medical University of Silesia in Katowice, Poland

### Abstract

Central Giant Cell Granuloma (CGCG) accounts for 1% to 7% of all benign lesions of the head and neck. It often arises in the maxilla followed by mandible and affects children and young adults. Free flap surgery in the pediatric population has gained widespread acceptance regarding its technical utility and reliability. One-stage reconstruction combining osseous free flaps with virtual surgical planning are becoming the standard for mandibular defects. The aim of this study was the present the case with fibula free flap with virtual surgical planning for reconstruction after resection of multiple central giant cell granulomas of the mandible and to assess the feasibility and safety of this technique.

### Introduction

Central Giant Cell Granuloma (CGCG) is not a true neoplasm but rather a reactive process; its origin can be triggered by trauma or inflammation. Most commonly the disease affects maxilla followed by the mandible and often seen in children and young adults, predominantly females, in the second and third decade of life [1]. Fast-growing lesions have rarely been reported. In these six cases, CGCG are characterized by an aggressive behavior against an innocent histological appearance, pain, and rapid facial swelling. The clinical importance of these benign tumors is that they clinically mimic a malignant lesion [2,3]. The present case illustrates a rare aggressive variety of CGCG, with an atypical clinical presentation in young boy; attention has been focused in particular on surgical treatment with custom-made 3D models.

Free flaps are a useful reconstructive option in the management of mandible defects, even in the pediatric population [4]. Initial concerns as to the feasibility and reliability of the procedure in children were readily overcome by the fact that the relative size of the pedicle vessels is larger than those in adults [5].

The aim of this study was the present the case with fibula free flap with virtual surgical planning for reconstruction after resection of multiple central giant cell granulomas of the mandible and to assess the feasibility and safety of this technique.

### Case Presentation

The 9-year-old boy who underwent fibula free flap reconstruction using the virtual surgical planning following resection of mandible multiple tumors at the Children's Hospital in Olsztyn in 2016. The patient has undergone ablative surgery and primary free flap reconstruction at our institution and the pathology report was confirming the aggressive variety of CGCG. Follow-up notes from surgical and medical outpatient clinics were reviewed for late complications, evaluation of growth and function of the reconstructed area and donor sites, and outcome. The follow-up is 24 month. As a part of our workup imaging studies were obtained, including a craniofacial CT and lower extremity CT. Virtual surgical planning was used to provide fibular cutting guidelines and to provide custom contoured plates and splints.

The fibula free flap for reconstruction of defects following surgery for giant cell granuloma of the mandible was performed. In this case almost whole mandible without mental protuberance was

### OPEN ACCESS

#### \*Correspondence:

Łukasz Krakowczyk, Department of Oncological and Reconstructive Surgery, Maria Skłodowska-Curie Institute-Oncology Center Gliwice Branch, 44-100 Gliwice, ul. Wybrzeże AK 15, Poland, Tel: +48322788514; E-mail: lukaszkrakowczyk@wp.pl

Received Date: 20 Jul 2018

Accepted Date: 14 Aug 2018

Published Date: 16 Aug 2018

#### Citation:

Krakowczyk Ł, Dowgierd K, Borowiec M, Smyczek D. Multifocal Central Giant Cell Granuloma of the Mandible in 9 Year Old Boy with One Stage Surgery using Fibula Free Flaps with Virtual Surgical Planning. *Clin Surg*. 2018; 3: 2072

Copyright © 2018 Łukasz Krakowczyk. This is an open access article distributed under the Creative Commons Attribution License, which permits unrestricted use, distribution, and reproduction in any medium, provided the original work is properly cited.

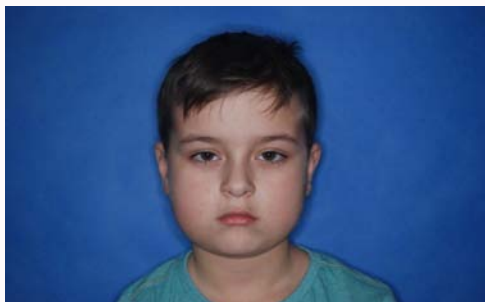


Figure 1: Pre-operative appearance.

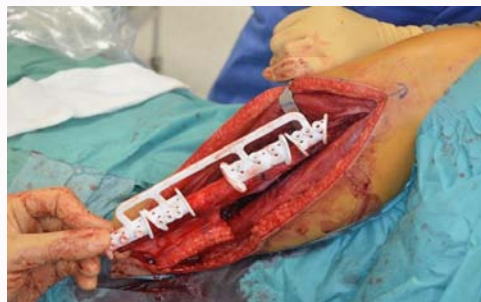

Figure 4: Fibula cutting guides.

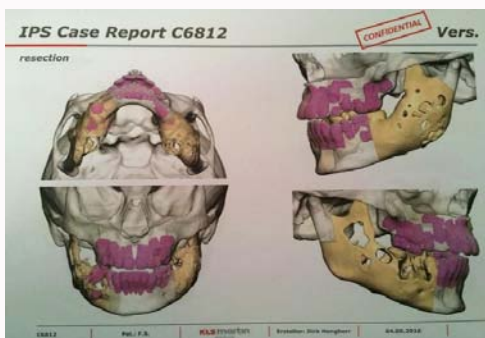


Figure 2: Multifocal giant cell tumors of the mandible in virtual surgical planning.

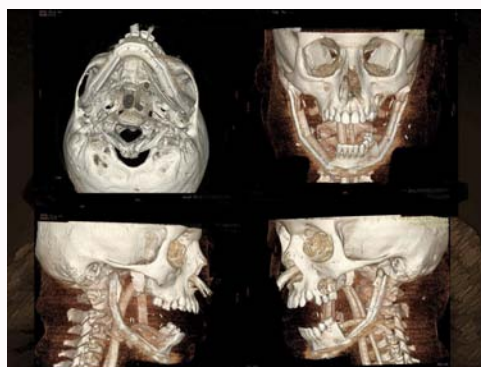

Figure 5: CT after tumors resection and reconstruction.



Figure 3: Final stereolithographic models with actual custom plates used intra-operatively.

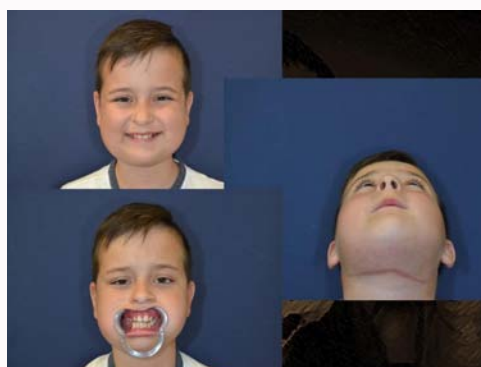


Figure 6: Three month post-operative appearance.

performed. The fibula osteoseptocutaneous flap was designed with small 2 cm x 5 cm skin paddle as a survival monitor with isolated about 15 cm peroneal vessel pedicle. Prior to pedicle division the fibula cutting guide was attached to the fibula. Proximal and distal osteotomies were then performed and connected to the individual titanium plate. A limited neck dissection exposing the facial artery and vein was performed. Using a Gore tunneler, the peroneal vessels were passed down to the exposed neck vessels. After osteosynthesis fibula with mandible the microvascular anastomosis were performed, connecting the facial artery with the peroneal artery using coupler size 1.5 mm, and facial vein with peroneal vein using coupler size 2.5 mm. The skin island was sutured as a survival monitor to the sub mental region; he did not require a tracheostomy. There was no donor site complication. Functional outcome, including mastication, deglutition, and speech was very satisfactory. The boy has intelligible speech and the cosmetic result was excellent. There was no impairment of donor site growth or function.

### Discussion

Central Giant Cell Granuloma (CGCG) is found in 75% in the mandible, usually near the mental foramen, also in the region of molar teeth. In the presented case, the multifocal tumor was detected in mandible. From slow and asymptomatic growth, associated with non-aggressive form, which applies to 60% to 80% of cases that stay unnoticed for a long time, because of their growth inside of the trabecular bone and no pain or neurological disorders. However migration of teeth can be observed. To the rarely occurring aggressive type, usually found in 19 to 40% of all CGCG cases, which causes bone mutilation, migration and loss of teeth, root resorption and infiltration of the soft tissues. Frequent symptoms are pain and paresthesia, pathological fractures and recurrences [1,2].

The use of a vascularized composite bone flap for functional mandible reconstruction represents the current state-of-the-art technique. Satisfactory aesthetic results can be achieved using the

fibula flap with virtual surgical planning, which is the ideal choice for mandible reconstruction [5,6]. In the present case, the autologous reconstruction utilized digital technology and custom-made models were performed with excellent functional and aesthetic results. However, the short-term outcome particularly if this does not extend through puberty-may differ significantly from the final result following the adolescent growth spurt and resultant anatomical changes and asymmetries.

The surgical result of this case demonstrate that free flap reconstruction using virtual planning is an efficient and relatively safe technique for reconstructing surgical defects of the head and neck in children undergoing extensive surgery. Despite the difficulties in performing the surgery and in the postoperative care of these children, free flap reconstruction provides satisfactory functional and esthetic results.

## References

1. Bataineh AB, Al-Khateeb T, Rawashdeh MA. The surgical treatment of central giant cell granuloma of the mandible. *J Oral Maxillofac Surg.* 2002;60(7):756-61.
2. Thompson SH, Bischoff P, Bender S. Central giant cell granuloma of the mandible. *J Oral Maxillofac Surg.* 1983;41(11):743-6.
3. Harii K, Ohmori K. Free groin flaps in children. *Plast Reconstr Surg.* 1975;55(5):588-92.
4. Akçal A, Karşıdağ S, Sucu DÖ, Turgut G, Uğurlu K. Microsurgical reconstruction in pediatric patients:a series of 30 patients. *Ulus Trauma Acil Cerr Derg.* 2013;19(5):411-6.
5. Parry SW, Toth BA, Elliott LF. Microvascular free-tissue transfer in children. *Plast Reconstr Surg.* 1988;81(6):838-40.
6. Runyan CM, Sharma V, Staffenberg DA, Levine JP, Brecht LE, Wexler LH, et al. Jaw in a day-state of the art in maxillary reconstruction. *J Craniofac Surg.* 2016;27(8):2101-4.
7. Arnold DJ, Wax MK. Microvascular Committee of the American Academy of Otolaryngology-Head and Neck Surgery, Pediatric microvascular reconstruction; a report from the Microvascular Committee. *Otolaryngol Head Neck Surg.* 2007;136:848-51.