



Metastatic Prostate Cancer Showing Superscan on Radionuclide Imaging

Jatinder Kumar*, Muhammad Umar Alam, Charu Shastri, Mark Bandyk, Joseph Costa and Balaji KC

Department of Urology, University of Florida, USA

Clinical Image

A 58 year old male presented with low back and right thigh pain, previously evaluated with X-ray lumbar spine and pelvis showing multiple scattered areas of bone sclerosis. Prostate biopsy done at PSA of 4771 ng/ml confirmed grade group 3 prostatic adenocarcinoma. Furthermore, his ^{99m}Tc-MDP bone scan showed diffuse increase intracer uptake involving the axial skeleton including skull, spine, bilateral ribs, pelvic bones, bilateral clavicles, bilateral scapula, sternum, proximal femurs and proximal left humerus. Renal activity was not seen Figure 1. This finding was consistent with “superscan”. Superscan is intense symmetric activity in the bones with diminished renal and soft tissue activity on radio-nucleotide imaging. It may be secondary to metastatic, metabolic, or hematologic disease causing increased osteoblastic activity Figure 2. The absent genitourinary activity (Absent kidney sign) is pathognomonic of a superscan. Patient was started on androgen deprivation therapy and abiraterone with prednisolone with excellent PSA response.

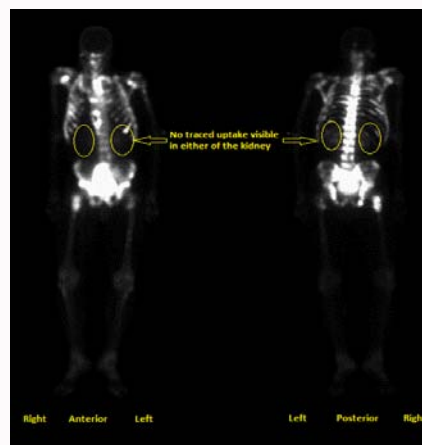


Figure 1: Superscan labeled.

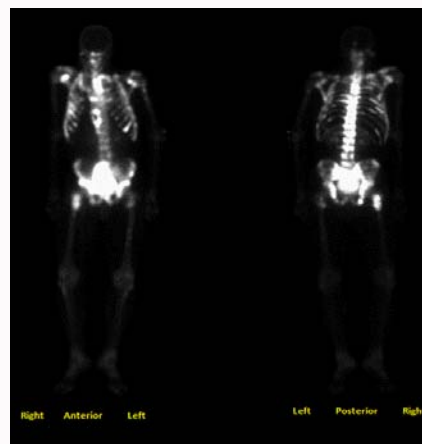


Figure 2: Superscan unlabeled.

OPEN ACCESS

*Correspondence:

Jatinder Kumar, Department of Urology,
University of Florida, Jacksonville,
Florida, USA, Tel: 904-699-7488;
E-mail: Jatinderurology82@gmail.com

Received Date: 15 Dec 2020

Accepted Date: 06 Jan 2021

Published Date: 13 Jan 2021

Citation:

Kumar J, Alam MU, Shastri C, Bandyk M, Costa J, Balaji KC. Metastatic Prostate Cancer Showing Superscan on Radionuclide Imaging. *Clin Surg.* 2021; 6: 3029.

Copyright © 2021 Jatinder Kumar.

This is an open access article distributed under the Creative Commons Attribution License, which permits unrestricted use, distribution, and reproduction in any medium, provided the original work is properly cited.