



Metastasis of Breast Cancer to Renal Cell Carcinoma: A Rare Case of Tumor-to-Tumor Metastasis (TTM)

Eymen Gazel^{1*}, Serdar Yalcin², Engin Kaya², Aytug Uner³, Yesim Saglıcan⁴ and Lutfi Tunc⁵

¹Department of Urolog, Acibadem University, Turkey

²Department of Urology, Gulhane Education and Research Hospital, Turkey

³Department of Oncology, Gazi University School of Medicine, Turkey

⁴Department of Pathology, Acibadem University, Turkey

⁵Department of Urology, Gazi University School of Medicine, Turkey

Abstract

Objectives: The aim of this case presentation was to show a case of primary breast cancer with metastasis to renal cell cancer.

Methods: A 42-year old female patient presented with a palpable mass in both breasts and tru-cut biopsy was applied. The result of the biopsy showed in the right breast: invasive ductal carcinoma and in the left breast: mixed invasive ductal and invasive micropapillary carcinoma. In the upper pole of the left kidney, a mass of approximately 3cm was determined. With these findings, the patient was diagnosed as Grade 4 breast cancer with multiple distant metastases and chemotherapy was planned. At the end of a 10-month follow-up period, the metastases had recovered and the response of the patient to chemotherapy was reported to be good. However on the follow-up abdominal CT, there was observed to still be a mass in the mid-section of the left kidney, 2.7 cm × 2.8 cm × 3.3 cm in size, showing contrast involvement and consistent with malignancy. Laparoscopic radical nephrectomy was applied to the patient. Unclassified type RCC was determined. The general status of the patient is currently good with no recurrence and follow-up is continuing.

Results and Conclusions: To date, metastasis of breast cancer has been determined in only 3 cases of resected RCC. This case is of value as the fourth case in literature of RCC metastasis from breast cancer. In conclusion, metastasis from breast cancer to RCC is not often encountered in patients. The case presented here is the 4th case of nephrectomy applied and proven breast cancer metastasis to RCC. Therefore, there is extremely limited information about the follow-up of these patients. There is a need for long-term follow-up to share the problems and treatment of these patients.

Keywords: Breast cancer; RCC; Metastasis; Oncology; Nephrectomy

Introduction

When two different tumors are determined at the same time in one patient, they are known as “synchronised tumors”. Although synchronised tumors are often encountered, metastasis to a tumor from a tumor of different primary origin is a rarely seen occurrence. This is known as Tumor-to-Tumor Metastasis (TTM) phenomenon [1]. TTM was first defined by Berent in 1902, as the visualisation in the same localisation of two tumors originating from different organs which are histologically, morphologically and immunophenotypically independent of each other [2-4].

It is known that Renal Cell Cancer (RCC) is often seen together with other organ tumors and metastases from other organ tumors to RCC are also seen [5]. However, it can be understood from literature that metastasis of breast cancer to RCC has been observed very rarely [1]. To date, metastasis of breast cancer has been determined in only 3 cases of resected RCC. Nevertheless, there have also been 2 cases reported where metastasis of breast cancer to RCC was determined incidentally during autopsy [6,7].

The aim of this case presentation was to show a case of primary breast cancer with metastasis to renal cell cancer. This case is therefore the fourth case in literature of RCC metastasis from breast cancer.

OPEN ACCESS

***Correspondence:**

Eymen Gazel, Department of Urology, Acibadem University, Ankara, Turkey, Tel: 05332684240;

E-mail: eymen_gazel@yahoo.com

Received Date: 01 Feb 2018

Accepted Date: 01 Mar 2018

Published Date: 09 Mar 2018

Citation:

Gazel E, Yalcin S, Kaya E, Uner A, Saglıcan Y, Tunc L. Metastasis of Breast Cancer to Renal Cell Carcinoma:

A Rare Case of Tumor-to-Tumor Metastasis (TTM). *Clin Surg.* 2018; 3: 1935.

Copyright © 2018 Eymen Gazel. This is an open access article distributed under the Creative Commons Attribution License, which permits unrestricted use, distribution, and reproduction in any medium, provided the original work is properly cited.

Case Presentation

A 42-year old female patient presented with a palpable mass in both breasts and tru-cut biopsy was applied. The result of the biopsy showed in the right breast, invasive ductal carcinoma Grd1, Ki-67 proliferation index: 20%, Estrogen Receptor (ER): 95%, progesterone receptor (PR): 80% (+), C-ERB-B2 (-); and in the left breast: mixed invasive ductal and invasive micropapillary carcinoma, Grd2, Ki-67 proliferation index: 30% to 40%, ER:90%, PR:60% (+), C-ERB-B2 (-). In the Computed Tomography (CT) scanning applied to the patient, multiple primary cancer foci were determined bilaterally in the breasts and multiple metastases were determined in the bones and lungs. In the upper pole of the left kidney, a mass of approximately 3 cm was determined.

With these findings, the patient was diagnosed as Grade 4 breast cancer with multiple distant metastases and chemotherapy was planned with the Oncology Department. In the chemotherapy, 7 cycles of FEC (5-FU: 900 mg+ Epirubicin: 170 mg+ Cyclophosphamide: 900 mg) were applied and 5 cycles of TC (Docetaxel 140 mg+ Cyclophosphamide: 800 mg) and bone support treatment of Zoledronic acid 4 mg once every 21 days.

At the end of a 10-month follow-up period, the metastases had recovered and the response of the patient to chemotherapy was reported to be good. However on the follow-up abdominal CT, there was observed still be a mass in the mid-section of the left kidney, 2.7 cm × 2.8 cm × 3.3 cm in size, showing contrast involvement and consistent with malignancy (Figure 1). Laparoscopic radical nephrectomy was applied to the patient. In the pathological examination, a tumor 3 cm in diameter was determined macroscopically in the mid-section of the left kidney (Figure 2) and in the histological examination, unclassified type RCC was determined containing micropapillary breast cancer metastasis in the form of small foci. There was reported to be no invasion to perirenal fat tissue, the renal vein or lymph nodes and no microvascular invasion. The pathology was reported as grade T1aN0M0.

In the histochemical examination applied with the Ventana benchmark xt method, the results were reported as CK7 [Biocare Med(OV-TL 12/30)]: positive; WT1 [CELL MARQUE (6F-H2)]:negative; ER [LEICA (6F11)]: positive in areas of breast carcinoma, negative in RCC areas; HER-2/neu 4B5 [VENTANA]: negative; GCDFP15 [Biocare Medical (D6)]:): positive in areas of breast carcinoma, negative in RCC areas; GATA3 [CELL MARQUE (L50-823)]:): positive in areas of breast carcinoma, negative in RCC areas; PAX8 [CELL MARQUE (MRQ-50)]:): negative in areas of breast carcinoma, positive in RCC areas; CD10 [SCYTEK (56C6)]: negative; P504S [Biocare Medical (N/A)]: negative; Ki-67 [DAKO (MIB-1)]: 5% in breast carcinoma areas, 1% in RCC areas.

Following the nephrectomy, hormonal treatment was started of tamoxifen 2 × 10 mg/day. In respect of ease of use, bone support treatment was added of Clodronate disodium 2 × 800 mg/day. The general status of the patient is currently good with no recurrence and follow-up is continuing.

Discussion

Following the definition of Tumor-to-Tumor Metastasis (TTM) phenomenon by Berent, Campbell stated the conditions required for a case to be said to be TTM. According to this, the patient has more than one tumor, the tumor receiving the metastasis is an actual

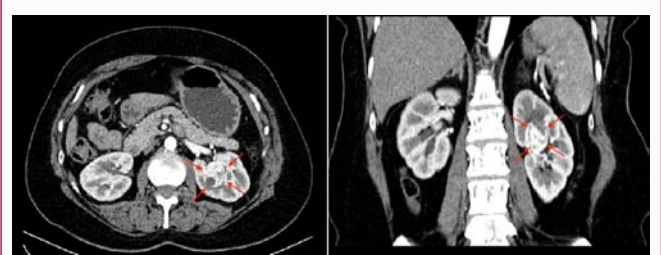


Figure 1: A mass in the mid-section of the left kidney, 2.7 cm × 2.8 cm × 3.3 cm in size.

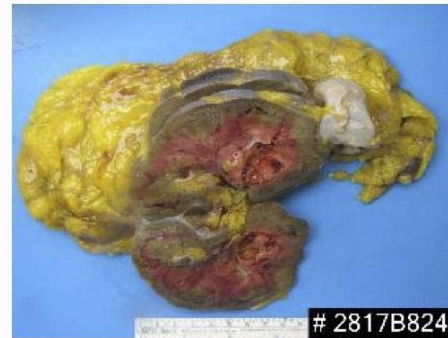

Figure 2: A tumor 3 cm in diameter was determined macroscopically in the mid-section of the left kidney.

neoplasm, the tumor making the metastasis develops within the receiving tumor, it does not develop through adjacent pathways or by embolisation from vessels and the metastatic tumor is a tumor which does not metastasise to the lymphatic system on the basis of a lymphovascular malignancy (lymphoma/leukemia) that is already present [3,4]. The case presented here fulfilled these conditions and can therefore be accepted as a case of TTM.

Two different theories have emerged to explain the pathophysiology of the concept of TTM. One of these is the “seed and soil” theory. According to this, the metastatic cell (seed) shows easier development within tumor tissue of low metabolism and containing high collagen and fat (soil). In an animal experiment with results that supported this theory, it was shown that cancer cells transferred within sarcoma tissue grew more rapidly than normal tissue. The other theory is “mechanical”. According to this, there is an increase in the vascular structure in the tumor tissue which is present and associated with this an increase develops in the blood supply. This causes circulation of more malignant cells in the tumoral region, thereby creating an environment which increases the risk of metastases [8].

RCC is the tumor that most often accompanies other malignancies [6]. Furthermore, when all the TTM cases were examined, the most common receiving tumor was seen to be RCC, followed by sarcoma, meningioma, and thyroid cancer and hypophysis adenoma. The cancer type which most often metastasises to other tumors is lung cancer, followed by breast cancer and prostate cancer [9]. The reason that RCC receives the most metastases is that the kidneys receive a large part of cardiac output and are more exposed to metastatic cells. This hypothesis can be seen to be consistent with the “mechanical” theory.

The cancer metastasising most often to kidney tumors is lung adenocarcinoma. Although breast cancer is one of the cancers most

often metastasising to other tumors, metastasis to kidney tumors is rare. Metastasis from breast cancer to kidney angiomyolipoma has been reported in a total of 3 cases [10]. Similarly, metastasis to RCC is seen very rarely. To date, a total of 5 cases have been reported, 2 of which were determined during autopsy. Thus, a total of 3 RCC cases are known where they have been admitted for surgery and breast cancer metastasis has been seen.

In those cases, it is noticeable that all the metastatic breast cancers were invasive ductal cancer. In the current case, the breast cancer was determined as micropapillary subgroup of invasive ductal type. In literature, metastases have been examined immunohistochemically with Estrogen Receptor (ER) staining. Two (2/5) cases were reported as ER: positive, 2/5 as ER: negative, 1/5 as HER-2/neu positive and 3/5 as HER-2/neu negative. The results of 1 case were not available. In the current case the breast carcinoma areas were stained ER positive and HER-2/neu negative.

The age of patients with TTM ranges from 43 to 75 years. The case presented here was 42 years old and is therefore the youngest case in literature of metastasis from breast cancer to RCC. The time to TTM after diagnosis of breast cancer has been reported to range from 1 year to a maximum of 30 years and in one case TTM was found to be present during the breast cancer diagnosis [1]. In that case, no response was seen to chemotherapy and as it was suspected that the mass in the kidney could be a different malignancy from the breast cancer, it was decided to perform a nephrectomy. In the current case, the mass in the kidney was determined during the breast cancer diagnosis. There is no definitive way of differentiating whether this simultaneous lesion in the kidney is a metastasis from the primary cancer, or a different malignancy of the kidney. In such cases it can be considered more appropriate to start chemotherapy taking metastatic breast cancer into account and then acting according to the response to this treatment. When TTM was determined in all the other cases, there were seen to be multiple metastases already in other locations apart from RCC. In the current case, bone and lung metastasis was also found when TTM was determined.

In other TTM cases, survey of the patients has been seen to be short. One patient was lost at 10 months after nephrectomy. Another patient refused treatment and withdrew from follow-up with recurrence and progression of metastases outside the kidney in the postoperative 4th month. In the other case, follow-up could not be made. Since the diagnosis of breast cancer in the current case, 14 months have passed and 4 months since the nephrectomy due to the diagnosis of RCC. The general performance of this patient is extremely good, with no recurrence, no progression and ongoing follow-up.

In conclusion, metastasis from breast cancer to RCC is not often encountered in patients. The case presented here is the 4th case of nephrectomy applied and proven breast cancer metastasis to RCC. Therefore, there is extremely limited information about the follow-up of these patients. There is a need for long-term follow-up to share the problems and treatment of these patients. In addition it must not be forgotten that RCC is the most common tumor accompanying other tumors and is even the most common metastasis receiving tumor. If there is kidney involvement in patients with a metastatic tumor, it should always be considered that there is the possibility that this could be metastasis to the kidney from the primary tumor or a direct RCC case.

References

1. Huo Z, Gao Y, Yu Z, Zuo W, Zhang Y. Metastasis of breast cancer to renal cancer: report of a rare case. *Int J Clin Exp Pathol*. 2015;8(11):15417-21.
2. Berent W, Seltene metastasenbildung. *Zentralbl. Allg. Pathol*. 1902;13:406.
3. Campbell LV, Gilbert E, Chamberlain CR, Wtne AL. Metastases of cancer to cancer. *Cancer*. 1968;22(3):635-43.
4. Amin M, Radkay L, Pantanowitz L, Fine J, Parwani A. Tumor-to-tumor metastasis (TTM) of breast carcinoma within a solitary renal angiomyolipoma: A case report. *Pathol Res Pract*. 2013;209(9):605-8.
5. Richardson J, Katamaya I. Neoplasma to neoplasm metastasis. *Arch Pathol*. 1971;91:135-9.
6. Sella A, Ro JY. Renal cell cancer: best recipient of tumor-to-tumor metastasis. *Urology* 1987;30(1):35-8.
7. Val-Bernal JF, Villoria F, Pérez-Expósito MA. Concurrent angiomyolipomas and renal cell carcinoma harboring metastatic foci of mammary carcinoma in the same kidney: an incidental autopsy finding in a patient with a follow-up of thirty years. *Ann Diagn Pathol* . 2001;5(5):293-9.
8. Hart IR. "Seed and soil" revisited: mechanisms of site-specific metastasis. *Cancer Metastasis Rev*. 1982;1(1):5-16.
9. Petraki C, Vaslamatzis M, Argyrakos T, Petraki K, Strataki M, Alexopoulos C, et al. Tumor to tumor metastasis: Report of two cases and review of the literature. *Int J Surg Pathol*. 2003;11(2):127-35.
10. Williams TR, Oakes MF. Metastatic breast carcinoma to renal angiomyolipomas in tuberous sclerosis. *Urology*. 2008;71(2):e57.