



# Management of Atlanto-axial Dislocation, A Case Based Approach: An Institutional Experience

Vernon Velho and Sachin Ashok Giri\*

Department of Neurosurgery, Grant Medical College & Sir J. J. Group of Hospitals, India

## Abstract

**Introduction:** Although many different techniques have been described for management of AAD, fixed or mobile varieties, no single technique is sufficient to manage all types of AADs as anatomical variations are many a times different in patients resulting in the tailoring the procedure for the associated deformity correction. Although radiological imaging allows diagnosis of abnormality, many times planned procedure is modified. In our series we describe the various techniques of management as well as rescue operations in case of failure of planned procedure.

**Methods:** It is a retrospective study extended over a period of 10 years i.e. from January 2007 to December 2017. The clinical parameters which were used are demographics, visual analogue scale for assessment of pain & Nurick's grading for neurological deficit. Apart from dynamic flexion & extension neck X-ray & CT scan, MRI craniovertebral junction, 3D CT angiogram of neck vessels was used for detailed anatomy & pathological assessment. In a patient with AAD associated with congenital anomalies, 3D print was used in perioperative period. Improvement in the neurological deficit is assessed & compared after 6 month follow up.

**Results:** Total 154 patients of AAD are operated over a period of 10 years. Most of these patients were presented with neck pain and occipital headache (86.5%) followed by mono or hemi or quadriparesis (66.7%). In initial period of experience, most of these patients were managed by simple sub-laminar techniques like Gallie's or Brooke's fusion technique. But with gain in experience, there is gradual shift to more robust construct techniques like C1 lateral mass and C2 pedicle screw and rod technique or occipito C2-C3 fusion technique or Magerl's technique. Vertebral artery injury occurred in two patients while placement of C1-C2 transarticular screw while one patient had a vertebral artery injury while placement of C2 pedicle screw. Though these techniques give more robust fixation, due to anatomical variation and intraoperative failure of planned procedure, other conventional and bailout techniques like occipitocervical fixation using Hartshill and sub-laminar wires or Writer's technique or Brooke's technique are used.

**Conclusion:** Each case of AAD has to be evaluated with CT images with 3D reconstruction. 3D printing aids in decision making and also in cases with congenital anomalies like Klippel-Feil syndrome where there is high risk of vertebral artery injury due to anomalous course. Though there are many techniques described for the management of AAD, it is essential to have all basic techniques in an armamentarium as these procedures may be useful as bailout techniques.

## Abbreviations

AAD: Atlanto Axial Dislocation; BI: Basilar Invagination; 3D CT: 3 Dimensional Computed Tomography; MRI: Magnetic Resonance Imaging; CMJ: Cervicomedullary Junction; CVJ: Craniovertebral Junction; CSF: Cerebrospinal Fluid; VA: Vertebral Artery

## Introduction

Atlantoaxial dislocation is one of the difficult pathology which has been managed by different techniques over a period of time. The atlantoaxial joints can lose stable articulation from traumatic, inflammatory, idiopathic, or congenital abnormalities. There was a gradual evolution in the diagnostic techniques as well as therapeutic modalities in past few years. There are many studies which describe the various operative techniques for the treatment of Atlantoaxial Dislocation (AAD). Most of the studies describe the C1-C2 fusion by posterior approach. There are some studies which dealt the AAD via anterior approach. But no particular study has determined which approach or technique is more effective in achieving the aims of AAD treatment, such as relieving cervicomedullary junction (CMJ) compression, restoring the normal alignment of CVJ with reconstruction of stability. Here

## OPEN ACCESS

### \*Correspondence:

Sachin Ashok Giri, Department of Neurosurgery, Grant Medical College & Sir J. J. Group of Hospitals, India, E-mail: sachingiri14@gmail.com

Received Date: 06 Dec 2018

Accepted Date: 21 Dec 2018

Published Date: 24 Dec 2018

### Citation:

Velho V, Giri SA. Management of Atlanto-axial Dislocation, A Case Based Approach: An Institutional Experience. Clin Surg. 2018; 3: 2274.

**Copyright** © 2018 Sachin Ashok Giri. This is an open access article distributed under the Creative Commons Attribution License, which permits unrestricted use, distribution, and reproduction in any medium, provided the original work is properly cited.

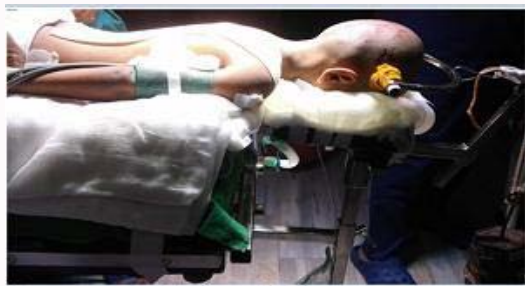

Figure 1: Cervical traction in neutral position using Gardner-wells tong.

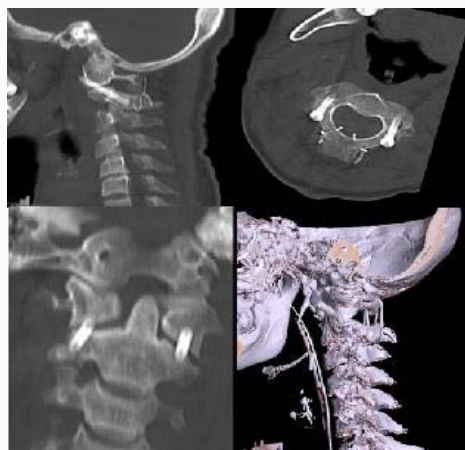

Figure 2: Magerl's technique of C1-C2 transarticular screw fixation.

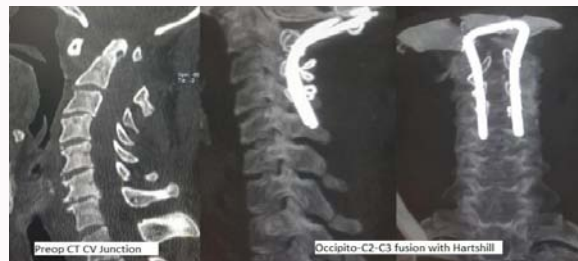

Figure 3: Occipitocervical fusion using Hartshill and sublaminar wires.

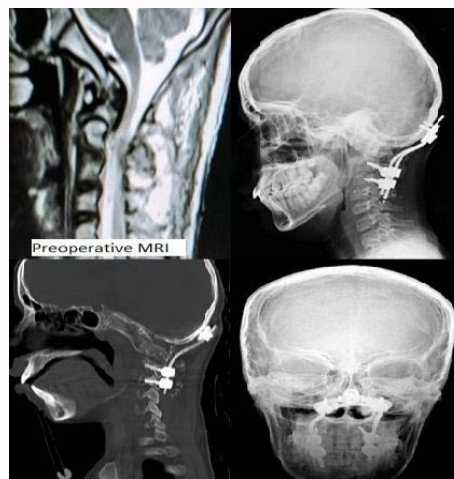


Figure 4: Occipito-C2-C3 fusion using plate, rod & screws construct.

we share our experience of ten years in the management of AAD which incorporates gradual evolvement of various techniques from sublaminar wiring to C1-C2 fusion using rod & screw construct.

## Materials and Methods

One fifty four patients with AAD (118 males and 36 females, aged 8 to 69 years with an average age of 38.7 years) underwent C1-C2 or occipito-C2-C3 fusion under general anesthesia (Table 1). Each surgical procedure was performed by the same experienced senior neurosurgeon. Our indication to perform surgery was neurologic deficit (myelopathy) with CMJ compression. The clinical presentations are summarized in Table 2. Neurologic deficit duration was between 6 and 55 months (average ~ 23 months). Anteroposterior, lateral and dynamic plain X-rays, Computed Tomography (CT) scans with 3D reconstruction views of CVJ, CT angiogram and Magnetic Resonance Imaging (MRI) were obtained in all patients preoperatively. Chamberlain, McRae, and Wackenheimer lines were surveyed, and all measured data met the diagnostic criteria of AAD with BI. Awake intubation using fiber-optic bronchoscope in neutral position was done in all patients. Skeletal traction was applied to all patients in neutral position (Figure 1). For mobile variety, C1-C2 fusion has done using sublaminar wiring (Brooke's technique) or transarticular screw placement (Magrel's technique). If there is significant anterior compression, transoral odontoidectomy performed followed by posterior fixation. For non-mobile variety, C1-C2 fusion carried out using C1 pars screw & C2 pedicle screws & rods (Goel&Harms). In patients, where screw placement failed, a C1-C2 sublaminar wiring with fixation was carried out. Occipito-cervical fixation with hartshill & wires was also used as a rescue operation. All of the patients were assessed clinically to observe neurologic recovery in terms of

improvement in Nurick's grade following surgery. Improvement in Nurick's grade was analyzed at 6 months interval. Complications were documented in the form of intraoperative, immediate & delayed ones.

## Results

Total 154 patients of AAD were operated in 10 year period with male to female ratio of 3.1:1. Most of these patients were between 10 to 30 years of age group. Main symptom at the presentation was neck pain & occipital headache (86.5%) followed by neurological deficit in the form of monoparesis or hemiparesis or quadriparesis (66.7%) (Table 2). Sensory abnormalities seen in 63.6% patients. Short neck, low hairline and limitation of neck motion is observed in 30.2%. Head tilt is observed in 42.6% patients. Most of the patients were in Nurick's grade 1 or 2 of neurological deficit (Table 3). At the initial phases of surgical management of AAD, most of the patients were managed by Gallie's fusion [1]. In Brooke's method of C1-C2 fusion, two bone grafts are fashioned to wedge between C1 & C2 after decortication of C1 arch & C2 lamina. But with gaining more experience, there was a gradual shift from sublaminar wiring technique to more robust construct like C1-C2 fusion using rods and screws over last few years (Table 4). In last 2 years, there were only 4 patients who were operated by Brooke's technique (Table 5). Out of these four patients, two patients had complex CV junction anatomy, one patient was switched from conventional C1-C2 screw & rod fixation to sublaminar wiring due to vertebral artery injury & one patient had a significant morbidity prompting to reduction in surgical time & selection of more simple & safer technique of sublaminar wiring. Out of 29 patients operated by sublaminar wiring, two patients had a dural tear intraoperatively which was managed

**Table 1:** Age distribution.

AGE	NUMBER OF PATIENTS	%
0-10	26	16.8
11-20	72	46.75
21-30	28	18.1
31-40	10	6.6
41-50	12	7.7
51-60	6	3.8
<b>TOTAL</b>	<b>154</b>	

**Table 2:** Presenting symptoms.

SYMPTOMS	%
short neck, low hairline and limitation of neck motion	30.2
Head tilt	42.6
Sensory abnormalities	63.6
Webbed neck	26.4
Neck pain and posterior occipital headache	<b>86.5</b>
Quadri/para/monoparesis	<b>66.7</b>
Repeated aspiration pneumonia, dysphagia	26.2
Sleep apnea ,hearing loss	19.6
attacks of altered consciousness, transient loss of visual fields, confusion, vertigo	25.8

**Table 3:** Preoperative deficit.

Weakness (Nurick myelopathy grading)	Pre-operative	No. of patients %
Grade 0	13	8.4
Grade 1	43	27.9
Grade 2	48	31.1
Grade 3	24	15.5
Grade 4	18	11.6
Grade 5	8	5.1

**Table 4:** Surgeries over last 10 years.

Surgery	No. of cases	Percentage %
Gallie's Fusion	6	3.8
Brooke's fusion	23	14.9
Transarticular screw fixation	15	9.7
Lateral Mass /Transpedicular screw Fixation	25	<b>18.83</b>
Pars screw fixation	10	6.4
Translaminar screw fixation	11	7
Occipito cervical fixation Using Hartshill and wires	35	<b>22.7</b>
Occipito-Cervical fixation using occipital plate and screws	12	7.7
Transoralodontoidectomy with O-C2/C3 fixation	34	22

successfully without any postoperative complication. Transarticular screw i.e. Magrel's technique was used in 11 patients with mobile variety of AAD. Most of these patients treated by this method were having incompetent posterior arch. This technique was deferred in patients with abnormal medial course of vertebral artery. All patients with transarticular screw fixation are supplemented with Brooke's sublaminar wiring procedure (Figure 2) for added stability [2-4]. C2 translaminar & C1 pars screw fixation (Wright's technique) done in five patients. This method of fusion was used as salvage technique

**Table 5:** Surgeries in last 2 years.

Surgery	No of cases (n=28)	Percentage (%)
Gallie's Fusion/Brooke's fusion	4	14
Transarticular screw fixation	1	3.5
C1 pars & C2 Lateral Mass /Transpedicular screw Fixation	11	<b>39.2</b>
Translaminar screw fixation	0	0
Occipito cervical fixation using Hartshill plate and wires	5	17.8
Occipito-Cervical fixation using occipital plate and screws	2	7
Transoralodontoidectomy with O-C2/C3 fixation	5	17.8

**Table 6:** Complications.

COMPLICATIONS IMMEDIATE	No. of patients	Percentage
Worsening of myelopathy	12	7.8
Sensory deterioration	5	3.2
Respiratory distress	4	2.4
Death	1	0.6
<b>DELAYED</b>		
Wound infection managed conservatively	7	4.5
Infection that required implant removal	1	0.6
Implant Failure	5	3.2
Death	2	1.2

in four patients because of failure to achieve C1-C2 fusion using C2 pedicle screw [5]. Three patients out of these five patients had pedicle breach medially and in two patients, there was a suspicion of vertebral artery injury. In our series, 35 patients underwent occipitocervical fusion using Hartshill (Figure 3) & wires while 12 patients underwent occipitocervical fusion using plate, rod& screws construct (Figure 4). Over a past two years, there is switch from the all of the above techniques to C1 pars & C2 pedicle screw & rod fixation as it is found to provide more biomechanical stability, relieving cervicomedullary junction compression & restoring normal alignment of CVJ. In addition, this technique can still be utilized in cases where there is aberrant vertebral artery course. Total 31 cases were operated by this technique using polyaxial screws & rods. Bilateral C2 ganglia were sacrificed in all these patients to provide wide exposure to the region without any complications.

Thirty four patients required trans-oral odontoidectomy for significant anterior compression. All these patients underwent posterior fusion in same sitting either by occipito-C2-C3 fusion or C1-C2 fusion by Goel & Harm's technique (Figure 5). Total three patients had a vertebral artery injury, two of which were managed successfully using interventional technique by sacrificing the injured vertebral artery. But one patient expired due to significant vascular compromise. Three patients had a dural tear, two of which developed during the passage of sublaminar wire while one patient developed CSF leak following placement of transarticular screw. Two patients had excessive blood loss secondary to vertebral venous plexus injury for which blood transfusion was required. Both these patients improved in postoperative period. Worsening of myelopathy was observed in 12 patients in immediate postoperative period. On retrospective assessment, most of these patients were in Nurick's grade IV or V. Sensory deterioration was observed in five patients. But all of these patients were improved during follow up period. Four patients required prolonged ventilator support due to respiratory



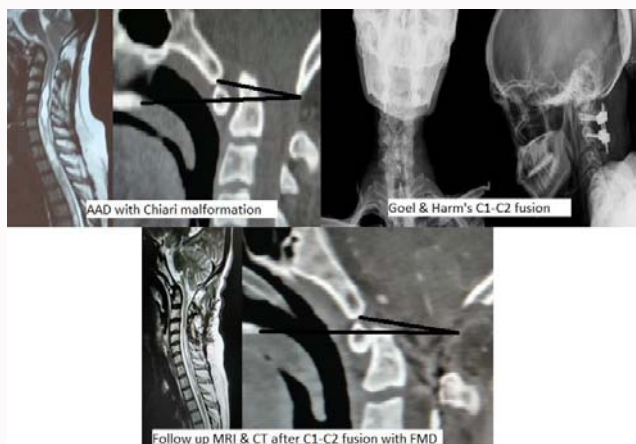


Figure 5: C1-C2 fusion by Goel & Harm's screw and rod construct.

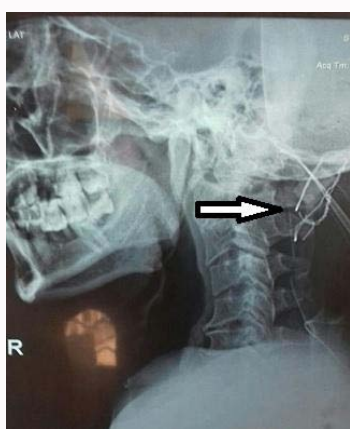

Figure 6: Follow up case of breakage of sublaminar wire.

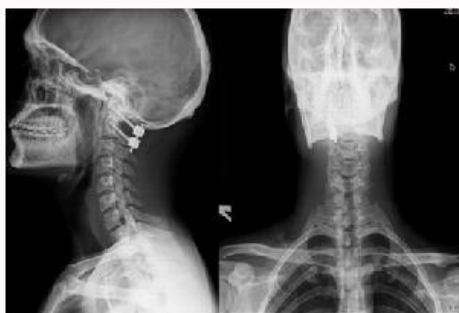

Figure 7: Unilateral C1-C2 fusion due to vertebral artery injury.

distress. Eight patients had wound infection, seven of which were managed conservatively while one patient had undergone Hartshill implant removal. This patient was managed without re-implantation as there was evidence of C1-C2 fusion in follow up period. Five patients had implant failure. Four of which are wire related & one due to failure of C1 pars screw. Three out of four patients had breakage of sublaminar wire (Figure 6) while one patient had a breakage of wire used for Hartshill fixation.

Two patients died in follow up period by cause unrelated to the procedure & twelve patients lost to follow up period (Table 6). There was significant improvement in the visual analogue scale in patients having moderate to severe neck pain in follow up period of

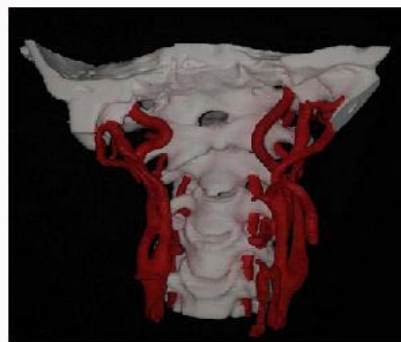


Figure 8: 3D print for preoperative evaluation of CV junction anatomy.

Table 7: Neck pain (Visual analogue scale) at 6 month follow up.

Clinical features NECK PAIN (visual analog scale)	Pre-operative		Post-operative	
	No. of patients	Percentage	No. of patients	Percentage
Mild	95	61.7	21	13.6
Moderate	34	22	6	3.8
Severe	12	7.7	0	0

Table 8: Nurick's grading (Grid) at 6 months follow up.

5→5 1	4→5 4	3→5 3	2→5 0	1→5 0	0→5 0
5→4 0	4→4 2	3→4 6	2→4 8	1→4 2	0→4 0
5→3 0	4→3 1	3→3 4	2→3 6	1→3 12	0→3 1
5→2 0	4→2 1	3→2 2	2→2 3	1→2 10	0→2 32
5→1 0	4→1 0	3→1 1	2→1 2	1→1 5	0→1 35
5→0 0	4→0 0	3→0 0	2→0 0	1→0 1	0→0 12

Table 9: Improvement following surgery.

Improved by 2 grades	58	37.60%
Improved by 1 grade	61	39.60%
Same as pre op	15	9.70%
Deteriorated	8	5.10%

six months (Table 7). 119 patients showed improvement in Nurick's grade in six month follow up period while 14 patients remained same as preoperative status. Eight patients found to be deteriorated in post-operative follow up period (Table 8, 9). 11 patients out of 14 who were remained same were primarily treated by sublaminar wiring & three were treated by occipito-C2-C3 fusion. Six out of eight patients who had deteriorated were having traumatic atlanto-axial dislocation & were not found to be associated with any specific mode of surgery. Two of three patients who had vertebral artery injury while placement of transarticular screws while one patient had a vertebral artery injury while placement of C2 pedicle screw. In this patient, screws are placed only on the side of vertebral artery injury & procedure abandoned for further evaluation of injured vertebral artery (Figure 7).

### Discussion

Surgical treatments are required in most of the patients with atlanto-axial dislocation with continuing neurological deficit [6-13]. Though there is improvements in the surgical techniques have brought some encouraging results over the years, there is no agreement among specialists regarding the appropriate surgical procedures that should be used for treating CVJ anomalies and reconstructing

stability. Simple posterior sublaminar wiring techniques require an intact posterior arch of C1 and C2. They cannot be utilized if there are fractures of the C1 or C2 posterior elements (including Hangman's or Jefferson's fracture), or if posterior decompression of the C1-C2 complex is required, or if there is significant osteoporosis. When we perform posterior wiring techniques, we prefer to use double braided titanium wires because they are more flexible than steel wire and have less chance of causing dural or neural injury.

Gallie in 1939 first described posterior C1-C2 sublaminar wire fixation with the use of steel wire [1]. In the Gallie technique, a single autograft harvested from the iliac crest is notched inferiorly and placed between the C2 spinous process and the posterior arch of C1. The graft is held in place by a sublaminar steel wire that passes beneath the C1 arch and then wraps around the spinous process of C2. By avoiding the Passage of the sublaminar wire under the lamina of C2, there is decrease the risk of neural or dural injury. There is increased rate of non-union in Gallie fusion up to 25% since it offers good stability only in flexion & extension and there is poor stability in rotational maneuvers [14]. Unlike Gallie fusion technique, in Brooks and Jenkins fusion, two separate iliac grafts are obtained & wedged between C1 arch and C2 lamina on either side of the midline. These grafts are then secured in place by placing the sublaminar cables on each side wrapping around these grafts. The cables are then tightened around the grafts and crimped in place. This technique not only provides stability in flexion and extension but also more rotational stability than Gallie's fusion technique. Therefore this procedure has more fusion rate as high as 93% and is improved by halo immobilization [15-18]. But there is increased risk of dural tear or neurological injury in this procedure as compared to Gallie's, because two wires are passed beneath the C1 arch and C2 lamina [16]. Transarticular screw fixation was first described by Roy Camille in 1972 [19]. But it is popularized by Magerl & Jeanneret. In 1979, Magerl described this technique for odontoid fractures. But it has widely being used for C1-C2 inflammatory disease, infections, congenital anomalies and acquired postsurgical deformities [2,3]. The main advantage of this technique is complete obliteration of rotational movement at C1-C2 joint. As these screws provide adequate internal immobilization, external immobilization is not required. Disadvantage of this technique is steep learning curve and there is a risk of vertebral artery injury, spinal cord or hypoglossal nerve injury. This risk significantly increases in patient with anomalous vertebral artery course. This risk can be minimized by doing preoperative CT angiogram of neck vessels [19-21]. If vertebral artery gets injured, screw placement is proceeded to achieve tamponade effect. But screw placement on contralateral side is abandoned. Patient shifted to angiosuite for confirmation and sacrifice of the affected vertebral artery. If there is preoperative diagnosis of aberrant vertebral artery, transarticular screw placement is carried out only on the side with normal vertebral artery course.

In Magerl's technique, lateral fluoroscopy used while placement of screws though some advocates biplane fluoroscopy. Exposure is done from occiput to C3 lamina and two small paramedian incisions are taken at D1-D2 level around 2 cm to 3 cm off midline for placement of transarticular screws. Lateral dissection is carried out to the lateral aspect of C2 lamina after exposing C1 arch. C1-C2 facet joint is curated to facilitate the bony arthrodesis. Entry point is 2 mm medial and 2 mm cranial to the midpoint of C1-C2 facet joint with 20 to 25 degrees of lateral trajectory. Cranio-caudal angulation is determined by inserting the probe into the joint which is generally parallel to the

facet joint. This trajectory can be achieved by separate small incisions around D1-D2 level, around 2mm to 3 mm off midline. A pilot hole is drilled under vision and trajectory is maintained towards the C1 lateral mass under fluoroscopic guidance. If there is translational misalignment between C1-C2, it is corrected using towel clips before drill crosses C1-C2 facet joint. Pilot hole is then tapped and fully threaded titanium screws are placed. Transarticular screw placement is followed by posterior fusion using Brooks and Jenkins technique or Dickman-Sonntag posterior interspinous wiring procedure for added stability [2-4,22]. Placement of polyaxial mini screws in C1 lateral mass and C2 pedicle with rod fixation. Originated by Goel and Laheri [11] in 1994 and promulgated in 2001 by Harms and Melcher [23]. There are advantages of this technique over transarticular technique as there is reduced risk of vertebral artery injury due to more superior and medial trajectory of the screw. This technique can be used in some cases of aberrant VA course. Goel's technique may be used in the presence of C1-C2 subluxation. Another advantage of this technique is that alignment of C1-C2 complex is not necessary prior to instrumentation. C1-C2 complex completely exposed. Dissection carried out over the superior surface of the C2 pars interarticularis to expose the C1-2 joint to locate the entry point for the C1 pars screws. Bleeding from the perivertebral venous plexus is controlled with bipolar cautery and surgical or gelfoam. Goel et al. have reported that sacrifice of the C2 ganglion provides a wide exposure to the region for the conduct of the surgery and does not lead to any significant neurological symptom. The screw entry point is the midpoint of the inferior part of the C1 pars interarticularis (for both mediolateral and cranio-caudal directions). An all or a 1 mm to 2 mm high-speed drill is used to mark the position to prevent slippage while drilling the hole. Drilling a portion of the inferior arch of C1 is sometimes needed to allow screw placement. As the thickness of the arch in the cranio-caudal dimension varies widely, and the horizontal segment of the VA lies immediately above – use pre-op CT for planning. C1 screw trajectory averages  $\approx 17^\circ$  medially,  $\approx 22^\circ$  rostrally, targeting the superior aspect of the anterior tubercle of C1 on lateral fluoro. C1 screws are 3.5 mm or 4 mm diameter, length is determined from pre-op fine-cut CT to obtain bicortical purchase some authors use only unicortical purchase). It may actually be necessary to have the C1 screw protruding 1 mm to 2 mm more than the C2 screw in order to allow rod attachment [24]. The entry point for the C2 pars screws 3 mm rostral and 3 mm lateral to the inferior medial aspect of the inferior articular surface of C2. The screw follows a steep trajectory paralleling the C2 pars (Often 40 degrees or more). The screws are passed with 10 degrees of medial angulation. Screw length is typically 16 mm, which often stops short of the transverse foramen. Preoperative CT study with angiography or 3D print (Figure 8) is helpful to identify the unusual location of foramen transversarium or aberrant vertebral artery course as in patients with congenital anomalies like Klippel-Feil syndrome. Vertebral artery injury is still a risk with C2 pars screws but the risk is not as high as with transarticular screws. If a fusion is to be performed: the posterior arch of C1 and the C2 lamina are decorticated with a drill. Only fusion substrate is then placed, taking care not to compress the dura. Joint surface is drilled and bone is packed within the C1-2 joint.. Coagulation around C2 ganglion can prevent venous bleeding. Cutting C2 ganglia facilitates opening and packing the C1-C2 joint with bone. Stepped approach with 2 mm drill bit under fluoroscopic guidance helps in preventing wrong trajectory for screw placement. Occipitocervical fusion technique can be carried out using Hartshill & sublaminar wires or by occipital keel plate, screw and rod construct. In Hartshill and sublaminar wire fusion

technique avoids vertebral artery injury and relatively easier bail out technique if there is difficulty in placement of C1-C2 screws or due to abnormal anatomy at CV junction. In this technique, Hartshill is moulded according curvature at the CV junction in neutral position and is fixed translaminar screws [25, 26] 1 year stability appears to be less than C2 pedicle screws when used for subaxial fusions, but was as effective for axial fusions (C1-2 or C1-3) [27]. May be useful as a "bailout" for subaxial fusions when the C2 pars diameter is too small for pedicle screws or if there is pedicle compromise during C2 screw placement [27].

## Conclusion

Each case of AAD has to be evaluated with CT images with 3D reconstruction. 3D printing aids in decision making and also in cases with congenital anomalies like Klippel-Feil syndrome where there is high risk of vertebral artery injury due to anomalous course. Though there are many techniques described for the management of AAD, it is essential to have all basic techniques in an armamentarium as these procedures may be useful as bailout techniques.

## References

- Gallie WE. Fractures and Dislocation of the Cervical Spine. *Am J Surg.* 1939;46:495-99.
- Haid RW Jr. C1-C2 transarticular screw fixation: technical aspects. *Neurosurgery.* 2001;49(1):71-4.
- Haid RW, Subach BR, McLaughlin MR, Rodts GE, Wahlig JB. C1-C2 Transarticular Screw Fixation for Atlantoaxial Instability: A Six-Year Experience. *Neurosurg.* 2001;49(1):65-70.
- Fiore AJ, Haid RW, Rodts GE, Subach BR, Mummaneni PV, Riehl CJ, et al. Atlantal lateral mass screws for posterior spinal reconstruction: technical note and case series. *Neurosurg Focus.* 2002;12(1):E5.
- Wright NM. Posterior C2 fixation using bilateral, crossing C2 laminar screws: case series and technical note. *J Spinal Disord Tech.* 2004;17(2):158-62.
- Jian F-Z, Chen Z, Wrede KH, Samii M, Ling F. Direct posterior reduction and fixation for the treatment of basilar invagination with atlantoaxial dislocation. *Neurosurgery.* 2010;66(4):678-87.
- Smith JS, Shaffrey CI, Abel MF, Menezes AH. Basilar invagination. *Neurosurgery.* 2010;66(3 Suppl):39-47.
- Guo SL, Zhou DB, Yu XG, Yin YH, Qiao GY. Posterior C1-C2 screw and rod instrument for reduction and fixation of basilar invagination with atlantoaxial dislocation. *Eur Spine J.* 2014;23(8):1666-72.
- Chandra PS, Kumar A, Chauhan A, Ansari A, Mishra NK, Sharma BS. Distraction, compression, and extension reduction of basilar invagination and atlantoaxial dislocation: a novel pilot technique. *Neurosurgery.* 2013;72(6):1040-53.
- Menezes AH. Surgical approaches: postoperative care and complications "transoral-transpalatopharyngeal approach to the craniocervical junction". *Childs Nerv Syst.* 2008;24(10):1187-93.
- Goel A. Treatment of basilar invagination by atlantoaxial joint distraction and direct lateral mass fixation. *J Neurosurg Spine.* 2004;1(3):281-6.
- Peng X, Chen L, Wan Y, Zou X. Treatment of primary basilar invagination by cervical traction and posterior instrumented reduction together with occipitocervical fusion. *Spine (Phila Pa 1976).* 2011;36(19):1528-31.
- Dasenbrock HH, Clarke MJ, Bydon A, Sciubba DM, Witham TF, Gokaslan ZL, et al. Endoscopic image-guided transcervical odontoidectomy: outcomes of 15 patients with basilar invagination. *Neurosurgery.* 2012;70(2):351-9.
- Coyne TJ, Fehlings MG, Wallace MC, Bernstein M, Tator CH. C1-C2 posterior cervical fusion: long-term evaluation of results and efficacy. *Neurosurgery.* 1995;37(4):688-92.
- Brooks AL, Jenkins EB. Atlanto-axial arthrodesis by the wedge compression method. *J Bone Joint Surg Am.* 1978;60(3):279-84.
- Smith MD, Phillips WA, Hensinger RN. Complications of fusion to the upper cervical spine. *Spine (Phila Pa 1976).* 1991;16(7):702-5.
- Grob D, Crisca JJ III, Panjabi MM, Wang P, Dvorak J. Biomechanical Evaluation of Four Different Posterior Atlantoaxial Fixation Techniques. *Spine.* 1992;17(5):480-90.
- Dickman CA, Sonntag VK, Papadopoulos SM, Hadley MN. The Interior Spinous Method of Posterior Atlantoaxial Arthrodesis. *J Neurosurg.* 1991;74(2):190-98.
- Madawi AA, Casey AT, Solanki GA, Tuite G, Veres R, Crockard HA. Radiological and anatomic evaluation of the atlantoaxial transarticular screw fixation technique. *J Neurosurg.* 1997;86(6):961-68.
- Paramore CG, Dickman CA, Sonntag VK. The anatomical suitability of the C1-2 complex for transarticular screw fixation. *J Neurosurg.* 1996;85(2):221-4.
- Wright NM, Lauryssen C. Vertebral artery injury in C1-2 transarticular screw fixation: results of a survey of the AANS/CNS section on disorders of the spine and peripheral nerves American Association of Neurological Surgeons/Congress of Neurological Surgeons. *J Neurosurg.* 1998;88(4):634-40.
- Mummaneni PV, Haid RW. Atlantoaxial fixation: overview of all techniques. *Neurol India.* 2005;53(4):408-15.
- Goel A, Karapurkar AP. Transoral plate and screw fixation of the craniovertebral region--a preliminary report. *Br J Neurosurg.* 1994;8(6):743-5.
- Rocha R, Safavi-Abbasi S, Reis C, Theodore N, Bambakidis N, de Oliveira E, et al. Working area, safety zones, and angles of approach for posterior C-1 lateral mass screw placement: a quantitative anatomical and morphometric evaluation. *J Neurosurg Spine.* 2007;6(3):247-54.
- Wright NM. Posterior C2 fixation using bilateral, crossing C2 laminar screws: case series and technical note. *J Spinal Disord Tech.* 2004;17(2):158-62.
- Jea A, Sheth RN, Vanni S, Green BA, Levi AD. Modification of Wright's technique for placement of bilateral crossing C2 translaminar screws: technical note. *Spine J.* 2008;8(4):656-60.
- Parker SL, McGirt MJ, Garcés-Ambrossi GL, Mehta VA, Sciubba DM, Witham TF, et al. Translaminar versus pedicle screw fixation of C2: comparison of surgical morbidity and accuracy of 313 consecutive screws. *Neurosurgery.* 2009;64:343-8.