



## Long Term Clinical and Functional Outcome of Lateral Supramalleolar Flap for Soft Tissue Coverage of Foot and Ankle Defects: Largest Case Series at a Tertiary Care Hospital

Pervaiz Mehmood Hashmi<sup>1\*</sup>, Kamran Ahmed S<sup>2</sup>, Muhammad Ali<sup>3</sup>, Abeer Musaddiq<sup>4</sup> and Alizah Hashmi<sup>4</sup>

<sup>1</sup>Department of Hand & Reconstructive Microvascular Surgery, Aga Khan University Hospital, Pakistan

<sup>2</sup>Department of Orthopedics, Indus Hospital, Karachi, Pakistan

<sup>3</sup>Musculoskeletal Service Line, Aga Khan University Hospital, Karachi, Pakistan

<sup>4</sup>Aga Khan University Hospital, Karachi, Pakistan

### Abstract

**Background:** Reconstruction of defects around foot and ankle is challenging issue. We wanted to assess the clinical and functional outcome of lateral supramalleolar flap for coverage soft tissue defects around the foot and ankle.

**Methods:** This analytic case series was conducted at Aga Khan University Hospital, Karachi. The data was collected from medical records and patient interviewing. Patients with soft tissue defects around foot and ankle and coverage with supramalleolar flaps were included. The various parameters of interest (causes, flaps dimensions, vascular variations, and outcome) were included in the prestructured proforma the data was analyzed with SPSS version 25.

**Results:** Forty-seven patients were included in the study from May 1999 to December 2019. The male to female ratio was 35:12. The mechanism of injury was varied. Eighteen cases were pedicle island flaps whereas two were peninsular rotation flaps. The maximum flap size harvested was 20 cm × 8 cm distal flap necrosis occurred in one patient requiring split thickness skin graft. In eight patients' flap was rotated as 'delay flap'. In 12 cases the peroneal artery perforator was absent, the flap being based on inferolateral collateral artery from anterior tibial artery. Majority of the patients fall in excellent category based on self-designed assessment tool.

**Conclusion:** The lateral supramalleolar flap provided coverage to almost all regions of the foot and ankle with a cosmetically acceptable donor and recipient site. There were no problems with shoe wear, only two patients requiring defatting for cosmetic reasons. Microvascular expertise was required for a predictable outcome.

**Keywords:** Supramalleolar flap; Peroneal artery perforator; Fasciocutaneous flap; Foot and ankle; Soft tissue defect

### Introduction

Soft tissue defects around foot and ankle commonly occur as a result of Road Traffic Accidents (RTA) that may involve bone, tendon and neurovascular structures [1]. Other causes include blast injuries, machine/industrial injuries, resection of tumors, and neuropathic ulcers [2]. The incidence of such injuries in Karachi (an industrial and heavily populated city), is quite high because of a poor roads traffic system (the city ranked 4<sup>th</sup> in road traffic accidents in the world [3]). Road traffic accidents, gunshot and bomb blast injuries frequently lead to open fractures with skin loss. Similarly, cases of chronic osteomyelitis, chronic burns, tumor excision and skin necrosis due to irradiation around the foot and ankle require soft tissue coverage. Such cases present very late and are commonly associated with infections. These cases pose a great challenge due to underlying infections, limited local soft tissue availability and need for secondary reconstruction of involved structures (bone, tendon nerves and vessels). These wounds require staged reconstruction; initial skeletal stabilization followed by coverage with thin, pliable soft tissue and subsequent repair/reconstruction of tendon,

### OPEN ACCESS

#### \*Correspondence:

Pervaiz Mehmood Hashmi, Department of Surgery, Hand & Reconstructive Microvascular Surgery, Aga Khan University Hospital, P.O. Box: 3500, Stadium Road, Karachi, Pakistan, Tel: 92 3452105652; Fax: 92 21 34934294; E-mail: Pervaiz.hashmi@aku.edu

Received Date: 17 Sep 2020

Accepted Date: 08 Oct 2020

Published Date: 15 Oct 2020

#### Citation:

Hashmi PM, Kamran Ahmed S, Ali M, Musaddiq A, Hashmi A. Long Term Clinical and Functional Outcome of Lateral Supramalleolar Flap for Soft Tissue Coverage of Foot and Ankle Defects: Largest Case Series at a Tertiary Care Hospital. *Clin Surg.* 2020; 5: 2976.

**Copyright** © 2020 Pervaiz Mehmood Hashmi. This is an open access article distributed under the Creative Commons Attribution License, which permits unrestricted use, distribution, and reproduction in any medium, provided the original work is properly cited.

bone and neural tissue for restoration of limb functions [4,5].

Reconstruction of soft tissue defects of the foot and ankle depends on the location, size, and depth of wound. Various local available options include local muscle flap, fasciocutaneous flap, perforator flap, metatarsal artery flap, sural artery flap and supramalleolar flap [6,7].

Free skin grafts are often unsuitable because of their tendency to contract and poor resistance to pressure. Local skin flaps would be preferable but are relatively small and have limited range and reliability [7]. Further compromise of a major vessel of the leg, like the anterior tibial or posterior tibial artery, is not always desired. Local muscle flaps like flexor digitorum brevis and abductor hallucis longus are often inadequate to reach problem areas like the heel, tendoachilles and perimalleolar region. Cross leg flaps require immobilization in cumbersome positions and free flaps have their own merits and demerits. Lateral supramalleolar flap described by Yoshimura and Masquelet [8,9] is a very good option to cover the defect around the dorsum of foot, ankle and perimalleolar area. This flap is based on the last perforator of peroneal artery that pierces the interosseous membrane just above the ankle syndesmosis and becomes continuous with anterolateral malleolar artery. The cutaneous branch of this perforator supplies the skin over the anterolateral aspect of lower one third of leg. Masquelet [9] in 1988 described the lateral supramalleolar fasciocutaneous flap based on cadaveric and patient study. Without compromise to the major blood vessels of the foot, including the peroneal artery, this flap has proved to be a reliable fasciocutaneous flap for the loco regional coverage of distal third of the leg, ankle, perimalleolar region, dorsum and plantar aspect of foot [9-11], except the weight bearing region of the heel [10,12,13] as the flap is insensate and relatively thin. It can be a rather large flap (15 cm × 8 cm in clinical series [9] and 22 cm × 9 cm in dye injection studies in fresh cadavers [14]). The pedicle of the flap is long (8.0 cm in rotation flaps [9] to 15 cm in distally based flaps with compound pedicle [10]) and the pivot point of pedicle is sinus tarsi, which increases the arc of rotation. The flap is most commonly employed as a distally based pedicle island flap.

We did a retrospective analysis of supramalleolar flaps done for coverage of defects around the foot and ankle by a single surgeon over a period of 20 years from May 1999 to December 2019. The main objective of our study was to evaluate the clinical and functional outcomes of lateral supra-malleolar flap in terms of viability, coverage of defect, cosmetic appearance and functions of the foot and ankle.

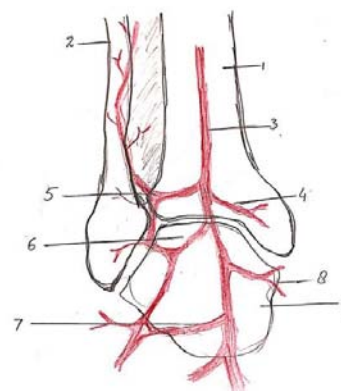
## Patients and Methods

This was an analytical case series; all cases done by a single surgeon from May 1999 to December 2019, and included all the patients who required soft tissue coverage for defects around the foot and ankle. Data was collected through a structured proforma that included demographic parameters, causes of soft tissue defects, (secondary to open fractures, following debridement for chronic osteomyelitis, infected fractures, infected non-unions, tumor excision, pressure sores and scar contracture as a result of old burns), site of defect, size and type of flap (peninsular, antegrade, retrograde), per-operative findings, presence or absence of peroneal perforator and inferolateral collateral artery, complications and outcome of flap. The data was collected from medical records and patient interviewing. The patients with advanced peripheral vascular disease, advanced diabetes mellitus, unavailability of skin, very large skin defects, radiation injuries, defects

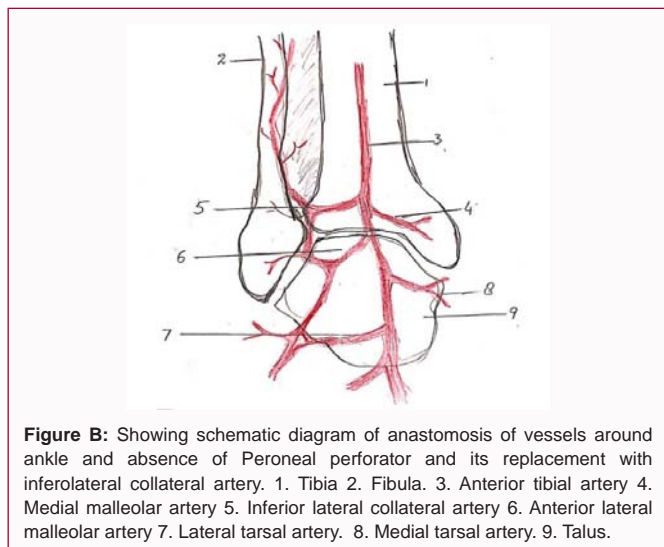
of the weight bearing region of the heel and defects reconstructed with other flaps were excluded from the study. All the patients were operated by one surgeon and loupe magnification used in all cases. No preoperative Doppler or angiography was done to assess the state of vascular pattern of the flap. The protocol of study was approved from Departmental Research Committee (DRC) and ethical review committee ERC. The final clinical and functional assessment was done by two research officers based on a self-assessment tool. This tool has four major parameters of assessment: percentage of coverage of defect by flap, cosmetic appearance, weight bearing status and Activities of Daily Life (ADL). The data was analyzed in SPSS version 25.

## Dissection technique

The patient is placed supine with a sand bag under the buttock and pneumatic tourniquet on the thigh. The skin island is planned according to the defect. The distal limit should include the point of emergence of the perforating branch of the peroneal artery, four finger breadths above the lateral malleolus. The proximal limit reaches the mid leg. The anterior limit is the tendon of the tibialis anterior muscle and the posterior limit should not cross the posterior border of the fibula. Then an incision is drawn anterior to the lateral malleolus and reaches to the depression of the sinus tarsi on the lateral aspect of the hind foot. First the anterior margin of the flap is elevated, isolating the pedicle lying on the tibiofibular ligament. The superficial peroneal nerve is divided proximal to the flap and buried in the muscles. The pedicle is exposed. The posterior margin of the flap is then elevated. At this stage the flap remains attached only to the septum between the anterior and lateral compartments. The perforating branch of the peroneal artery is then clamped temporarily to see the adequacy of retrograde flow in the skin island (Figure A). If the flow is good, then the perforator is ligated proximal to the emergence of skin perforators. If the flow is deemed unsatisfactory, the flap is sutured back on the bed and delayed for 48 h. In the end the septum is incised sub-periosteally and the flap rotated as a distally based pedicle island to the required defect. Release of the pedicle up to the sinus tarsi enhances rotation by adding length to the pedicle. Division of the fascia on the posterior border of extensor digitorum brevis helps to avoid compression on the pedicle. The closure of the donor site is achieved by suturing the peroneal and extensor muscles together. A split thickness skin graft is usually required for coverage of the donor site defect. In case of peninsular rotation flap, the pedicle may not need exposure, and the



**Figure A:** Showing schematic diagram of anastomosis of vessels around ankle and presence of Peroneal perforator. 1. Tibia 2. Fibula. 3. Peroneal perforator. 4. Anterior tibial artery. 5. Anterior lateral malleolar artery. 6. Talus 7. Lateral tarsal artery. 8. Medial malleolar artery 9. Medial tarsal artery.



**Figure B:** Showing schematic diagram of anastomosis of vessels around ankle and absence of Peroneal perforator and its replacement with inferolateral collateral artery. 1. Tibia 2. Fibula. 3. Anterior tibial artery 4. Medial malleolar artery 5. Inferior lateral collateral artery 6. Anterior lateral malleolar artery 7. Lateral tarsal artery. 8. Medial tarsal artery. 9. Talus.

flap rotated on a distal hinge. Similarly, for coverage of very distal defects on the bases of toes, a flap based on compound pedicle can be harvested. In case of absent peroneal perforator, the flap may be based on antegrade circulation from inferolateral collateral artery, a branch of the anterior tibial artery.

## Results

There were 47 patients included in the study out of 51 with a male to female ratio of 35:12; 4 patients could not be traced for final follow up analysis. The mean age of patients was 31.04 years ranging from 4 to 77 years. The average follow up time period ranged from 8 months to 20 years, average being 13 years. Right to left side ratio was 26:21. Table 1 represents the results.

Trauma was the major cause of soft tissue defect in 18 cases, followed by infections in 15, blast injuries in 5, tendoachilles coverage in 4, contracture release in 3 and coverage of tumor defect in 2 cases. The various sites reconstructed with lateral supramalleolar flaps were: Dorsum of foot in 24 cases, ankle in 12 and around the heel in 11 cases. See Table 1 distal partial thickness flap necrosis occurred in 1 case, in which adipose-fascia survived and split thickness skin grafting served the purpose. Flap tip necrosis occurred in 5 cases that healed with re-epithelialization without intervention. Hematoma formation in 1 case required drainage by removal of couple of sutures and went on to healing with excellent result. Significant venous congestion occurred in 4 cases requiring suture removal and later re-suturing after 48 h. Distal wound dehiscence occurred in one case due to already present infection by gram negative rods, requiring debridement and re-suturing of the flap. In 8 cases the flap was retained on the donor bed after harvesting due to doubtful circulation on rotation to the recipient area. All these flaps were rotated electively as 'DELAY FLAPS' to the recipient area after 48 h. In 12 patients the peroneal artery perforator was absent and the flap was based on antegrade circulation from inferolateral collateral artery, a branch of the anterior tibial artery. These cases of flaps based on inferolateral collateral artery from anterior tibial artery did not have any complications like venous congestion, flap tip/partial necrosis. The complications of congestion, flap tip and/or partial necrosis were noted in those cases (9 out of 35) where peroneal perforator was present.

The maximum flap size harvested was 20 cm × 8 cm which is larger than harvested by Masquelet AC (15 cm × 8 cm) in his clinical series

**Table 1:** Clinical summaries of 47 patients.

| S.no | Variables                        |                                      | No. (%)      |
|------|----------------------------------|--------------------------------------|--------------|
| 1    | Gender                           | Male                                 | 35 (74.5%)   |
|      |                                  | Female                               | 12 (25.5%)   |
| 2    | Age                              | Mean ± SD (in years)                 | 31.04 ± 20.6 |
| 3    | Mechanism of injury              | Trauma                               | 18 (38.3%)   |
|      |                                  | Tumor                                | 2 (4.3%)     |
|      |                                  | Blast injury                         | 5 (10.6%)    |
|      |                                  | Infection                            | 15 (32%)     |
|      |                                  | For Contracture release              | 3 (6.4%)     |
|      | For TA coverage s/p repair of TA | 4 (8.5%)                             |              |
| 5    | Flap Size                        | Mean in cm (L+B)/2                   | 9.15 ± 1.6   |
| 6    | Complications                    | Tip necrosis                         | 4 (8.5%)     |
|      |                                  | Infections                           | 2 (4.3%)     |
|      |                                  | Venous Congestions                   | 3 (6.4%)     |
|      |                                  | Venous congestion + partial necrosis | 1 (2.1%)     |
|      |                                  | No Complications                     | 37 (78.7%)   |
|      |                                  |                                      |              |
| 7    | Flap Survival                    |                                      | 98%          |

[9]. The average operating time was 60 min to 90 min and the donor site was covered with split thickness skin graft in the same setting. There was no flap failure. Two patients required de-fattening of the flap for cosmetic reasons. The donor site was cosmetically acceptable to majority of the patients.

We evaluated results of our patients based on four parameters: Coverage of defects in terms of percentage, cosmetic appearance, weight bearing status and Activities of Daily Living (ADL). Each parameter was divided into four grades: Excellent, good, fair and poor and each grade was given a specific number. 5, 4, 3, and 2 points respectively. (Refer to (Table 2)) An excellent grade on all accounts had the maximum points of 20, so 17 to 20 was graded as excellent, 13 to 16 as good, 9 to 12 as fair and 8 as poor. Based on this clinical and functional evaluation, majority of our cases fall in the "excellent" category - 42 (89.4%), good - 4 (8.6%) and fair - 1 (2%). Cosmetically, the flap was acceptable for 32 individuals, 9 patients reported it as "thick", 3 complained of hairy skin and three patients labeled the skin as insensate. Regarding functions (ADL) and weight bearing status, 44 patients were satisfied, 3 had problems in sports activities and shoe wear, and all had full weight bearing status.

## Discussion

The potential problems of the flap [9] include some amount of venous congestion in reversed island flaps, painful neuroma as a result of lesion of the superficial peroneal nerve, anatomic vascular variations [9,14-20] and the donor site concern specially in young women. The usefulness of lateral supramalleolar flap has been demonstrated by its use as a delay flap [18,24] for tendoachilles coverage in difficult situations like Werner's syndrome, coverage of ischemic ulcer in Buerger's disease [19], as a free flap for oral coverage [14] and limb reconstruction [20].

Certain anatomic variations of the flap include the inconstant but frequent presence of a proximal inferolateral collateral artery [15,16],

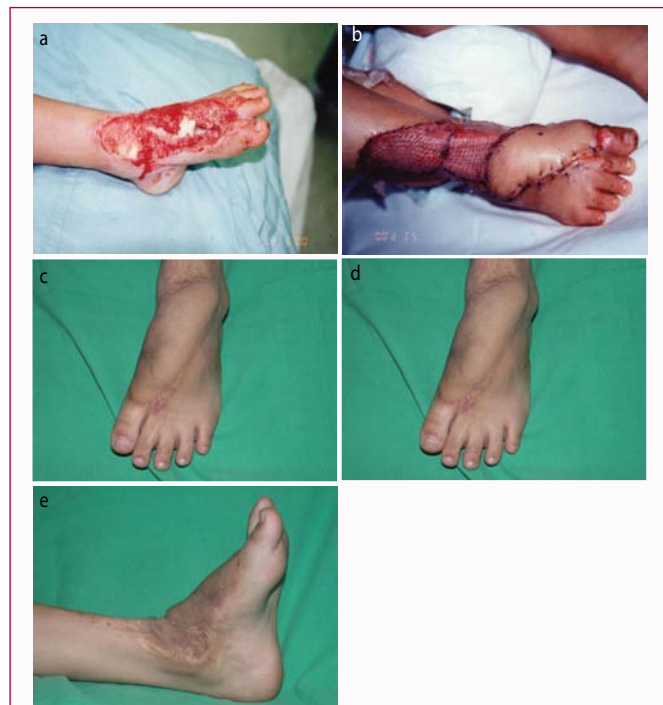

**Table 2:** Correlation between Complications and absence of peroneal perforators.

| COMPLICATION                         | Group I   | Group II  |
|--------------------------------------|---|---|
|                                      | Absence of peroneal perforator and Presence of inferolateral collateral artery/<br>(N=12 cases) | Presence of peroneal perforator/ No inferolateral collateral artery<br>(N=35 cases) |
| Tip necrosis                         | 0   | 4   |
| Infection                            | 0   | 2   |
| Venous congestion                    | 0   | 3   |
| venous congestion + partial necrosis | 0   | 1   |

**Table 3:** Flap Outcome Grade by Dr. Pervaiz Hashmi et al. (Showing functional outcome based on flap Coverage, Cosmetic appearances, Activities of Daily livings and Weight bearing status of limb).

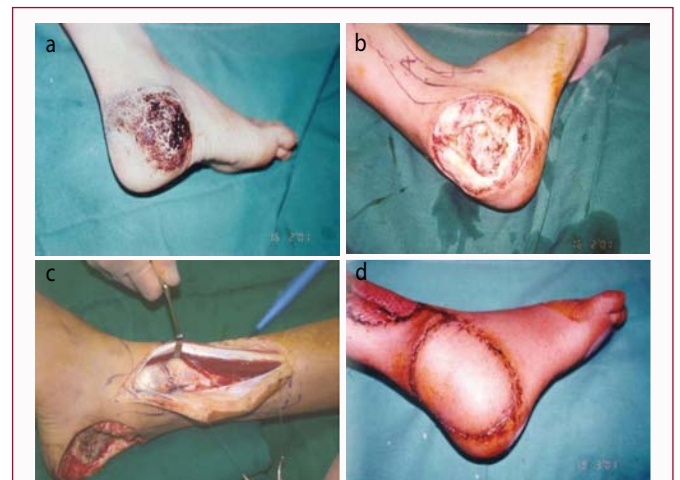| Variable            | Excellent (5)              | Good (4)                                      | Fair (3)                              | Poor (2)                                   |
|---------------------|----------------------------|---|---------------------------------------|--|
| Coverage            | 100%                       | 90% -100%                                     | 80%-90%                               | 50%-70%                                    |
| Cosmetic Appearance | Highly acceptable          | Acceptable with slight raised skin margin     | Acceptable with raised skin margin    | Not acceptable due to thick and hairy skin |
| ADL                 | No issue in ADL and sports | No issue in ADL, difficulty in sports         | Mild issue in ADL, cannot play sports | Difficulty in ADL and sports               |
| Weight bearing      | Full weight bearing        | Full weight bearing, mild discomfort in sport | Discomfort in full weight bearing     | Pain on full weight bearing                |
| Total               | 20                         | 16  | 12                                    | 8  |



**Case 1:** This 4 years girl sustained grade III-B fracture of first metatarsal of left foot as a result of runover injury. The area of degloving extended from dorsum of foot and ankle up to the bases of first and second toes (Figure 1a). To cover this defect, lateral supramalleolar flap was raised as a retrograde pedicle island flap (Figure 1b). Three and a half years postoperatively after de-fattening of the flap for cosmetic reasons (Figure 1c), excellent range of ankle motion was achieved (Figure 1d, 1e).

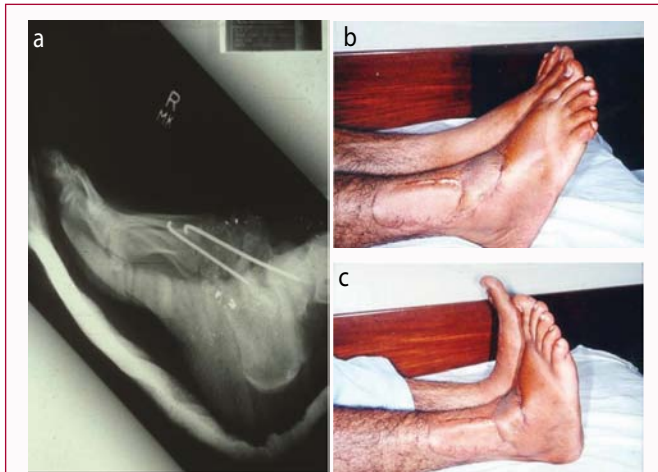
variations in the level of anastomosis between the perforating branch of the peroneal artery and the anterolateral malleolar artery arising from the anterior tibial artery, presence of the anterior peroneal artery, presence of a vascular network instead of a well-defined artery, absence of the perforating branch of the peroneal artery [15,16] and the basis of cutaneous circulation solely on anterior tibial perforators.

We encountered different variations in vascular anatomy as compared to other series. In 12 out of 47 cases the peroneal

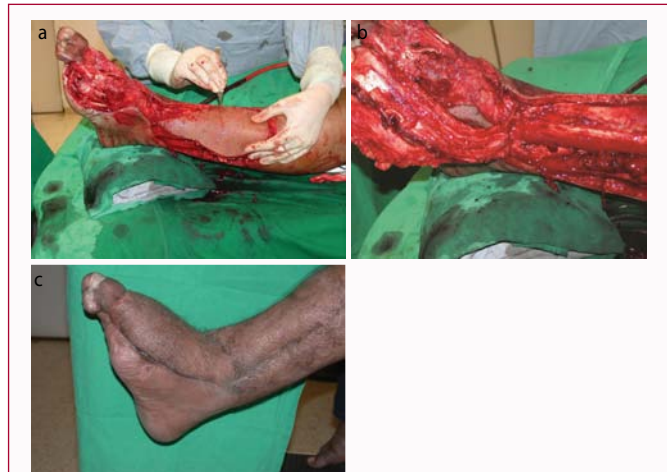

**Case 2:** 12 years male child, presented with a hemangioma on the lateral aspect of right heel for over two years with intermittent bloody discharge (Figure 2a). Excellent functional and cosmetic result was achieved by excision of hemangioma and coverage with lateral supramalleolar flap (Figure 2b, showing defect, 2c showing inferolateral collateral artery as the peroneal artery perforator was absent and 2d showing the final outcome).

artery perforator was absent (Figure B), which is a larger ratio and contradicts the previous data [9,15]. Dubreil Chambradel [8] found the peroneal artery perforator absent in 10 out of 165 cadaveric dissections. Relevant literature [9,11-14,25-29] shows a persistent and constant presence of perforator of peroneal artery but our experience is different. We detected 12 cases out of 47 in which the peroneal artery perforator was replaced with inferolateral collateral artery from the anterior tibial artery. This finding is consistent with the finding of Le Nen et al. [15,16] who suggested that inferior lateral collateral artery is the basis of lateral supramalleolar flap based on cadaveric and clinical studies. We think antegrade flap based on inferolateral collateral artery is much more vascularized, robust and perfused. The chances of its partial or tip necrosis are less, as we have seen in our study. In flaps based on the inferior collateral artery, we noted that artery bifurcated just like perforator of peroneal artery. The ascending branch of this inferolateral collateral artery supplies the anterolateral



**Case 3:** 40 years old gentleman had gunshot injury to right foot with grade III open fracture of tarsometatarsal joints. Following debridement and skeletal stabilization, as shown in X-rays Figure 3a. The defect was covered with Supramalleolar flap with good plantar and dorsiflexion (Figure 3b, 3c).



**Case 4:** 38 years old gentleman sustained injury to his left foot in road traffic accident when tyre of a vehicle ran over his foot. There was with loss of lateral two toes and skin over the dorsum of foot. Following debridement, defect was covered with supra malleolar flap, based in inferior lateral collateral artery (Figure 4a, 4b). Excellent outcome after three years (Figure 4c).

**Table 4:** Scorings based on Table 3.

| Outcomes Scores/Grades | No. of Patients (%) (N=47) |
|------------------------|----------------------------|
| Excellent              | 42 (89.4%)                 |
| Good                   | 4 (8.6%)                   |
| Fair                   | 1 (2%)                     |
| Poor                   | 0                          |
| Mean Score ± S.D       | 18.9 ± 1.7                 |

skin of the leg and descending branch anastomoses with anterolateral malleolar artery (Figure B), forming a continuous channel till the sinus tarsi. This arterial channel forms a basis for the flap.

We noticed that the incidence of complications like venous congestion, flap tip necrosis was zero in the 12 cases where flap was based on antegrade circulation of inferolateral collateral artery from the anterior tibial artery. All complications were noted in those cases where peroneal artery perforator was present and flap was based on the retrograde circulation and ascending branch of peroneal artery perforator.

Eight flaps needed to be left on donor bed after harvesting due to doubtful circulation and later rotated to the recipient site as “DELAY FLAPS” after 48 h without any problems [24]. Awareness of vascular variations is important and use of delay flap in case of doubtful circulation is an excellent option. Even without Duplex imaging, use of magnification was enough to evaluate the vascular anatomy pre-operatively. It was possible to harvest the flap on all occasions despite vascular variations.

The lateral supramalleolar is not the first option for weight bearing heel coverage [9,11-13], but the arc of rotation does allow one to cover the region in problem cases.

The majority of patients we encountered in our series were those with road side accidents and bomb blast wounds, males being the major victims. Most of the fractures were stabilized before flap coverage. Although many cases came to us after more than 12 h of injury, we did not encounter any flap failure as a result of uncontrollable infection. We compared our results with the major case series of supramalleolar flaps done since its inception by Masquelet

[2]. The comparison was done in terms of flap survival, complications, functional and aesthetic outcome. The complication rate is variable in different series. Masquelet and Valenti [9,11] have reported a complication rate of 7.6% each for venous congestion, partial necrosis and hematoma formation, and a flap survival rate of 90%. Touam [25] reported a flap necrosis rate of 11% with a survival rate of 77%. The complication rate of flap necrosis and venous congestion was higher in older series [26,27] ranging from 5% to 20%. Recent series [28,29] show a relatively lesser rate of complications in terms of flap necrosis, venous congestion and infections.

There are few pertinent points to our series worth mentioning. It is the largest case series by a single surgeon with a very long follow up. The second aspect noted was that complications were associated with retrograde circulation (with perforator of peroneal artery) like partial or tip necrosis of flap; may be angiosome territory of ascending branch of peroneal perforator is less/small as compared to ascending branch of inferolateral collateral artery that supplies up to mid leg (ante grade circulation). This aspect is well supported by other authors also [15,16]. The last feature of our case series is that we developed a self-designed tool to assess the clinical and functional outcome of our flaps and patients. Four parameters were included cosmetic appearance, coverage of defect, weight bearing status of foot and ADL. Each variable was given four grade and four numbers correspondingly. The assessment was done by two independent researchers (doctors) who evaluated the patients in clinics and the final analysis of data was performed by an independent third party. The self-designed assessment tool and scoring system needs validation by other researchers. This was an effort to determine the outcome of flaps objectively.

This flap can be raised as peninsular when a skin paddle is kept intact with flap at the pivot point of rotation. Most of the flaps are raised retrograde when peroneal perforator is intact; the pedicle length can be increased along with its anastomosis with anterolateral malleolar artery and raised up to sinus tarsi. We used this flap safely for the defects around the heel, tendoachilles, perimalleolar area, ankle joint, and dorsum of foot up to toes and plantar aspect of foot except weight bearing area of heel. This is an excellent flap for coverage of above-mentioned defects provided the surgeon is familiar

**Table 5:** Comparisons of 7 studies of Lateral Supramalleolar Flap.

| Author's Name        | Duration of study | Number of Patients | Complication                         | Survival Rate/ flap coverage |
|----------------------|-------------------|--------------------|--------------------------------------|------------------------------|
| Valenti P, Masquelet | 1987-1989         | 13                 | 1 distal necrosis (7.6%)             | 90%                          |
|                      |                   |                    | 1 hematoma (7.6%)                    |                              |
|                      |                   |                    | 1 venous congestion (7.6%)           |                              |
| C. Touam             | 1988-1997         | 27                 | 3 Complete necrosis (11%)            | 77%                          |
|                      |                   |                    | 2 Partial necrosis (7%)              |                              |
|                      |                   |                    | 1 venous congestion (3%)             |                              |
| Philippe Voche       | 1991-2002         | 41                 | 8 venous congestion (19.5%)          | 95%                          |
|                      |                   |                    | 3 partial necrosis (7%)              |                              |
| Demiri E             | 2000-2005         | 20                 | 1 necrosis (5%)                      | 95%                          |
|                      |                   |                    | 4 partial necrosis (20%)             |                              |
|                      |                   |                    | 1 venous congestion (5%)             |                              |
| Mahesh S. G          | 2016-2018         | 20                 | 1 flap edema (5%)                    | 95%                          |
|                      |                   |                    | 1 partial Graft loss (5%)            |                              |
|                      |                   |                    | 3 Infection (15%)                    |                              |
| G. I. Nambi          | 2017-2019         | 20                 | 3 necrosis (15%)                     | 85%                          |
|                      |                   |                    | 1 epidermolysis at flap margins (5%) |                              |
| Vivek                | 2017-2019         | 20                 | 2 venous congestion (10%)            | 80%                          |
|                      |                   |                    | 2 partial necrosis (10%)             |                              |
| Pervaiz Hashmi       | 1999-2020         | 47                 | 4 Tip necrosis (8.5%)                | 98%                          |
|                      |                   |                    | 2 Infections (4%)                    |                              |
|                      |                   |                    | 4 Venous congestions (8.5%)          |                              |

with anatomy, vascular variations and microsurgical techniques. This procedure has to be done with patience as the dissection is tedious, just like posterior interosseous artery flap in upper extremity.

The understanding of fasciocutaneous flaps [20] and cutaneous vascular territories of the leg [21] has greatly aided in the development of flap surgery. Newer techniques and modifications of lateral supramalleolar flap as adipofascial flaps continue to emerge with good clinical success for small and medium size defects [22]. The study substantiates that the lateral supramalleolar fasciocutaneous flap is a reliable choice of flap for medium to large size wounds in the region of perimalleolar area, dorsum of foot and foot and ankle. As there can be vascular variations [9,14-17], therefore, color duplex imaging for preoperative localization of perforators and magnification for dissection around the vessel will greatly facilitate the outcome, especially for relatively less experienced microvascular surgeons. The usefulness of lateral supramalleolar flap for coverage of soft tissue defects around the foot and ankle is undoubted.

### Meetings at Which the Work Was Presented in Part

15<sup>th</sup> International Congress of Pakistan Orthopedic Association, January 12 to 14, 2001, Lahore, Pakistan.

OASAC, SICOT, ASAMI, XVI ORTHOCON, April 5 to 8, 2002, Karachi, Pakistan.

Annual Conference of Pakistan Association of Plastic Surgeons, March 2002, Karachi.

XVI Scientific Congress BOSCON 2003 held on March 1 to 3, 2003, under Bangladesh Orthopedic Society, Bangladesh.

### References

- Shen ZL, Jia WX, Hou MZ, Huang XQ, Cai YX, Wang L, et al. Application

of flaps for coverage of foot wounds with tendon and bone exposure based on a subunit principle. In *Innovations in Plastic and Aesthetic Surgery*. Springer, Berlin, Heidelberg; 2008. p. 119-26.

- Heitmann C, Levin LS. The orthoplastic approach for management of the severely traumatized foot and ankle. *J Trauma Acute Care Surg*. 2003;54(2):379-90.
- Baumer EP, Lauritsen JL. Reporting crime to the police, 1973–2005: A multivariate analysis of long-term trends in the National Crime Survey (NCS) and National Crime Victimization Survey (NCVS). *Criminology*. 2010;48(1):131-85.
- Taylor GI, Townsend P, Corlett R. Superiority of the deep circumflex iliac vessels as the supply for free groin flaps. *Clinical work. Plast Reconstr Surg*. 1979;64(6):745-59.
- Deng C, Wei Z, Wang B, Jin W, Zhang W, Tang X, et al. The proximally based lateral superficial sural artery flap: A convenient and optimal technique for the reconstruction of soft-tissue defects around the knee. *Int J Clin Exp Med*. 2016;9(8):15167-76.
- Shim JS, Kim HH. A novel reconstruction technique for the knee and upper one third of lower leg. *J Plast Reconstr Aesthet Surg*. 2006;59(9):919-26.
- Soltanian H, Garcia RM, Hollenbeck ST. Current concepts in lower extremity reconstruction. *Plast Reconstr Surg*. 2015;136(6):815e-829e.
- Yoshimura M, Shimada T, Imura S, Shimamura K, Yamauchi S. Peroneal island flap for skin defects in the lower extremity. *J Bone Joint Surg Am*. 1985;67(6):935-41.
- Masquelet AC, Beveridge J, Romana C, Gerber C. The lateral supramalleolar flap. *Plast Reconstr Surg*. 1988;81(1):74-81.
- Menesi L. [The lateral supramalleolar fasciocutaneous flap and its modification]. *Magy Traumatol Ortop Kezseb Plasztikai Seb*. 1994;37(4):371-4.
- Valenti P, Masquelet AC, Romana C, Nordin JY. Technical refinement of

- the lateral supramalleolar flap. *Br J Plast Surg.* 1991;44(6):459-62.
12. Leung PC, Hung LK, Leung KS. Use of the medial plantar flap in soft tissue replacement around the heel region. *Foot Ankle.* 1988;8(6):327-30.
  13. Nohira K, Shintomi Y, Sugihara T, Ohura T. Replacing losses in kind: improved sensation following heel reconstruction using the free instep flap. *J Reconstr Microsurg.* 1989;5(1):1-6.
  14. Wolff KD. The supramalleolar flap based on septocutaneous perforators from the peroneal vessels for intraoral soft tissue replacement. *Br J Plast Surg.* 1993;46:151-5.
  15. Le Nen D, Beal D, Person H, Lefevre C, Senecail B. Anatomical basis of a fascio-cutaneous pedicle flap based on the infero-lateral collateral artery of the leg. *Surg Radiol Anat.* 1994;16:3-8.
  16. Le Nen D, Stindel E, Caro P, Dubrana F, Lefèvre C. [Therapeutic possibilities of the lateral supra-malleolar flap and its variations. Apropos of 6 clinical cases]. *Ann Chir Plast Esthet.* 1996;41(2):127-35.
  17. Beveridge J, Masquelet AC, Romana MC, Vinh TS. Anatomic basis of a fascio-cutaneous flap supplied by the perforating branch of the peroneal artery. *Surg Radiol Anat.* 1988;10:195-9.
  18. Saitoh S, Hata Y, Murakami N, Seki H, Kobayashi H, Shimizu T, et al. The 'superficial' peroneal artery: A variation in cutaneous branching from the peroneal artery, nourishing the distal third of the leg. *Br J Plast Surg.* 2001;54:428-33.
  19. Okazaki M, Ueda K, Kuriki K. Lateral supramalleolar flap for heel coverage in a patient with Werner's syndrome. *Ann Plast Surg.* 1998;41: 307-10.
  20. Chang H, Hasegawa T, Moteki K, Ishitobi K. A challenging treatment for an ischaemic ulcer in a patient with Buerger's disease: Vascular reconstruction and local flap coverage. *Br J Plast Surg.* 2001;54:76-9.
  21. Cormack GC, Lamberty BG. A classification of fascio-cutaneous flaps according to their patterns of vascularisation. *Br J Plast Surg* 1984; 37: 80-7.
  22. Whetzel TP, Barnard MA, Stokes RB. Arterial fasciocutaneous vascular territories of the lower leg. *Plast Reconstr Surg.* 1997;100:1172-83;discussion 84-5.
  23. Lee S, Estela CM, Burd A. The lateral distally based adipofascial flap of the lower limb. *Br J Plast Surg.* 2001;54:303-9.
  24. Ahmed K, Hashmi P. Delayed lateral supramalleolar flap; an innovative technique for enhanced viability. *J Ayub Med Coll Abbottabad.* 2005;17(3)1-4.
  25. Touam C, Rostoucher P, Bhatia A, Oberlin C. Comparative study of two series of distally based fasciocutaneous flaps for coverage of the lower one-fourth of the leg, the ankle, and the foot. *Plast Reconstr Surg.* 2001;107(2):383-92.
  26. Voche P, Merle M, Stussi JD. The lateral supramalleolar flap: experience with 41 flaps. *Ann Plast Surg.* 2005;54(1):49-54.
  27. Demiri E, Foroglou P, Dionyssiou D, Antoniou A, Kakas P, Pavlidis L, et al. Our experience with the lateral supramalleolar island flap for reconstruction of the distal leg and foot: A review of 20 cases. *Scandinavian J Plast Reconstr Surg Hand Surg.* 2006;40(2):106-10.
  28. Mahesh SG, Ramji AN, Balaji R, SM MC. Reconstructive strategies for lower one-third leg soft tissue defects. *Int Surg J.* 2018;5(12):4016-21.
  29. Nambi GI, Varanambigai TA. Clinical study of the lateral supramalleolar flap in the soft tissue reconstruction around the ankle region. *Indian J Plast Surg.* 2020;53(1):83.
  30. Vivek R, Jhansi S, Janardhanan J. lateral supramalleolar flap for reconstruction of the defects of distal leg. *Indian J Appl Res.* 2020;9(12).