



Lateral Meniscus Posterior Root Tear with Pigmented Villonodular Synovitis

Yue Shen*, Haruna Nakajima, Xuesong Dai and Shigui Yan

Department of Orthopedic Surgery, Second Affiliated Hospital, School of Medicine, Zhejiang University, China

Keywords

Meniscus tear; Arthroscopy; Pigmented villonodular synovitis

Clinic Image

A 43-year-old male was referred to our hospital for orthopedics outpatient clinic with the complain of right knee pain accompanied by snapping sensation. He described the pain as constant and nonradiative. The patient had a history of knee trauma, while his systemic review was unremarkable. The pain can be aggravated by physical activity, for example, long standing or walking. Physical examination of the right knee showed slight joint effusion and tenderness along the joint line. No positive sign of knee instability was found by performing the anterior and posterior drawer tests, the Lachman test. Magnetic Resonance Imaging (MRI) of the left knee reveals “right lateral meniscus posterior root tear” (Figure 1A). This patient accepted our surgical medical suggestion of arthroscopy surgery. During his arthroscopy operation, careful examination of the whole knee was preceded. Intraoperatively, a bright brown inflamed synovium was seen and dark brown bloody fluid drained from the joint (Figure 1B). The synovial lesion was resected and treated with shaver in order to achieve a macroscopic complete removal of PVNS. Radio frequency abrasion was used to stop bleeding of synovial bed and to reduce the chances of recurrence. A decision was made to obtain synovial biopsy from the right femoral notch, which confirmed the diagnosis of PVNS. Macroscopically, no residual lesion or affected synovium tissue was left. The posterior horn of the lateral meniscus had a complex tear and displacement consistent with a bucket handle tear. Then meniscus repair procedure is preceded. Histological examination of the excision piece described characteristics compatible with PVNS, with areas of extensive necrosis and the presence of hemosiderin deposits (Figure 1C). Because of incomplete synovial excision and histological confirmation of PVNS diagnosis, the patient was referred to the Radiation Oncology Department. The patient refused further follow-up and radiation therapy because of the absence of symptoms and because of economic issues. At his 2-month follow-up, clinical and radiological examinations were unremarkable. On examination, he walked without assistance and showed a full range of motion without the signs of knee effusion.

OPEN ACCESS

*Correspondence:

Yue Shen, Department of Orthopedic Surgery, Second Affiliated Hospital, School of Medicine, Zhejiang University, Hangzhou 310009, Zhejiang, China, Tel: +86180-5873-0540;

E-mail: shenyue@zju.edu.cn

Received Date: 28 Oct 2019

Accepted Date: 18 Nov 2019

Published Date: 25 Nov 2019

Citation:

Shen Y, Nakajima H, Dai X, Yan S. Lateral Meniscus Posterior Root Tear with Pigmented Villonodular Synovitis. *Clin Surg*. 2019; 4: 2667.

Copyright © 2019 Yue Shen. This is an open access article distributed under the Creative Commons Attribution License, which permits unrestricted use, distribution, and reproduction in any medium, provided the original work is properly cited.

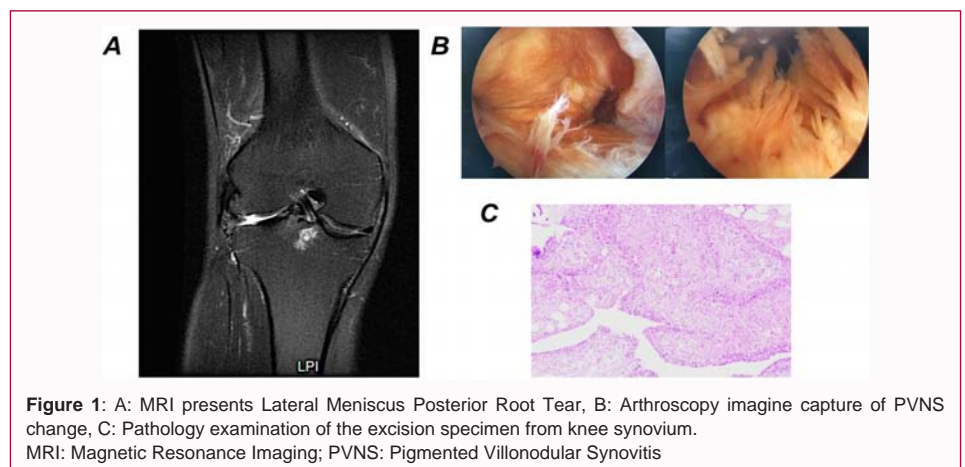


Figure 1: A: MRI presents Lateral Meniscus Posterior Root Tear, B: Arthroscopy image capture of PVNS change, C: Pathology examination of the excision specimen from knee synovium. MRI: Magnetic Resonance Imaging; PVNS: Pigmented Villonodular Synovitis