



## Ischiofemoral Impingement Syndrome

Jingen Hu and Caibao Hu\*

Department of Intensive Care Medicine, Zhejiang Hospital, Hangzhou, China

### Clinical Image

A 26-year-old female presents to the Orthopedic Outpatient Clinic due to a right hip pain, radiating to the lower extremity for 3 months.

She also noted as an audible, painful clunking and a grinding sensation in her hip during hip flexion. She has no history of injury or surgery. Physical examination revealed full range of motion in right hip joints; right hip joint produced an audible click as the hip moves from flexion to extension. She can kneel down with knees close together. MRI revealed quadratus femoris muscle edema with concurrent narrowing of the ischiofemoral space (Figure 1). Ischiofemoral impingement syndrome was diagnosed on that basis. After four weeks of the non steroidal anti-inflammatory drugs and physical therapy, pain of the right hip was decreased and the hip snapping sensation was resolved. At the 8-month clinical follow-up, the patient has no complaining of right hip pain.

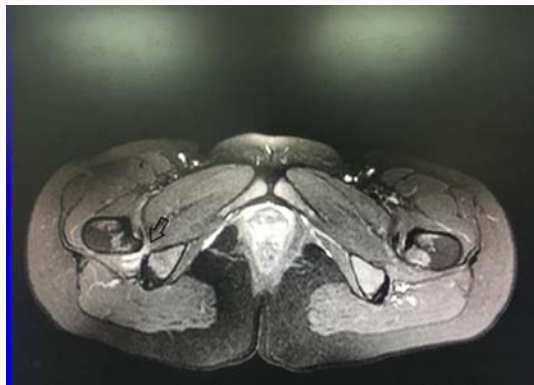


Figure 1: Quadratus femoris muscle edema with concurrent narrowing of the ischiofemoral space.

### OPEN ACCESS

#### \*Correspondence:

Caibao Hu, Department of Intensive Care Medicine, Zhejiang Hospital, Hangzhou, Zhejiang 310000, China, E-mail: zjicu1996@163.com

Received Date: 11 Mar 2019

Accepted Date: 12 Apr 2019

Published Date: 18 Apr 2019

#### Citation:

Hu J, Hu C. Ischiofemoral Impingement Syndrome. *Clin Surg.* 2019; 4: 2401.

**Copyright** © 2019 Caibao Hu. This is an open access article distributed under the Creative Commons Attribution License, which permits unrestricted use, distribution, and reproduction in any medium, provided the original work is properly cited.